



This is a digital copy of a book that was preserved for generations on library shelves before it was carefully scanned by Google as part of a project to make the world's books discoverable online.

It has survived long enough for the copyright to expire and the book to enter the public domain. A public domain book is one that was never subject to copyright or whose legal copyright term has expired. Whether a book is in the public domain may vary country to country. Public domain books are our gateways to the past, representing a wealth of history, culture and knowledge that's often difficult to discover.

Marks, notations and other marginalia present in the original volume will appear in this file - a reminder of this book's long journey from the publisher to a library and finally to you.

### **Usage guidelines**


Google is proud to partner with libraries to digitize public domain materials and make them widely accessible. Public domain books belong to the public and we are merely their custodians. Nevertheless, this work is expensive, so in order to keep providing this resource, we have taken steps to prevent abuse by commercial parties, including placing technical restrictions on automated querying.

We also ask that you:

- + *Make non-commercial use of the files* We designed Google Book Search for use by individuals, and we request that you use these files for personal, non-commercial purposes.
- + *Refrain from automated querying* Do not send automated queries of any sort to Google's system: If you are conducting research on machine translation, optical character recognition or other areas where access to a large amount of text is helpful, please contact us. We encourage the use of public domain materials for these purposes and may be able to help.
- + *Maintain attribution* The Google "watermark" you see on each file is essential for informing people about this project and helping them find additional materials through Google Book Search. Please do not remove it.
- + *Keep it legal* Whatever your use, remember that you are responsible for ensuring that what you are doing is legal. Do not assume that just because we believe a book is in the public domain for users in the United States, that the work is also in the public domain for users in other countries. Whether a book is still in copyright varies from country to country, and we can't offer guidance on whether any specific use of any specific book is allowed. Please do not assume that a book's appearance in Google Book Search means it can be used in any manner anywhere in the world. Copyright infringement liability can be quite severe.

### **About Google Book Search**

Google's mission is to organize the world's information and to make it universally accessible and useful. Google Book Search helps readers discover the world's books while helping authors and publishers reach new audiences. You can search through the full text of this book on the web at <http://books.google.com/>







4519

A MANUAL  
OF  
*Assoc. Med. Ass.*  
DISEASES OF THE EAR

FOR THE USE OF

Students and Practitioners of Medicine

BY

ALBERT H. BUCK, M.D.,

Clinical Professor of the Diseases of the Ear, in the College of Physicians  
and Surgeons, New York; Consulting Aural Surgeon,  
New York Eye and Ear Infirmary

NEW YORK  
WILLIAM WOOD & COMPANY  
56 & 58 LAFAYETTE PLACE  
1889



.







## CONTENTS.

---

### CHAPTER I.

	PAGE
<b>GENERAL DIAGNOSIS</b> . . . . .	1
Method of procedure . . . . .	1
Tests of the hearing power . . . . .	3
The use of the tuning fork . . . . .	6
Ear specula and reflectors . . . . .	8
Introduction of the speculum and use of the reflector . . . . .	13
Anatomical considerations . . . . .	13
Sources of light . . . . .	14
Position of the patient in relation to the light . . . . .	15
The actual examination . . . . .	15
Accessory instruments used in the examination of the ear . . . . .	17

### CHAPTER II.

<b>GENERAL PATHOLOGY</b> . . . . .	26
Anatomical relations of the internal, the middle, and the outer ear . . . . .	26
The locality first affected by the inflammation . . . . .	28
The extent to which the inflammation may involve the outer, middle or internal ear . . . . .	28
The extent to which an inflammation of one of the three cavities may involve the other two, and perhaps also neighboring parts . . . . .	28
The characteristic differences between inflammations of the ear . . . . .	31
The alterations produced in the tissues and in the secretions . . . . .	34

### CHAPTER III.

<b>DISEASES OF THE AURICLE</b> . . . . .	36
Eczema . . . . .	36
Simple diffuse inflammation . . . . .	39

	PAGE
Hæmatoma auris; perichondritis; othæmatoma; chondromalacia; chondromalacosis . . . . .	40
New-growths . . . . .	51
Miscellaneous affections . . . . .	53
Lupus . . . . .	53
Syphilitic gummata and ulcerations . . . . .	53
Cirsoid aneurism . . . . .	54
Cleft lobule . . . . .	54
Wounds and contusions . . . . .	55
Burns . . . . .	55
Frost-bite . . . . .	56
Herpes zoster . . . . .	56
Congenital malformations . . . . .	57
Fistula auris congenita . . . . .	58
CHAPTER IV.	
DISEASES OF THE EXTERNAL AUDITORY CANAL . . . . .	59
Impacted cerumen . . . . .	59
Circumscribed inflammation . . . . .	66
Diffuse inflammation (otitis externa diffusa, periostitis, eczema, desquamative inflammation, otomycosis) . . . . .	69
Ulcers, polypoid growths, and caries . . . . .	87
False membranes . . . . .	94
Syphilitic ulcers and condylomata . . . . .	100
Foreign bodies . . . . .	104
Wounds . . . . .	111
New-growths . . . . .	112
Osteoma . . . . .	112
Cancer . . . . .	116
Sarcoma . . . . .	118
Cysts . . . . .	121
CHAPTER V.	
METHODS OF EXAMINING THE MIDDLE EAR . . . . .	123
Direct inspection . . . . .	123
Valsalva's method . . . . .	124
Politzer's method . . . . .	125
Catheterization of the Eustachian tube . . . . .	131
CHAPTER VI.	
DISEASES OF THE MIDDLE EAR . . . . .	139
Classification . . . . .	139
Eustachian catarrh . . . . .	140



CONTENTS.

vii

	PAGE
Other pathological conditions of the Eustachian tube . . .	141
Acute and subacute inflammation of the middle ear . . .	150

CHAPTER VII.

<b>ACUTE AND SUBACUTE CATARRHAL INFLAMMATION OF THE MIDDLE EAR . . . . .</b>	<b>152</b>
Pathology . . . . .	152
Acute catarrhal inflammation . . . . .	155
Subacute inflammation . . . . .	156
Mucous or serous exudation into the middle ear (hydro-tympanum ; otitis media serosa sive mucosa). . . . .	158
Hæmorrhagic exudation into the middle ear . . . . .	163
Adenoid vegetations of the naso-pharyngeal vault . . . . .	171
Treatment of special stages or conditions of the disease . . . . .	184

CHAPTER VIII.

<b>CHRONIC CATARRHAL INFLAMMATION OF THE MIDDLE EAR . . . . .</b>	<b>194</b>
Hypertrophic inflammation . . . . .	194
Sclerosis of the tympanic mucous membrane . . . . .	195

CHAPTER IX.

<b>ACUTE PURULENT INFLAMMATION OF THE MIDDLE EAR . . . . .</b>	<b>204</b>
Pathology . . . . .	205
Symptomatology . . . . .	206
Sequelæ and complications . . . . .	217
Diagnosis . . . . .	218
Prognosis . . . . .	220
Treatment . . . . .	222
Therapeutic measures which tend to arrest or diminish the direct force of an acute inflammation of the middle ear . . . . .	222
Therapeutic measures which tend to prevent the indirect effects of an acute inflammation of the middle ear . . . . .	227
Therapeutic measures which possess the power of arresting the discharge which follows the acute stage of a purulent inflammation of the middle ear . . . . .	229
Acute inflammation of the posterior fold of the drum membrane . . . . .	239

CHAPTER X.

<b>CHRONIC PURULENT INFLAMMATION OF THE MIDDLE EAR . . . . .</b>	<b>242</b>
The course of the disease . . . . .	242
General remarks on diagnosis and prognosis . . . . .	243

	PAGE
Different types of chronic purulent inflammation of the middle ear . . . . .	249
Simple uncomplicated cases . . . . .	249
Proliferative cases . . . . .	255
Cases in which the bone is involved . . . . .	270
Desquamative processes . . . . .	276
Extension of the ulcerative process to neighboring organs . . . . .	280
Cyst-like tumors of the drum membrane . . . . .	280
Deformities caused by both the acute and the chronic forms of purulent inflammation of the middle ear . . . . .	282
Artificial drum membranes . . . . .	290
 CHAPTER XI. 	
FRACTURES OF THE TEMPORAL BONE . . . . .	291
 CHAPTER XII. 	
DISEASES OF THE MASTOID PROCESS . . . . .	298
Anatomical relations . . . . .	298
Subacute condensing mastoid osteitis . . . . .	307
Acute diffuse mastoid osteitis . . . . .	313
Chronic ulcerative inflammation of the mastoid antrum . . . . .	322
Significance of certain phenomena occasionally met with in diseases of the mastoid process . . . . .	326
Treatment . . . . .	327
The indications for resorting to perforation of the mastoid process . . . . .	330
Steps of the operation . . . . .	335
 CHAPTER XIII. 	
MISCELLANEOUS CONDITIONS OF THE DRUM MEMBRANE, OSSICLES, AND TYMPANIC CAVITY . . . . .	341
Atrophy of the membrana tympani . . . . .	341
Horny growth of the membrana tympani . . . . .	342
Vascular growth of the membrana tympani . . . . .	343
Deformed drum membrane . . . . .	344
Absence of the Hammer . . . . .	344
Hook-shaped manubrium mallei . . . . .	344
Ruptures of the drum membrane . . . . .	345
New-growths in the middle ear . . . . .	346
Hyperostosis . . . . .	346
Vascular growths . . . . .	347
Malignant tumor . . . . .	353
Subjective and objective systolic murmurs . . . . .	357

CONTENTS.

ix

	PAGE
Otalgia . . . . .	358
Affections of the chorda tympani nerve . . . . .	359

CHAPTER XIV.

SYPHILITIC AND TUBERCULAR DISEASE OF THE DEEPER PARTS OF THE EAR . . . . .		360
Syphilis . . . . .		360
Tuberculosis . . . . .		366
Painless ulcerative inflammation of the membrana tympani . . . . .		367
Cheesy inflammation of the middle ear . . . . .		368

CHAPTER XV.


DIFFERENT FORMS OF AURAL DISEASE IN WHICH THE LABY- RINTH IS BELIEVED TO BE INVOLVED . . . . .		371
Ménière's disease . . . . .		377
Anomalies of hearing . . . . .		382
Diplacusis monauricularis . . . . .		383
Diplacusis binauricularis . . . . .		383
Hyperæsthesia acustica . . . . .		385

THE APPENDIX.

ANATOMICAL AND PHYSIOLOGICAL SKETCH OF THE EAR . . . . .	389
GENERAL INDEX . . . . .	418







# A MANUAL OF DISEASES OF THE EAR.

---

## CHAPTER I.

### GENERAL DIAGNOSIS.

IN investigating cases in which complaint is made of the ear, we can derive aid, in ascertaining the true nature of the disturbance, from three different sources, viz., from the patient's own account (or that of some member of the family); from various outward manifestations discoverable by simple inspection and palpation; and, finally, from an examination of the more or less hidden approaches to the deeper cavities of the ear. In almost all cases the information derived from any one of these sources needs to be confirmed by the evidence obtained from the other two before we can safely adopt a positive diagnosis. Thus, for example, in examinations with the speculum and reflected light, the picture presented to the eye of the examiner often possesses no absolute diagnostic value; that is, it may represent the legitimate accompaniment of either of two or three different pathological processes. The true interpretation of the picture is obtained only after we have learned the history of the case, have inspected the accessible parts in the immediate neighborhood, and have tested the hearing and perhaps also the body-temperature. To save time, and also to make sure of not forgetting some important step in the examination, the beginner will find it useful in practice to adopt a routine plan of procedure in every case. First get the history of the trouble, whatever it may be, from the patient. Then test the hearing of both ears (watch and voice tests) and make a note of the results. Apply the vibrating tuning-fork to the patient's forehead and note any predominance of the sound (as observed by the patient) in one or the other ear. Next observe the appearance of the auricle and of the mastoid integuments. Pass the finger firmly over the regions in front of and behind the ear, and observe whether the glands on the side

of the neck, below the ear, are enlarged or tender. In cases characterized by severe pain, especially if of several days' duration, search for spots of tenderness in other parts of the head—generally in the vicinity of the occipital protuberance, and sometimes near the vertex. Then proceed to inspect, by aid of speculum and reflected light, the condition of the external auditory canal and drum membrane. Finally, do not omit to examine the faucial mucous membrane, and to question the patient in regard to any symptoms that he may have noticed in the region of the nose and pharynx.

Such a routine plan of examining a case of ear disease will place us in possession of the most prominent facts; but nevertheless, in many instances it will be found necessary to supplement them with still others. I will give a single instance of this, by way of illustration. The case, we will suppose, is one in which the external meatus is found to be closed by a swollen condition of its soft parts, and this, in connection with the swollen and tender condition of the mastoid integuments, suggests the question: Are all these manifestations due simply to an inflammation that has originated primarily in the outer canal of the ear, or are they due to an inflammation of the tympanic cavity which has spread to such an extent, and has reached such a degree of violence, that the outward parts have become secondarily involved? The swollen condition of the meatus debars us from examining the drum membrane, and hence, to solve this problem correctly, we are obliged to cross-question the patient carefully in regard to the order in which the different symptoms—tinnitus, impairment of hearing, tenderness of outer parts, and perhaps others still—have followed each other. The development of tinnitus and deafness only after the ear has been painful and tender for one or more days will furnish *prima facie* evidence of an acute inflammation of the soft parts of the external auditory canal, while the existence of impaired hearing, tinnitus, and perhaps also deep-seated throbbing for a period of several hours or days before the development of tenderness on pressure, indicates that the inflammation must have begun in the middle ear. A history of antecedent "cold in the head" would almost render the diagnosis positive.

This sort of problem, which relates only to the starting-point and extent of the disease, is generally not so very difficult to solve, but there are others which will often baffle us completely. I refer to that large class of cases in which progressive and serious impairment of the hearing is associated with visible lesions of comparative insignificance. As will be seen farther on, when we come to discuss this part of our subject in detail, it will not do to simply establish the fact that the main underlying cause of the disease is a catarrhal process involving the vault of the pharynx

and the cavities of the ear : we must go farther in our investigations, and ascertain what are the various factors at work in perpetuating the catarrhal process. This inquiry will carry the surgeon out of the narrow limits of aural into the broad domain of general pathology ; for it not infrequently happens that a disturbance of the digestive processes, a malposition of the uterus, or that ill-defined general condition termed " lithæmia," is the important factor concerned in perpetuating the catarrhal activity.

We may now proceed to consider more in detail the subjects which have simply been touched upon in the preceding introductory remarks.

#### TESTS OF THE HEARING POWER.

In the case of an adult, considerable dependence may be placed upon the individual's own statement in regard to the character and degree of the impairment of the hearing ; but in the case of a child the information desired must be obtained from the parents or the guardian. Nothing is more common, however, than to hear patients—intelligent adults—say very positively that only one of their ears is affected, whereas on examination it is ascertained that the ear which is supposed to be sound is in reality but little less impaired than the other. Other persons sometimes maintain stoutly that the hearing of one ear is entirely gone, when in reality the organ possesses a very useful degree of hearing power. In no case, therefore, is it safe to accept unreservedly the patient's statements in regard to the degree of impairment of his hearing.

The ticking of a watch, and words or sentences spoken either in a whisper or in an ordinary tone of voice, constitute the only tests which have ever been employed to any great extent. The watch will be found useful, in most cases, in ascertaining the rate of improvement of the hearing while the patient is under treatment. However, the results obtained from the employment of this test are not always trustworthy ; that is, an improvement in the patient's power to hear the ticking of a watch does not always indicate that a corresponding improvement has taken place in his power to hear speech. On the other hand, a patient will often improve very decidedly in his power to hear speech, and yet not be able to hear the ticking of the watch a single inch farther than he did when the test was first tried. It would seem, therefore, as if speech ought always to be employed as the more satisfactory of the two tests. Theoretically, this is indeed true, but in practice, and especially in the small offices, which most of us occupy, the speech test is found to be very unsatisfactory. In this state of things the physician is often compelled to depend almost

entirely on the patient's own observations in regard to any improvement that may take place in the state of his hearing power.

In testing the hearing with the watch, it is better to hold it first at a point which lies beyond the hearing distance of the ear which is being tested, and then to gradually bring it nearer and nearer to the ear, until the patient is able to distinguish the sound of the ticking. As a rule, it is not necessary to ask the patient to close the other ear during the progress of the test, as the ticking of an ordinary watch is a sound of too great feebleness to reach the opposite ear. The proximity of a wall, door, or other reflecting surface, may, however, render such a precaution necessary. If the hearing is markedly affected, the ticking of the watch may not be heard even when it is pressed firmly against the auricle. In this connection it should be remarked that a patient who fails to distinguish the sound of the ticking when the watch is pressed against the auricle will often hear the sound quite distinctly when the watch is pressed against the temple or against the mastoid process. In young children the watch test is not generally to be trusted. For office purposes a loud-ticking watch should always be used, one that in a quiet room may be heard normally at a distance of from seven to ten feet. Watches which tick so delicately that they can only be heard at a distance of three or four feet, are not of much practical use to the aural surgeon. Prof. Adam Politzer, of Vienna, in the hope of furnishing a source of sound of uniform character and intensity, devised a small instrument which he calls an "acoumeter." The click of this instrument may be heard, in a quiet room, at a distance of thirty feet. In certain cases, therefore, testing by the acoumeter would undoubtedly reveal a change in the hearing power when the employment of the watch would probably fail to show any change whatever. The superiority of this instrument over a loud-ticking watch has not proved to be so great as it was at first anticipated, and accordingly it has failed to find general acceptance, at least on this side of the Atlantic.

So long as we continue to use the watch as a means of testing the hearing, the fractional method of recording the hearing distance is undoubtedly the best. This method, which was first suggested by Dr. Prout, of Brooklyn, N. Y., requires that the numerator of the fraction should represent the distance at which the watch is heard by the person whose hearing is being tested, while the denominator indicates the average distance at which a reasonable number of persons with good hearing can distinguish the ticking of the same watch. It is only when we have occasion to report a case that it is desirable to designate the hearing distances in fractional terms. In our own private records the actual distances are alone sufficient, as the tests are always made with the same watch.

The employment of spoken or whispered words as a means of testing the hearing is also involved in many difficulties. I have already mentioned the chief obstacle which in many cases practically precludes the employment of speech as a test, *viz.*: the smallness of the physician's office. But there are other difficulties which are scarcely less serious. I refer to the facts that certain words are much more readily distinguished by the ear than others; that it is not always possible to exclude outside noises; and that the speaker cannot uniformly employ the same pitch, loudness and distinctness of voice. Hence this test is at best a very crude one. Indeed, it is not a possible thing, to-day, to express degrees of hearing power with anything approaching to the accuracy with which the degree of acuteness of vision may be expressed.

In testing the hearing with spoken or whispered words, certain precautions will be found necessary. Thus, for example, if we wish to test the hearing of one ear by means of spoken words, it is absolutely necessary that the other ear should be closed quite firmly. The patient should also sit in such a position that the physician's voice may be thrown directly against the ear which remains open, *i. e.*, at right angles to that side of the head. If we desire to test the hearing power of both ears, the patient should sit facing us, but with both his eyes closed. Deaf people sometimes possess the power of "reading the lips" to such a remarkable degree that the test can hardly be considered a fair one unless the patient has kept his eyes closed. It is also not sufficient for the patient to answer that he has understood what was said to him; he should be required to repeat the exact words spoken by the physician. The difficulty in regard to the determination of the hearing distance may be roughly solved in the following manner:—Repeat, in an ordinary tone of voice, certain numbers (of two or three figures) at a distance of say twenty feet. The patient, we will assume, hears only a part of them correctly. Try the experiment again at a nearer point, say at twelve feet. If he hears all the words correctly, twelve feet may be taken as the hearing distance for that particular day or moment. If the room is so small that we cannot ascertain the maximum distance at which the patient can hear words spoken in an ordinary tone of voice, we must speak in a whisper in repeating the test words. At each distance selected, at least three sets of complex numbers should be repeated, as otherwise the test can scarcely be considered a fair one. The results of these tests are recorded, and at some later date the experiment is to be repeated. By a comparison of the results obtained at these two trials, we may obtain some idea—although not a very accurate one—of the progress of the case. But after all, the sources of error are so many that we often feel disposed to place our chief reliance upon the

patient's own statements, especially if he be a man of intelligence and not given to imagining.

#### THE USE OF THE TUNING FORK.

It is only in exceptional cases that we derive valuable information from the tuning-fork test. Nevertheless, it is a good plan to



FIG. 1.—Heavy Prismatic Tuning Fork, with Movable Clamps. (Half natural size.)

make its use a matter of routine practice in at least the majority of cases. The ordinary forks employed for the purpose of giving a tone of a certain pitch, are of very little use to the aural surgeon. The sound is so feeble in intensity and dies away so quickly that, even if the patient should be able to hear it, the duration of the sound is so very brief that he can scarcely reach a correct conclusion in regard to the auditory sensations which it may have produced before the vibrations will have ceased altogether. The surgical instrument-makers now sell a heavy prismatic fork, of low pitch and provided with movable clamps attached to each arm, which will be found admirably adapted to medical purposes (Fig. 1). By striking one of the arms of the instrument lightly upon the knee, one can call forth sonorous vibrations which continue audible for a period of several seconds—long enough to enable the surgeon to place the handle of the fork on the patient's forehead, just above the bridge of the nose, and to permit the patient to observe calmly in which ear the sound preponderates.

If the preponderance of sound is in the affected ear we may exclude at once any serious disease of the labyrinthine structures or of the auditory nerve at some other point in its course; or, in other words, we may safely assume that the disease is located either in the middle ear or Eustachian tube, or in the external auditory canal. On the other hand, it is not always safe to draw the conclusion that the nervous structures of the affected ear are at fault when the patient refers the preponderance of sound to the unaffected ear.

The latter ear, which he supposes to be unaffected, may happen to be plugged with inspissated cerumen; in which case it will not be surprising if the phenomena

of reflection and re-inforcement of sound should be more marked in the ear supposed to be well than in that which led the patient to consult his physician. An error of this kind, however, will be speedily rectified by an examination of both ears with the speculum and reflected light, and, if necessary, by a repetition of the tuning-fork test after the removal of the mass of cerumen.

To determine the degree of preponderance of sound in one ear it is only necessary to place the handle of the vibrating fork upon some part of the skull more remote than the centre of the forehead from the affected ear. If the degree of preponderance is only slight, the sound will already begin to be referred to the good ear when the handle of the fork is placed on the forehead at a distance of say one inch from the median line, on the side toward the unaffected ear. If the degree of preponderance is marked, the handle of the vibrating fork may be placed on the skull just above the normal ear, and yet the sound will be heard by the patient most strongly in the affected ear, on the opposite side of the skull.

In the absence of a tuning fork a watch held between the teeth may be used as a substitute. If the ticking is too feeble for the patient to hear it in this way, he may be asked to hold a silver spoon suspended from between his teeth. By tapping the spoon lightly with a knife or other object of metal, it may be made to vibrate for an instant or two, and if the patient is a quick observer he will be able to notice in which ear the sound preponderates. At best, however, these makeshifts are poor substitutes for a well-constructed tuning fork.

*Rinne's Experiment.*—The attempt has been made of late to attach a certain degree of diagnostic value to what is known as Rinne's experiment. This is based on the observation, made by Rinne in 1855, that persons with normal hearing are able to hear the sound of a vibrating tuning fork held in front of the auricle, after they have ceased to hear the same fork by direct bony conduction through the teeth and skull. The tuning fork is set in vibration, its handle is placed against the closed teeth or upon the skull of the patient or person experimented upon, and then, when the tone of the vibrating fork ceases to be audible to him, it is quickly transferred to a position where the still feebly vibrating arms of the fork will be close to the orifice of the external auditory canal. If he be a person with impaired hearing, and nevertheless is able to hear the sound through the air after it has ceased to be audible through the bones of his head, the presumption is that the obstacle to good hearing is situated in the labyrinth or in some other part of the auditory nerve, and that the conducting apparatus is not affected.\* On the other

\* This result of Rinne's test is technically called "positive result with Rinne's



hand, if he is unable to perceive the sound of the fork after it has been transferred from the head to the vicinity of the outer orifice of the meatus, the presumption will be that the conducting apparatus and not the auditory nerve is at fault. Post-mortem examinations have been made in three different instances (Bezold, Politzer, and Habermann), and in each instance ankylosis of the stapedio-vestibular joint was found—a confirmation of the correctness of the conclusions drawn from Rinne's test, which had been applied in each case during the patient's lifetime. In each the test had yielded a negative result. Lucae, from whose account in Eulenburg's Real-Encyclopædie I have derived the chief part of my information regarding Rinne's test, lays stress on the importance of using tuning-forks of a low pitch, and preferably those provided with clamps, which prolong materially the duration of the vibrations. Gruber refers very briefly to the test, in the last edition of his treatise on diseases of the ear, and attaches comparatively little value to the results obtained by its employment.

#### EAR SPECULA AND REFLECTORS.

It is a matter of the first importance that the physician who contemplates studying diseases of the ear should be provided with good instruments. Badly devised or clumsily constructed instruments will make it impossible for him, in many cases, to arrive at a correct diagnosis, and, in other cases still, he will, by their use, cause the patient much unnecessary discomfort or even pain.

In a few individuals, the external auditory canal is so broad and straight that the physician can see its walls throughout their entire length, and even the drum-membrane, by direct inspection, without the aid of instruments of any kind. In the majority of persons, however, a satisfactory view of these regions cannot be obtained except with the aid of two kinds of instruments, *viz.*, one to push aside the soft walls of the orifice of the canal (ear specula), the other to illuminate the parts thus rendered accessible (mirrors of various kinds).

*Ear Specula.*—Of the different patterns of ear specula which are offered for sale in the surgical instrument-makers' shops, the cheapest and at the same time the best are those known by the name of Wilde's ear specula. These instruments have the shape of truncated hollow cones; they are of coin silver, and are polished within and without. For all ordinary demands, three different sizes will be found sufficient. They should not exceed

experiment (+ R);" but when the patient fails to hear the fork through the air after it has ceased to be audible by bony conduction, the result is expressed as "negative result with Rinne's experiment (-R)."

three and a half centimetres ( $1\frac{1}{2}$  inch) in length. The aperture at the smaller end of the instrument should measure not less than three and a half millimetres ( $\frac{1}{2}$  inch) in diameter, for the smallest of the three sizes of specula, and not more than eight millimeters ( $\frac{1}{4}$  inch) for the largest. The walls of the instrument should be no thicker than is sufficient to prevent them from bending under ordinary manipulations. Thick-walled specula rob us of valuable space and diminish to a proportionate extent the degree of illumination.



FIG. 2.—Wilde's Ear Speculum. (Natural size.)

*Reflectors.*—Two kinds of contrivances are generally used for the purpose of reflecting light into the external auditory canal, *viz.*: the *hand-mirror* and the *forehead-mirror*. So far as the mirror itself is concerned, these two are one and the same thing. In practice it has been found that the best illumination is obtained with a concave mirror of circular form, whose focal distance may vary from twelve to thirty centimetres (5 to 12 inches), according to the visual power of the observer. The majority of men will find a focal distance of about twenty centimetres (between 7 and 8 inches) the best adapted to their purposes. With regard to the size of the mirror, it may be said that one having a diameter of seven centimetres ( $2\frac{1}{2}$  inches) is as large as the observer can conveniently handle. Almost all the mirrors offered for sale have a central aperture or unsilvered spot, through which the observer can see the parts illuminated directly in the focal line. If the hand-mirror be used, it is probably better to place the eye in the focal line than to look over the edge of the mirror. At the present day, however, all students of otology who are not near-sighted should be taught to use only the forehead-mirror. While at first it may be found more difficult to manipulate than the hand-mirror, its advantages over the latter are so great as to more than compensate for the difficulties encountered in learning how to use it properly. These difficulties once overcome, the physician no longer requires an assistant, but has both hands free for the various manipulations which are required in even the simplest case. The forehead-mirrors usually sold in the shops, and commonly pictured in the text-books, are very poorly adapted to the wants of an aural surgeon; some of them are in fact absolutely useless for his purposes. If we examine these instruments carefully, we shall find that they are fundamentally wrong in two respects: first, no space—or insufficient space—is left between the forehead-plate and the upper edge of the mirror, thus rendering it either difficult or impossible for the observer to see the ear; second, the ball-and-socket joint, by which the mirror is attached to the fore-

head-plate, allows the former to be rotated to such a limited extent, both from side to side and from before backward, that the observer will often find himself unable to use the source of light that may happen to be available, unless he changes its position or that of the patient, or both. If the forehead-mirror, however, be properly constructed, the observer will find comparatively little difficulty in placing himself in such a position that he can utilize almost any source of light that he may find at hand. The accompanying cut (Fig. 3) gives a correct representation of a forehead-mirror well adapted to the wants of the aural surgeon. The details of construction are as follows: The forehead-plate is made of hard rubber,  $9\frac{1}{4}$  centimetres ( $3\frac{3}{4}$  inches) long,  $2\frac{1}{2}$  centimetres (1 inch) broad at the broadest part, a trifle more than a millimetre (or about  $\frac{1}{16}$  inch) in thickness, and curved flatwise, so as to lie at all points in firm contact with the forehead. This concave side should not be padded, partly for reasons of cleanliness, and chiefly because such padding materially diminishes the stability of the mirror when once adjusted to the observer's forehead. At both ends of the plate there is a long and narrow opening, through which the forehead-band or strap is to be inserted. A word or two with regard to the latter. The dealers are in the habit of furnishing forehead-bands of elastic material covered with black cotton or silk. In summer time, or in a warm room, the dye is set free by the perspiration, and the physician finds a black stain on his temples wherever the band has touched the skin. To obviate this annoyance the forehead-band should be made partly of undyed leather and partly of elastic (or non-elastic) material. The leather portions should begin at either end of the forehead-plate and should extend to a distance of twelve or thirteen centimetres (about 5 inches) from these. Beyond these limits an elastic or non-elastic band of any material or color may be used. The adjustment of the band to the size of the head is effected by means of a buckle.

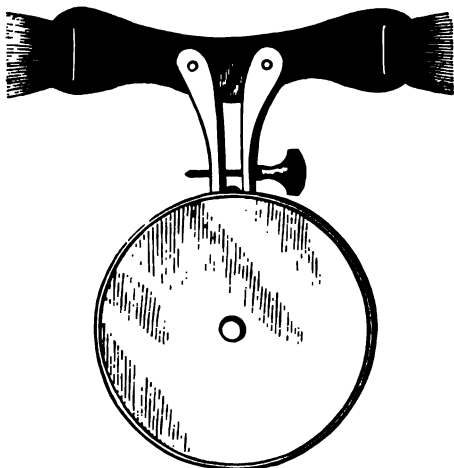


FIG. 3.—Forehead-mirror. (Half the natural size.)  
(For cut of mirror in actual use, see page 14.)

er's forehead. At both ends of the plate there is a long and narrow opening, through which the forehead-band or strap is to be inserted. A word or two with regard to the latter. The dealers are in the habit of furnishing forehead-bands of elastic material covered with black cotton or silk. In summer time, or in a warm room, the dye is set free by the perspiration, and the physician finds a black stain on his temples wherever the band has touched the skin. To obviate this annoyance the forehead-band should be made partly of undyed leather and partly of elastic (or non-elastic) material. The leather portions should begin at either end of the forehead-plate and should extend to a distance of twelve or thirteen centimetres (about 5 inches) from these. Beyond these limits an elastic or non-elastic band of any material or color may be used. The adjustment of the band to the size of the head is effected by means of a buckle.

As to the mirror itself, I have already described it sufficiently. Its mode of attachment to the forehead-plate is, however, a matter of great importance. All the contrivances used for this purpose are based upon the principle of the ball-and-socket joint. The majority of them, however, as I have already stated, allow so little freedom of motion that the physician often finds himself unable to use the source of light at his command. In the first place the ball should be attached, through the medium of a strong stem (of solid brass), to the metal back of the mirror (see Fig. 4). This stem should be fastened to the mirror at a distance not exceeding seven millimetres (or about  $\frac{1}{4}$  inch) from its circumference. The point at which the stem broadens out into the ball should also be seven millimetres distant from the back of the mirror, and the ball itself should measure about one centimetre ( $\frac{1}{2}$  inch) in diameter. The socket in which the ball revolves consists of two segmental sockets hollowed out of the ends of two brass shanks, which are attached, each by a single rivet, to the convex side of the forehead-plate. The length of each shank is five centimetres (2 inches). By means of an adjustable screw, which passes through a slot in one shank, the mobility of the joint may be increased or diminished at will.

If we examine such a mirror as I have endeavored to describe, we shall find in the first place that it may be rotated unusually far forward, thus enabling the observer to use a source of light situated comparatively high above the patient's head. In the second place, the mirror may be rotated so far toward one side or the other that the observer can use a source of light situated close to the extremes of either side. In the third place, we are not so strongly tempted to close one eye, when using the forehead-mirror in the manner shown in Fig. 5, as we are when looking through the central aperture of the hand-mirror. Only one eye does the real work of examination in both cases, but in using the forehead-mirror we are not conscious, in the slightest degree, that we are not observing the object with both eyes in the ordinary manner. Finally, if it be found desirable to inspect the illuminated parts in the focal line—or, in other words, to secure the maximum degree of illumination—the mirror can readily be rotated in such a manner as to bring the central aperture in front of either eye. Unless a

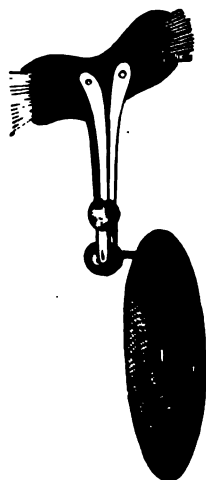


FIG. 4.—Forehead-mirror. Profile view.

mirror can fulfill all these requirements it may safely be assumed that the instrument is not as perfect as it is possible to make it.

I have gone thus minutely into the details of construction and advantages of the forehead-mirror because I have observed that the use of the hand-mirror in aural examinations is still very common, not only in this country but also on the continent of Europe. As no one who has once experienced the comfort of working with a good forehead-mirror would ever think of returning to the habitual use of the hand-mirror, I can only explain the widespread use of the latter instrument by assuming that no really good forehead-mirror has been brought to the notice of the profession. The one which I have described is essentially the same as that which was first shown to me in 1870 by Dr. Robert F. Weir of this city, and which he had been using, if I remember rightly, for several months previously.

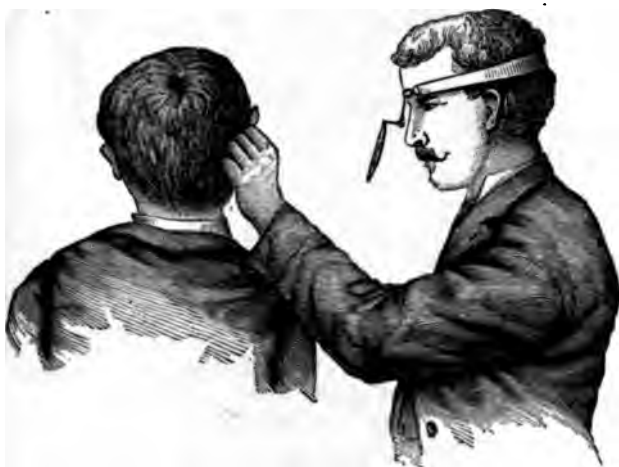

FIG. 5.—Forehead-mirror in Actual Use.

The forehead-mirror is to be worn in the manner represented in the accompanying cut, *i. e.*, with the ball-and-socket joint resting upon the bridge of the nose, and the mirror itself projecting at a still lower level. As our ordinary sources of light are almost invariably situated at a level higher than that of the examiner's eyes, the plan adopted by some, of resting the mirror against the forehead, will be found rather awkward in aural examinations.

If for any reason it is thought desirable to magnify the object under examination, a lens of suitable focal distance may be held between the eye of the observer and the speculum. A person

with good eyesight, however, will gain but little, if any, additional information by the use of lenses in the examination of the ear.

INTRODUCTION OF THE SPECULUM AND USE OF THE REFLECTOR.

If the physician wishes to introduce a speculum into the ear in such a manner as to gain a satisfactory view of the membrana tympani and deeper parts of the external auditory canal, without causing his patient either harm or unnecessary discomfort, he must first become acquainted with at least the more important points in the anatomy of these parts. I will therefore enumerate here, very briefly, those peculiarities in the anatomy of the external auditory canal which seem to me to have an important practical bearing upon the procedure which we have undertaken to describe.

*Anatomical Considerations.*—In infancy, the external auditory canal

is almost entirely composed of soft tissues, and the drum-membrane lies but little below the surrounding surface of the skull. (Fig. 6). In older children and in adult life the inner half of the canal consists of a cylinder of bone, the inner end of which is spanned by the drum-membrane. There are still other anatomical differences between the infantile canal and that of adult life, which bear directly upon this question of examinations of the ear. In infants the drum-membrane faces chiefly downward, while in adults it faces chiefly outward. Again, in infants the soft walls of the meatus tend to collapse and lie in contact with each other, the general direction of the canal from the drum-membrane being outward and upward. It should also be kept clearly in mind that in the infant at birth the little ring of bone (annulus tympanicus, Fig. 7) in which the drum-membrane is set, and to which the membranous meatus is firmly fastened, is itself still very feebly attached to

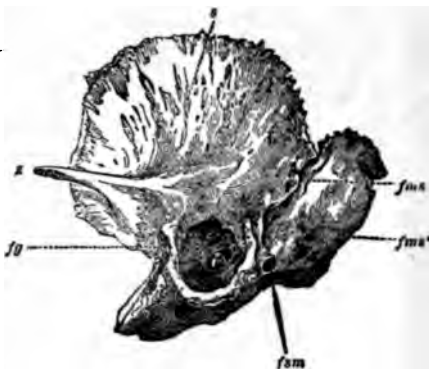

FIG. 6.—Temporal Bone of Newly-born Child, showing Annulus Tympanicus in its normal attachments to the bone. *a*, squamous portion; *fms*, *fms'*, fissura mastoidea squamosa; *fg*, fissura Glaseri; *fsm*, foramen stylo-mastoideum. (After Gruber.)



FIG. 7.—Annulus Tympanicus of Newly-born Child, separated from its attachments. (After Gruber.)

the squamous portion of the temporal bone. Finally, in adults, the cartilaginous portion of the meatus tends to droop downward and forward (Fig. 8). As the framework of this portion

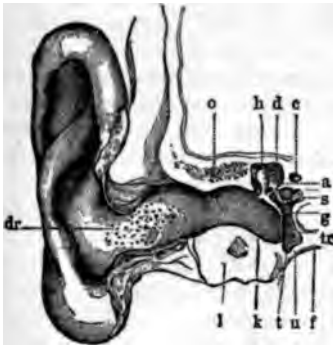

FIG. 8.—Vertical Section through the Right External Auditory Canal, Drum Membrane and Middle Ear. *o*, cellular spaces in the upper bony wall of the canal (these cells communicating with the cavity of the tympanum); *d*, roof or tegmen of the tympanum; *t*, tympanum; *u*, lower wall of the same; *tr*, membrana tympani or drum-head; *h*, head of hammer; *a*, anvil; *s*, stirrup; *c*, canal of Fallopius; *f*, fossa jugularis; *dr*, mouths of glands at orifice of the external auditory canal. (After Politzer.)

of the canal is not composed of a solid plate of cartilage, but is provided with several fissures (Santorinian fissures, see Fig. 9) spanned by elastic tissues, it will be found to possess a very considerable degree of mobility. In old age, however, these fibrous portions, which play, in a measure, the part of hinges, become stiff and hard from the abundant deposit of calcareous material, and the natural mobility of the canal is thereby seriously diminished. These, I believe, are the only important points that have a direct practical bearing upon the subject of the introduction of the aural speculum.

*Sources of Light.*—In the examination of the ear with either the hand- or the forehead-mir-

ror, it is not necessary to procure any other source of light than those which can almost always be found in every house.

Direct sunlight is so dazzling that we cannot use it with either comfort or advantage. Ordinary daylight, such as can be obtained by directing our mirror toward the sky above the horizon, or toward the white wall of a house near by, generally affords sufficient illumination for ordinary purposes. If the window of the room looks out upon a narrow street, it will be found better to trust to artificial light. In our larger cities the argand gas-burner probably furnishes the most brilliant and steady source of light that can readily be found. In office practice some kind of movable fixture should be used, in order that the light can

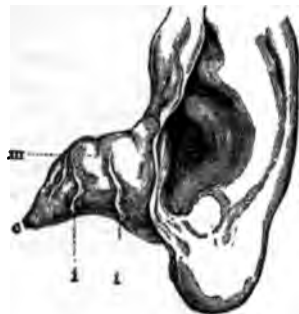

FIG. 9.—Auricle and Cartilaginous Portion of the External Auditory Canal. *m*, cartilaginous meatus; *c*, inner pointed end of the same; *i*, fissures of Santorini (incisurae Santoriniana);—Left ear. (After Politzer.)

of movable fixture should be used, in order that the light can

readily be placed at different levels, according to the height of the patient. The ordinary gas-flame, the light of a kerosene lamp, or even that of a candle, will afford all the illumination required in the great majority of cases. The interposition of lenses, for the purpose of increasing the brilliancy of the illumination, is superfluous.

*Position of the Patient in Relation to the Light.*—The physician should try and acquire the power to use sources of light situated in all imaginable positions. As a matter of course the light must occupy such a position that when the observer's face is directed toward the ear that is to be examined, he can see the flame or other source of illumination by simply turning his *eyes* in the proper direction. If he is obliged to turn his *head*, however, in order to see the light, it is certain that he will not be able, by means of his mirror, to reflect any of it into the patient's ear. In the next place, the source of light (if an artificial one) should not be at too great a distance from the observer, as in that case the illumination of the auditory canal would be rather feeble. The best position for the light is at a point a short distance behind and on one or the other side of the patient, not more than three feet from him, and about a foot above the level of the ear to be examined. If the light occupies a position on the observer's right-hand side, and is at the usual height above the patient's ear, there is a strong probability that in his manipulations with the right hand he will intercept the rays of light, and so shut off his view of the object under examination. If it happens, however, to be more convenient for him to use a source of light which is situated on his right side, he can readily avoid the difficulty just alluded to by raising the light to a higher level, thus enabling the rays to reach the mirror over his right arm. Probably the best plan for the beginner is to draw his illumination from a source which is situated on his left side. After he has acquired practice in using the forehead-mirror, it will make very little difference to him what position the light occupies, provided it be not on a lower level than the object under examination, and provided, of course, that it can be readily seen by the observer when his face is turned toward the ear of the patient.

*The Actual Examination.*—After the physician has acquired a certain degree of skill in the management of both speculum and mirror, he will find very little difficulty in adapting himself to the different circumstances under which he may find it necessary to make an examination of the ear. To lay down rules for all these varying conditions would simply be a waste of time. It will be sufficient if I describe the proper mode of procedure to be followed when the patient can be placed in the position which best suits the comfort of the physician who makes the examination.



Thus, for example, if the left ear be the one that we wish to examine, and if the patient be an adult, he should be made to sit in such a position that he will have the light in front of him, a little toward his right side and a few inches above the level of his eyes. The physician, of course, sits directly facing the patient's left ear. The patient's ear should be as nearly as possible on the same level with the observer's eyes. Where this is not the case, the patient's head must be bent toward one or the other side, until the long axis of his external auditory canal corresponds with the observer's axis of vision. The next step is to cause the reflected rays of light to fall directly upon the ear. In this connection there are one or two practical points to which attention should be called. In the first place, it is not necessary, with a mirror whose focal distance is about twenty centimetres, to observe whether the rays have been brought to a focus in the auditory canal, or several centimetres this side of it in the axial line of the canal. In other words, the illumination along the axial line, for a distance of several centimetres on either side of the focal point, is amply sufficient for all practical purposes. Hence, the observer, in examining an ear by the aid of a forehead-mirror, should hold his head in that position in which he can best see the parts to be examined. In the second place, in his efforts to cause the rays of light to fall upon the ear, he should not use the motions of the neck as a means of attaining this object. It is far better to fix the head in the proper position for observing the parts comfortably, and then rotate the mirror in its ball-and-socket joint until he finds the position in which it reflects the light in the direction desired. This done, the observer is ready to introduce the speculum and proceed with the examination.

Until we have learned by actual experience how large a speculum the ear under examination will admit, it is best to begin arbitrarily with one of medium size. The ear to be examined, we will suppose, is the left one. Holding the instrument between the thumb and forefinger of the left hand, and lifting the auricle upward and backward with the right hand, we should introduce the speculum cautiously into the orifice of the canal. As we push the instrument farther and farther inward, by a sort of boring motion, we should keep the eye directed upon the parts illuminated at the bottom of the speculum. By thus watching the progress of the inner end of the instrument, we shall be able to introduce it as far as we desire without causing the patient pain or even discomfort. In lifting the auricle upward and backward, while introducing the speculum, it makes no difference which hand is employed for the purpose, though it is, of course, easier to employ the right hand for the patient's left ear, and the left for his right. After the speculum is in position, however, and

we desire to use the right hand for operative or other purposes, the traction upon the auricle and the maintenance of the speculum in a steady position must be given over to the left hand. To accomplish this easily, the fore and middle fingers should be used for the purposes of traction, while the thumb is left free to steady the speculum.

With regard to the question of how far the speculum should be introduced into the meatus, it may be said that as soon as the instrument has reached a position in which a clear view of the membrana tympani and deeper portions of the canal can be obtained, nothing will be gained by pushing it farther inward. With Toynbee's and Von Troeltsch's specula it is an easy matter for a rough or careless operator to injure the deeper parts of the canal. With Wilde's conical specula and the broad-mouthed instruments of Gruber, however, the danger is greatly lessened.

In infants, the mode of procedure described above must be slightly modified, on account of the anatomical differences already mentioned. Thus, for example, it is generally necessary to overcome the collapsed state of the membranous walls of the canal by pulling the entire canal symmetrically outward. One way of accomplishing this is to exert slight upward and backward traction of the upper part of the auricle with one hand, and an outward, or outward and downward traction of the lower part with the other. A better way is to accomplish this combined movement by means of the fore and middle fingers of only one hand, the speculum being held in position by the thumb. But the exact mode of arranging the fingers is a problem which each one must, in the main, work out for himself, as the procedure is one that scarcely admits of satisfactory description.

*Accessory Instruments used in the Examination of the Ear.*—In a large proportion of the cases that come before us we find that the speculum and mirror are the only instruments required for obtaining a full and satisfactory view of the external auditory canal and drum-membrane. In a certain number of cases, however, we find the view obstructed by the presence of various substances such as cerumen, hairs, scales of epidermis, pus, etc. These must, of course, be removed, if we desire to see clearly the parts beyond, and for this purpose one or more of the following instruments may be employed: angular forceps, cotton-holders, probes and cures, and the syringe. I mention the syringe last, because I believe it to be the clumsiest and in some cases the least efficient of the means enumerated. Farther on I shall have occasion to discuss the merits of this instrument more fully.

A well-constructed pair of *angular forceps* is an invaluable instrument to the aural surgeon. He should be provided with

two patterns of the instrument—a rather stout pair (Fig. 10) which he can use in removing large bodies that are near the outer orifice, and a slender pair (Fig. 11), that can be employed in the deeper parts of the canal.

The long arms or blades of the more slender instrument should

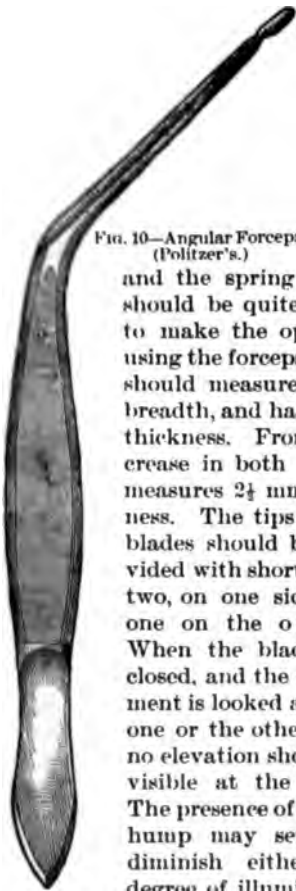


FIG. 10.—Angular Forceps (Politzer's.)

measure about six and a half or seven centimetres in length. If they are less than six centimetres in length, some difficulty may be experienced in illuminating the object which it is proposed to remove, during the actual operation. The shorter arms should measure about six centimetres (2½ inches) in length, and the spring which they form by their union should be quite feeble. A stiff spring is very apt to make the operator's hand tremble when he is using the forceps. At its extreme free end the blade should measure a trifle less than a millimetre in breadth, and hardly three-fourths of a millimetre in thickness. From this point it should gradually increase in both dimensions, until near the angle it measures 2½ mm. in breadth, and 1½ mm. in thickness. The tips of the blades should be provided with short teeth, two, on one side and one on the other. When the blades are closed, and the instrument is looked at from one or the other side, no elevation should be visible at the angle. The presence of such a hump may seriously diminish either the degree of illumination

or the extent of the field of vision. In the next place, it is important that, when the free extremities of the blades are brought close together, the stouter portions at the angle should not be too far apart. In a good instrument, if no greater

force is exerted than is sufficient to make the toothed ends interlock, the distance between the blades at the angle should not exceed a millimetre and a quarter or a millimetre and a half (or the total diameter of both blades, with

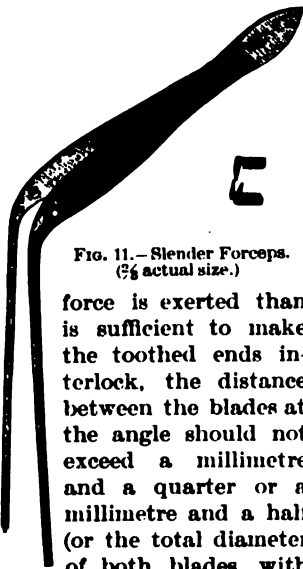


FIG. 11.—Slender Forceps. (2/3 actual size.)

force is exerted than is sufficient to make the toothed ends interlock, the distance between the blades at the angle should not exceed a millimetre and a quarter or a millimetre and a half (or the total diameter of both blades, with

the intervening space, should not exceed five millimetres). Finally, in examining a number of these slender forceps, apparently all alike in other respects, I have observed that, when more force was used than was sufficient to bring the blades in contact with each other throughout their entire length, the interlocking toothed ends separated, in some instances quite widely. While this is an extremely annoying fault in a pair of forceps, it is also one that can be readily discovered at the time of purchasing the instrument. A third pair of forceps, exactly like that shown in Fig. 11, with the exception that the ends are not toothed (simply flat and roughened where the tips meet), will be found a useful addition to the surgeon's armamentarium.

Of the stouter forceps, I like best the pattern which is sold in the shops under the name of Politzer's forceps (Fig. 10). As this instrument is not intended for delicate work, it is not necessary that I should devote any space to the consideration of the details of its construction. As usually found in the shops, it is a sufficiently good instrument for all the purposes to which the physician is likely to apply it. If he desire to purchase only one pair of forceps, it is certainly better for him to have in his possession the slender pattern.

*The Cotton-holder* is an exceedingly useful instrument to the aural surgeon. It consists of a slender rod of malleable steel, about twelve centimetres in length, which is slightly roughened at one end, for the reception of the cotton, and at the other broadens out into a short and rather thick handle. For ordinary purposes, a cotton-holder with a shank of 1 mm. in diameter is the best size. For the more delicate manipulations which are sometimes required in the middle ear (with a perforated drum-membrane), an instrument with a shank of not more than half a millimetre in diameter will be found more appropriate. It is a common fault of the cotton-holders sold in this city that the ends are too much roughened, thus rendering the removal of the mass of cotton at times an exceedingly difficult matter. With the nail blade of a pocket-knife, however, it is easy to remedy this defect in a very few moments. It is a much more difficult matter to apply the cotton to the holder quickly, neatly, and firmly. To describe the procedure intelligibly is a task which I can hardly hope to accomplish satisfactorily, and I therefore prefer to let my readers work out each one a method for himself. The most important point, as a matter of course, is to cover up the comparatively sharp end of the instrument so thoroughly with the cotton that no harm can be done with it. With regard to the uses to which the instrument, thus armed, can be put, I may say in general that it affords the quickest and best means, known to me, of removing from the ear fluid or semi-solid substances. The



cotton-holder is also employed for other equally important purposes, but of these we shall make mention in subsequent chapters.

*Probes and Curettes* are important accessory instruments. In very many cases simple inspection of the parts leads us to wholly erroneous conclusions with regard to the true state of things. Thus, for example, simple inspection would perhaps justify us in making the diagnosis of a swollen and ulcerated condition of the posterior half of the membrana tympani ; while inspection com-

combined with the proper use of the probe or curette, might reveal the existence of a polypoid mass that originated in the tympanic cavity, forced itself through a comparatively small perforation, and then spread itself out over the posterior half of the drum-membrane. I might enumerate many other pathological conditions which even the most skilful specialist would be very likely to interpret incorrectly if he did not use the probe as a means of correcting or confirming his first impressions. Of course, if obstacles intercept the view, these must first be removed ; and here the probe or the curette may also serve an excellent purpose. Both of these instruments, however, must be delicately constructed or the physician will find them of very little use, either as aids in making a correct diagnosis, or as substitutes for the forceps and syringe. The most essential details of construction of these instruments are the following : The probe (Fig. 12) should be made of a single rod of soft silver, and for a distance of 8 ctm. from one end it should be finished with four sides (each 1.5 mm. in diameter) in order to furnish a good hold for the fingers. This handle portion of the probe should merge gradually into a slender shank, less than half a millimetre in diameter, and terminating in a small knob, about three-fourths of a millimetre in diameter. A total length of 15 ctm. will be found amply sufficient. The curettes should be made of steel, and their handles should be of the same length as that of the probe, but they should be

eight instead of four-sided, and correspondingly heavier (diameter of nearly four millimetres). The shank, at the point where it broadens out abruptly into the handle, measures 1.5 mm. in diameter ; at the point where it joins the ring, it measures but 0.5 mm. in diameter. The handles and shanks of the two different sizes of curettes are precisely alike ; the only difference is in the side of the rings. Both are oval in shape, the smaller one measuring 3x2 mm., the larger one 5x4 mm. (external measure-



FIG. 12.—Slender Silver Ear Probe (¾ actual length).

ment). Their thickness, from one flat side to the other, is about 0.3 mm.; measured transversely, from the outer to the inner side of the ring, it is about 0.6 mm. in the larger curette, and about 0.3 mm. in the smaller one. The outer edges should be nicely rounded, and not left sharp. Although I have never written or said anything about using these instruments for scraping purposes, I was recently very much surprised to find that some of those offered for sale in the shops were so constructed that they could only be used as scrapers; that is, the flattened sides of the ring looked downward, *i.e.*, in a direction at right angles to the long axis of the shank, and the edges were left sharp; while in the curettes which I have always used and recommended, the flat part of the ring and the shank are in one and the same plane, and the edges are well rounded. For all purposes of lifting, loosening and separating any and all sorts of abnormal products or growths in the auditory canal, the latter type of instrument is admirably adapted, while the other is perfectly useless. On the other hand, I very much doubt whether the slenderness of the shank would permit these sharp-edged curettes to do effective work in the only direction in which they seem fitted to be of any use—that is, in scraping away carious bone. Under certain circumstances, it will be found desirable to bend the shank slightly near its attachment to the ring. This part of the shank, therefore, should be left untempered.

*The Syringe.*—With regard to the use of the syringe it is not an easy matter to lay down any well-defined rules. It is a very common practice to use this instrument with warm water for the removal of any and all sorts of obstacles in the external auditory canal, whether they be large or small, hard or soft. A distinguished writer on surgery once gave the advice that no instrument smaller than the elbow should ever be introduced into the ear, and the general acceptance of this doctrine as unimpeachably sound, probably furnishes the correct explanation of the fact that syringing is looked upon as the only safe method of clearing away obstacles from the auditory canal. All manipulations about this organ, it should be remembered, call for delicacy of touch, steadiness of hand, and the ability to so manage the illumination that the surgeon shall see distinctly everything that he does in the external auditory canal. Hence it is perfectly legitimate for one who undertakes to instruct in the art of curing ears, to assume that his readers are not so reckless



FIG. 13.—Steel Curette with Rounded Edges ( $\frac{1}{4}$  actual length).

or so clumsy as to deliberately injure their patients. If they are men of this stamp the advice of the distinguished surgeon is undoubtedly eminently appropriate for them; but to those who wish to learn the surest and most effective means of bringing the membrana tympani into full view, and are willing to take the trouble to acquire the manual skill and delicacy of touch requisite for the effective and painless employment of the instruments described above, I would give the advice to use the syringe only when circumstances compel them to use it. If the latter instrument could always or even generally be trusted to effect the desired object I should feel as if I were not quite justified by the facts in laying so much emphasis upon the employment of these instruments; but the truth is, that in a very large number of cases it is utterly impossible to obtain a satisfactory view of the membrana tympani and deeper parts of the ear unless we resort to instrumental interference such as I have described. In fact, there are not a few cases, as we shall learn farther on, in which the most experienced observer will find that the appearances presented to his eye are not what they seem to be, and that the true anatomical relations can only be learned by touching and moving the different parts upon which his eyes are fixed.

Here are a few hints that may serve in lieu of rules:

1. Soft cerumen or abundant foul pus should preferably be removed by syringing.

2. Hard cerumen or laminated masses of desquamated epidermis should be loosened from the surrounding walls of the canal by means of the curette. Oftentimes, especially in canals of large size, the mass may then be extracted entire by means of the angular forceps (preferably Politzer's). If the canal is not of large size, the curette may be used to loosen and break off sections of the mass, which may thus be removed piecemeal, either by means of the slender angular forceps or by using the curette somewhat as one would use a hoe.

3. When the outer portions of such a mass have been removed, and it is found that the inner part remains wedged in between the drum membrane and the anterior and upper wall of the canal, the curette should be used to open a small passage between the mass and the upper wall of the canal, as far inward as to the drum membrane if practicable. Then, by directing the stream of water from the syringe toward this artificial channel, one may often succeed in exerting a *vis à tergo* sufficient to dislodge the impacted mass.

4. Small objects like hairs, scab-like formations, etc. can always be readily got out of the way by aid of the curette or the slender forceps, or by wiping them away with a little cotton wound around the end of a cotton-carrier.

A good ear-syringe should have a piston that works easily. This is the first and most important requirement. In the next place, it should be provided with some contrivance which will enable the operator to alternately fill and discharge the instrument with one hand. This object is commonly attained by having the handle of the piston terminate in a ring large enough to admit the thumb, while two other rings large enough to admit the fore and middle fingers are fastened opposite to each other on the base of the cylinder. In the hard-rubber ear-syringes the neck of the cylinder is hollowed out in such a manner as to afford to the fore and middle fingers all the support that they receive from the rings in the metal instruments. With regard to the size of cylinder best adapted to the requirements

good ear syringe, I may say that, in general, it is better to employ an instrument of rather large capacity. Nevertheless, the one-ounce hard-rubber ear-syringes usually sold in the shops (Fig. 14), fairly answer all the reasonable requirements of a good syringe. Olive-pointed nozzles are not to be commended; those which are shaped like that in the accompanying cut are decidedly preferable. The terminal tip or spout should not exceed four millimetres (a little over one-eighth of an inch) in diameter.

The water employed in syringing the ear should have a temperature of about 100° F. In the case of adults we must be prepared to hear the patient complain of feeling dizzy or faint. This is by no means an uncommon experience. In some cases we can attribute this symptom to the temperature of the water used—either too hot or too cold,—or to the employment of too great force in driving in the piston. In others, however, the symptom will develop despite every precaution on the part of the physician. One or two unpleasant experiences of this nature have led me to adopt the rule of asking the patient from time to time, during the progress of the operation, whether he experiences either dizziness or faintness. In this way we may obtain timely warning of the necessity of discontinuing the operation or at least intermitting it for a time.

A few words may be added in regard to the different steps of the procedure. The patient's neck and shoulder should first be protected with a towel, and he should be given a glass finger-bowl or a mug to hold beneath his ear. The shallow hard-rubber or metal basins sold by the instrument-makers for this latter purpose are thoroughly unpractical. A sudden



FIG. 14.—Hard Rubber Ear-syringe.



motion of the patient's body is apt to cause the contents of the basin to spill over upon his person, while if a mug, bowl, or other deep vessel be used, the same accident is much less likely to occur. In the majority of cases the bowl or mug may be used both as a reservoir from which to fill the syringe and as a receptacle for catching the water that runs out from the ear. If the proper conveniences, however, are at hand, it is better to fill the syringe from a separate vessel, as sometimes the matters which are washed out from the ear block the canal of the nozzle, and so cause trouble. After we have filled the syringe with the right hand, we must straighten the patient's external auditory canal with the fingers of the left hand, in the manner described when speaking of the introduction of the speculum. This done, the nozzle is to be introduced a short distance—roughly estimated, not more than

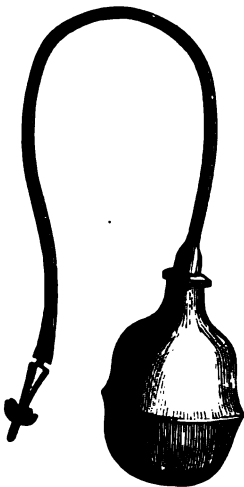


FIG. 15.—Angelo's Ear Douche half an inch—into the meatus, and the water thrown in with little or great

force, according to the nature of the conditions which led to the use of the instrument. If we are not pointing the syringe in the right direction, or if we have pushed the nozzle too far into the ear, the patient will be very likely to reveal the fact by the expression of his countenance. No description, however, can serve as an adequate guide to the successful carrying out of this procedure, which physicians are apt to consider a very easy task, but which is often quite the reverse. In infants the hard rubber or the metal syringe must be used with great caution. The fountain douche or some form of bulb syringe is a much safer instrument to use provided it be furnished with a suitable nozzle, one that cannot be introduced too far into the external meatus. The nozzles usually supplied with the douche are either so large that it is impossible to do effective work with them, or so slender and sharp-pointed that they may easily injure the canal or even the drum-membrane itself. In some of the shops it is now possible to purchase a pattern of ear douche which is sold under the names of "Angelo's Ear Douche," and "Reyders' Ear Douche," and which is free from



FIG. 16.—Nozzle of Angelo's Ear Douche. (Actual size.)

these objections. (See Figs. 15 and 16.) It consists of four parts, all easily removable, *viz.*: a white rubber bulb or reservoir, a hard-rubber stem to fit into the neck of the bulb, a piece of soft-rubber tubing about eight or ten inches long, and a terminal pronged ear nozzle. The latter is made of hard rubber, and is provided with four prongs which are symmetrically placed around the nozzle, each at a distance of about half an inch from the free end. The diameter of the nozzle at the tip is three and one-half millimetres; at the bases of the prongs it is about four millimetres. The prongs themselves project about six millimetres from the sides of the nozzle, and they are inclined a little backward, away from the tip. With such a nozzle, which can easily be slipped out from the rubber tubing and attached to the tubing of a fountain douche, the patient himself, or the mother, in case of a child, can easily be taught to cleanse the deeper parts of the external auditory canal as safely and as efficiently as it can be done by the physician with a well-constructed syringe.

## CHAPTER II.

### GENERAL PATHOLOGY.

THE organ of hearing is made up of a variety of tissues, disposed for the greater part in cavities which are either out of sight or are difficult to see and explore. In a rough way we may describe these cavities as surrounded on all sides by dense bone, sometimes very thick, and in only a few places noticeably thin. For reasons of convenience it is customary to speak of the three



FIG. 17.—Diagrammatic Representation of the Transmitting Apparatus of the Middle Ear. *M.A.E.*, Meatus auditorius externus; *MT*, membrana tympani; *M*, hammer or malleus; *I*, anvil or incus; *S*, stirrup or stapes; *L*, labyrinth; *FR*, fenestra rotunda.

anatomically different cavities as *the internal, the middle, and the outer ear*. The latter is simply an elongated cul de sac lined with skin and open at its outer end. The middle ear is a very complicated system of cavities, absolutely shut out from the outside world except through a long, narrow, and, for a large part of the time, closed channel which opens into the vault of the pharynx. These cavities are lined with a thin mucous membrane, which also plays the part of a periosteum or nourishing membrane for the underlying bone. In the chief one of these communicating cavities, *viz.* the tympanum proper, is placed an isolated arch of three ossicula. (See Fig 17.) This arch springs from the centre of the tympanic membrane and is inserted into the larger of the two openings that lead into the labyrinth, *viz.*, the oval window. This

arch is the connecting link between the sounds of the outside world and the nervous apparatus whose function it is to analyze them and convey them to the brain in the form of words, musical tones and noises. (See also Fig. 18). The mucous membrane which lines all the other parts of the many-chambered middle ear also covers every portion of the bony arch. At three points, and only three, there is a break in the continuity of the bony walls of the middle ear: the beginning of the channel leading to the pharynx (the Eustachian tube), the tympanic membrane, and the membrane which spans the fenestra rotunda—the

smaller of the two openings that lead into the labyrinth. The latter system of cavities, which is the last of the three enumerated above, is commonly spoken of as the inner ear. It has absolutely no direct communication with the outer world. It is practically, therefore, a serous cavity. In it is lodged the terminal expansion of the auditory nerve,—a complicated mechanism made up of a variety of beautiful structures. Later, we shall see how disease may invade this inner sanctuary, but generally it escapes in great measure the rude attacks of inflammation which involve the neighboring middle ear.

Putting to one side, for the moment, the few other diseases or abnormal changes which may take place in the ear, we may say

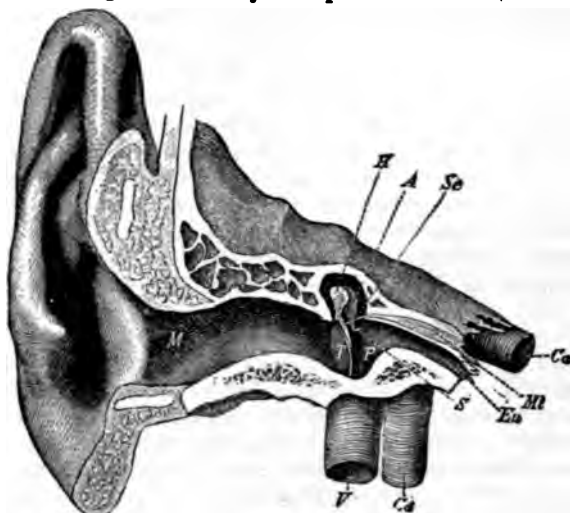


FIG. 18.—Anatomical Relations of External Auditory Canal, Middle Ear, etc. *M*, external auditory canal; *H*, hammer; *A*, anvil; *Se*, tendon of the tensor tympani muscle; *Mt*, tensor tympani muscle; *Eu*, Eustachian tube; *S*, stirrup; *P*, promontory, or inner wall of tympanum; *T*, membrana tympani; *Ca*, carotid artery; *V*, jugular vein. (After Hartmann.)

that it is the chief task of aural pathology to set forth and make plain the different changes which inflammation may produce in the three different cavities described above. We shall get a much clearer idea of "diseases of the ear" if we grasp and hold on firmly to this simple conception of a single morbid process, which, however, may vary greatly in its essential character, in its localization, and in its issues. In harmony with this idea, then, it may be truthfully said that in ninety-nine out of one hundred cases of ear disease, the physician's task consists in finding out—(1) in which of the three cavities named the inflammation began; (2) the extent to which it has involved that particular

cavity or system of cavities; (3) whether it has involved one or both of the neighboring cavities, and perhaps even remoter structures not belonging to the ear; (4) what are its essential characteristics; and, finally, (5) what are the alterations which it has produced in the tissues affected and in the secretions of the part. To make these points somewhat clearer I will consider each of them briefly in turn.

1. *The Locality first Affected by the Inflammation.*—The external auditory canal is sometimes the seat of a primary inflammation which shows no tendency whatever to extend inward toward the cavity of the middle ear. At most, it will involve the outer aspect of the membrana tympani, which portion of the membrane, however, is an essential part (anatomically speaking) of the external auditory canal. On the other hand, a primary inflammation of the middle ear—in the strict sense of the term—is rarely if ever encountered. In the vast majority of cases the primary inflammation develops in the upper part of the pharynx, and spreads thence to the middle ear. The only apparent exceptions are the cases of middle-ear inflammation that have developed as the result of syphilis, scarlet fever, small-pox, measles, etc. But even in these cases there are generally good grounds for believing that the primary source of the disease must be placed in the pharynx. An inflammation of the labyrinth is probably never primary; and yet there are German authorities who maintain that there is such a disease as a primary inflammation of the labyrinth.

2. *The Extent to which the Inflammation may involve the Outer, Middle or Internal Ear.*—In the external auditory canal an inflammation may involve the entire canal in all its parts, or it may be confined to one-half of the canal only—either the outer or the inner half,—or it may occupy even a more limited area. When the middle ear becomes inflamed the prevailing tendency is probably toward a diffuse, more or less evenly distributed type of inflammation; but extraordinary exceptions to this rule are now and then encountered. Thus, for example, an inflammation may light up in the middle ear and spend its chief force in some limited portion of this system of cavities. Localized inflammations of the mastoid antrum and of the upper half of the tympanic cavity proper are no longer great rarities. When first seen these cases often present every appearance of independent localized inflammations, owing either to the fact that the diffuse inflammation of the middle ear, out of which the localized inflammation grew, has by that time so far subsided as to be very insignificant, or else to the assumed fact that there may be such a thing as an independent localized inflammation of the middle ear.

3. *The Extent to which an Inflammation of one of the three Cavi-*

*ties may involve the other two, and perhaps also neighboring Parts.*

—An inflammation of the external auditory canal shows practically no tendency to involve the middle ear. The outer portion of the membrana tympani may participate actively in the inflammation, but then it must be remembered that this is an integral part of the outer canal. Formerly, it was quite common to read of the danger arising from an extension of inflammation from the auditory canal to the brain, through the intervening bone. I doubt whether such a thing ever occurs; certainly not from a *bona fide* primary inflammation of this part of the ear. On the other hand, it is not an unusual occurrence for patients suffering from an inflammation of the external auditory canal to have at the same time, and from the same underlying causes, a subacute catarrhal inflammation of the middle ear. Neither of these, however, can rightly be spoken of as being secondary to, or an extension of, the other. An arthritis of the temporo-maxillary joint is an occasional result of an inflammation of the auditory canal (either primary or secondary). The relations of these two regions are so intimate that one cannot help being surprised that an acute arthritis is so seldom associated with an inflammation of the adjoining meatus. A localized inflammation (abscess) of the cartilaginous portion of the auditory canal sometimes burrows to a considerable distance from its original starting-point. I have known it to give rise in this way to a large collection of pus, which presented every appearance of being a parotid abscess. In a similar manner it may spread backward and present the external appearances of severe mastoid disease, thus rendering it an exceedingly difficult matter to reach a correct diagnosis.

To describe fully the paths along which an inflammation of the middle ear sometimes travels, would fill the space of an ordinary text-book. Countless air-spaces surround it in many directions, and from these blood-vessels, lymphatics and nerves extend, through minute channels in the bone, to the external periosteum of the skull and into the cranial cavity. That part of the jugular vein which lies upon the temporal bone and is called the lateral sinus, is in very close proximity to the middle ear. The same is true of the internal carotid artery. Blood-vessels of the middle ear pierce the annular ligament of the fenestra ovalis and anastomose with the vessels of the vestibular part of the labyrinth; and a similar anastomosis undoubtedly takes place between the vessels of the scala tympani and those of the middle ear through the membrane of the fenestra rotunda. These anatomical facts show how almost unlimited are the possibilities of an extension of a middle-ear inflammation.

In basilar meningitis, whether of the epidemic form or not, it sometimes happens that the inflammation extends from the

cranial cavity, probably by way of the aquæductus vestibuli, into the vestibule and eventually into all parts of the labyrinth. Furthermore, there is every reason to believe that the acute inflammation of the middle ear, which is sometimes observed in these cases, owes its origin to an extension of the inflammation from the labyrinth. In this connection, however, it must be remembered that the inflammation may spread directly from the cranial cavity to the middle ear, as well as by the more round-about course through the labyrinth. Such a direct spreading of the inflammation is favored, in some cases, by a congenital defect in the bony roof of the tympanic cavity; the dura mater, and the tympanic mucous membrane, in these cases, being in direct contact with each other. This defective condition of the tegmen tympani is probably not an uncommon condition in infancy and early childhood; and while it serves to explain how basilar meningitis may readily set up an acute inflammation of the middle ear, it equally well affords a satisfactory reason for the rapid spread—as observed in certain exceptional cases—of an acute inflammation of the latter cavity to the meninges.

In early life the mastoid antrum is often separated from the outside soft parts (periosteum and skin) by a very thin shell of bone, and the bony channels for the emissary veins are doubtless often quite large. As a result of these anatomical conditions, it is not unusual in children to observe a rapid spread of an acute inflammation of the middle ear to the mastoid integuments. In this way large collections of pus sometimes form behind the ear before the drum membrane ruptures or even shows a marked state of tension. The legitimate conclusion from this is, that, in cases of this kind, the route of least resistance for the pus is through the antrum and openings for the emissary veins, and not, as in the case of adults, through the tissues of the membrana tympani. At first thought it would seem as if the Eustachian tube, the drainage channel provided by nature, ought to prove adequate, at least in the majority of cases, to the task of carrying off the secretions resulting from inflammatory action. As a matter of fact this channel rarely suffices, and the tension due to the increasing accumulation of pus generally continues until the drum membrane ruptures. The inadequacy of the Eustachian tube as a drainage channel is due to the fact that its tympanic orifice is not a gaping opening but rather a valve-like slit, apparently closed, in a natural condition of the parts. When, therefore, an inflammation attacks the middle ear the resulting swelling of the mucous membrane practically closes the tympanic orifice of the Eustachian tube; from being a loose-fitting valve it becomes a tight-fitting one, and all drainage through it probably ceases. Later on, in exceptional cases, large quantities of

pus may pass through it into the vault of the pharynx; and in some chronic cases, in which the drainage through a small perforation in the drum membrane is not sufficiently free, the greater part of a foul and irritating discharge may take place habitually through the Eustachian tube. A very striking hypertrophy of the pharyngeal mucous membrane below the mouth of the tube, and confined wholly to the side corresponding with the affected ear, results from this mode of drainage.

Before closing this section I must not fail to mention the fact that the facial nerve occasionally becomes involved, in the course of an inflammation of the middle ear. As a rule, facial paresis or paralysis is observed only in those cases of long-standing inflammation in which caries or necrosis of the bony walls has developed, especially in the vicinity of the fenestra ovalis and the entrance to the antrum. The facial nerve, it will be remembered, enters the meatus auditorius internus along with the auditory nerve, passes in close proximity to one of the whorls of the cochlea, curves round above the fenestra ovalis, and then, making a rather sharp bend, runs in a fairly straight direction downward, between the posterior margin of the oval window and the lower border of the entrance to the antrum, but much nearer to the latter, to emerge finally among the soft parts near the styloid process. For a distance of at least fifteen millimetres, in the middle part of its course through the temporal bone, this nerve is separated by a comparatively thin layer of bone from the mucous membrane of the middle ear. The favorite spot for caries in the tympanic cavity is precisely this neighborhood of the entrance to the antrum, and, consequently, it is not surprising that facial paresis or paralysis should not be a rare symptom in cases of long-standing purulent inflammation of the drum cavity. Now and then, a recognizable degree of facial paresis is observed in the course of an acute inflammation of the tympanum. In these cases one is tempted to assume that the nerve stands in an abnormally close relationship to the tympanic mucous membrane; its surrounding shell of bone being, perhaps, defective at some point, or the presence of anastomosing blood-vessels between the two tissues rendering the extension of inflammation from the tympanum to the nerve easier than usual.

4. *The Characteristic Differences between Inflammations of the Ear.*—Inflammation of the external auditory canal presents only two characteristically different types—the diffuse and the circumscribed variety; and the latter is very apt to be the direct result of the former. The diffuse variety sometimes involves only a limited patch or area of the canal, and is then generally confined to such manifestations as congestion, moderate infiltration of all the layers of the skin, and desquamation of only the outer



or exposed portions. At other times it extends throughout the entire length of the passage, and is then very apt to involve the outer surface of the drum membrane. Under these circumstances there is generally more or less active exudation from the inflamed surface. It may be nothing more than a mere moistening of the parts, but in some cases the exudation may be so active as to present all the appearances of a veritable otorrhœa. The underlying cause is probably, in most cases, a disturbance of the general nutrition—some lack of balance between the processes of assimilation and those of destructive metamorphosis, or a sluggishness on the part of those organs whose function it is to eliminate from the blood all those used-up products which, if allowed to remain in excess in the circulation, will play the part of irritants at various spots in the body. The external auditory canal seems to be one of these ill-favored spots, and the vault of the pharynx is certainly another. For convenience it is customary to call this condition lithæmia, or latent gout. In young and apparently robust children we sometimes see very striking examples of this sort of diffuse inflammation of the external auditory canal, associated generally with a similar condition of the corresponding auricle; and in these cases we can almost always trace the disease directly to an improper diet and to the habit, on the part of the mother, of allowing the child to eat at any and all hours of the day. Here, it is not improbable that the irritated state of the gastro-intestinal mucous membrane may, by reflex processes, excite an inflammation in the comparatively remote ear.

In the inflammations of the middle ear very great differences may be observed. It is particularly in this class of cases that we must make close inquiry into both the direct and the remote causes, if we wish to gain even an approximately satisfactory idea of the character, localization and extent of the inflammation. The least conspicuous, the most insidious, and perhaps, in the main, the most damaging in its effects upon the hearing, of all the different forms of middle-ear inflammation, is that which is technically known as "chronic catarrhal inflammation of the middle ear." Despite all the study of the past thirty years we know exceedingly little about this affection. That it grows out of a catarrhal inflammation of the vault of the pharynx; that it is apt to develop among members of certain families, as if hereditary influences played a certain part; that certain localities and certain types of climate must be counted among the etiological factors; that the lithæmic state is competent to promote its activity; that a disordered state of the stomach, liver, intestines, uterus and possibly other organs may reflexly, or in some other manner not understood, also favor a continuance of the disease; that all the methods of treatment hitherto discovered and em-

ployed can boast of little or no success—are all facts which few, I believe, will venture to dispute. In this ill-defined affection we are almost forced to assume that the important lesions—those which impair the hearing—are of such a nature as to render the transmitting apparatus (the ossicles and the parts about the round and oval windows) more rigid, less mobile than is natural.

In the more acute forms of inflammation, we encounter a number of very palpable differences, some of which are clearly dependent on the nature of the causative agent. Thus, in syphilitic and tubercular inflammations, we see the same peculiarities which characterize these inflammations when they attack mucous membranes in other

parts of the body, *viz.*: a tendency at times to involve only a limited area, and to cause the death of the particular part affected. It is also claimed that scarlet fever, measles, small pox, diphtheria, and, to a less marked degree, typhoid fever, manifest this same tendency. In these diseases, however, so many factors often conspire to aggravate the aural complication that one may be permitted to doubt whether, after all, they are inherently prone to cause necrosis of the soft parts of the middle ear

—in the sense in which we speak of syphilis possessing such a proneness. In those cases of inflammation of the middle ear which owe their origin to a “cold in the head,” to the entrance of some irritating fluid, like salt water, into the drum cavity by way of the Eustachian tube, or to the extension, earward, of a naso-pharyngeal catarrh of lithæmic or gouty origin, the inflammatory process involves the middle ear, so far as we are able to ascertain, diffusely and more or less evenly. Every now and then, however, we encounter a case in which the inflammation shows a very decided tendency to locate itself in one of two localities—either the mastoid antrum or the pocket-like spaces above the membrana tympani. (See Fig. 19.) Why, it will be asked, should an inflammation localize itself in these particular spots? The only plausible answer that I can give is this: These localized inflammations probably owe their origin to some form

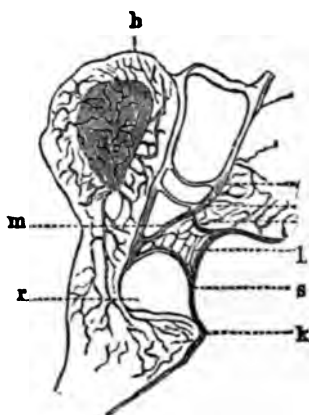


FIG. 19.—Longitudinal Section of the Hammer, showing the system of cavities or pockets lying between the head and neck of that ossicle and the drum membrane. A, head of hammer; k, short process; a, layer of skin toward external auditory canal; r, larger space situated just above the short process; l and m, smaller cavities. (After Politzer.)

of micro-organisms which have found their way into the middle ear along with the in-blown air, and have found conditions favorable to their multiplication and further development only in the two places named above. Both of these places may be termed stagnant places, where currents of air do not penetrate, where the secretions are quiet, and where probably the tissues are not much disturbed by the motions of the ossicles. In some of the cases of this kind which I have seen, I have had a strong suspicion that the air of the house was contaminated with sewer-gas. In any event the patients were in a depreciated condition of health, not referable to any definable disease. I have also observed that these localized inflammations develop much more slowly than do the bona fide acute diffuse inflammations of the middle ear. Here, then, are a series of facts and suspicions which fairly justify some such hypothesis as that which I have put forward.

5. *The Alterations Produced in the Tissues and in the Secretions.*

—In the earlier stages of a simple (non-tubercular, non-syphilitic) inflammation of the external auditory canal or of the middle ear, the alterations consist in different degrees of vascular congestion, with subsequent infiltration of the tissues involved. Hypersecretion soon takes place, and then, in the case of the middle ear, the amount of the fluid secreted may be so great as to fill the cavity tightly. If the tension passes a certain degree pain will be developed, through pressure upon the highly sensitive nerves of the middle ear. If the pressure be sufficiently great, and if the membrana tympani do not rupture sufficiently early to put an end to the continuance of the pressure, necrosis is likely to occur at some spot. This local death may involve only a very small area of the mucous membrane, and the underlying bone may escape. Very often, however, the bone also suffers, and the seeds are sown for a lifelong otorrhœa. Our dispensaries are full of such cases. Of many of them it may be truly said that a timely paracentesis of the drum membrane would have prevented the subsequent chronic disease, by relieving the pressure and so sparing the life of the tissues. Under certain circumstances the external auditory canal may, in the course of an acute inflammation, become a closed cavity, and, being subjected to the same condition of long-continued pressure, its soft parts may die at one or more points. The underlying bone may or may not participate in the necrosis, in precisely the same manner as happens in the middle ear. This course of events is observed only in cases of inflammation of the outer canal developing out of a primary otitis media; at all events, I have never observed anything of the kind in the course of a primary otitis externa. In many of the cases in which caries is discovered in the external

auditory canal we must doubtless explain the lesion in quite a different manner. The prolonged pressure within the middle ear, in a severe inflammation of that cavity, produces a caries which extends outward toward the external auditory canal. Eventually a sinus is formed in the substance of the bone, and drainage takes place through this instead of through a perforation in the drum membrane. The favorite spots for these sinuses are in the belt of bone stretching from Shrapnell's membrane, backward and outward to a point corresponding to the outermost limit of the floor of the mastoid antrum.

The discharge which takes place from an inflamed ear may vary greatly in consistency, color, and odor. These different qualities bear some relation to the different pathological conditions of the parts; but, unfortunately, the relation is not of so fixed and constant a character that we can safely draw conclusions from them in regard to the nature of the lesions. A thin watery discharge, of slightly pinkish hue and without odor, is generally observed in cases of acute inflammation of the middle ear, soon after a perforation has developed in the drum membrane. In a short time, however, the discharge grows thicker and assumes a yellowish hue. From this state, in favorable cases, it either simply becomes less abundant before it finally ceases altogether, or else it first passes through an intermediate stage in which the secretion presents all the physical characteristics of ropy nasal mucus. Even in such recent cases the discharge may be characterized by a very unpleasant odor, suggesting the thought of a possible caries of the bone. The odor, however, is simply an indication that the canal has not been cleansed with sufficient thoroughness or frequency. A creamy and very abundant discharge, in cases which commenced several weeks previously, and which were unusually severe in their earlier stages, is very apt to indicate that the disease is not confined chiefly—as is the case in most instances of simple purulent otitis media—to the tympanic cavity proper, but probably involves to an equal degree the associated system of mastoid cells. In chronic cases, the presence of a brownish or bluish-colored discharge, having a decidedly bad odor, is generally believed to indicate the existence of a carious bone process. The occasional appearance of blood in the discharge, in chronic cases, almost invariably indicates the presence of a polypoid mass, or at least of granulation tissue, in some part of the inflamed ear.



## CHAPTER III.

### DISEASES OF THE AURICLE.

**ECZEMA.**—Among the children of the poorer classes eczema of the auricle is an extremely frequent disease. If less frequent among the children of the well-to-do classes, it is certainly by no means a rare affection even among them. Again, in old age and in the middle period of life, it is quite a common disease. In a certain portion of the cases it develops on other portions of the skin at the same time, *e.g.*, on the hairy scalp or in the mastoid region. In children it is often associated with a conjunctivitis, and the coexistence of the two diseases suggests the

probability that the irritating secretions of the auricle have been transferred by the child's fingers to the eyes.

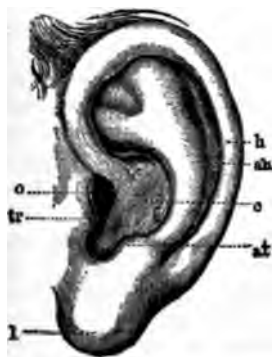

FIG. 20.—Auricle. *ah*, antihelix; *af*, antitragus; *c*, concha (fossa conchae); *h*, helix; *l*, lobule; *o*, orifice of external auditory canal; *tr*, tragus. (After Politzer.)

In its mildest and simplest form, eczema of the auricle manifests itself as a reddening and infiltration of the skin at one or more points. The favorite places are those spots where the skin is folded upon itself, as the fossa heliciis, and the angle behind the ear, where the skin is reflected from the auricle upon the mastoid process. The disease is observed at least equally often at the orifice of the external auditory canal, and extending from there forward over the tragus, and downward over the lobule—in other words, at points where there is apt to be a good deal of friction, or where an irritating discharge from the meatus may act as an exciting cause. At a later stage these reddened and infiltrated spots secrete a fluid which soon becomes inspissated, forming crusts or scabs. In many cases actual ulceration takes place beneath the scabs; and this is particularly apt to occur in the incisura intertragica, in the fossa heliciis (see Fig. 20), and in the angle behind the ear. In exceptional cases the entire auricle and immediate surroundings present an almost continuous mass of scabs.

In another group of cases, a desquamative process, confined to

certain portions of the auricle, seems to constitute the most characteristic, if not the only, manifestation of the disease. The intervening portions of the skin appear to be perfectly healthy, and even those parts which are desquamating or are covered with scab-like formations, often present a pale and uninfamed appearance. The term chronic eczema is usually applied to this class of cases, but it may be applied with equal justice to almost all cases of eczema of the ear in adults.

The prognosis of the disease is good. In the majority of cases we may confidently expect to restore the auricle to an apparently natural condition in a short time. In children, particularly, we may look for a very prompt clearing up of the affected skin, and the cure is likely to prove permanent. In persons past middle life it is well to give a more guarded prognosis; for although we may succeed in promptly restoring the part to a seemingly healthy condition, a relapse is almost sure to come, and that, too, at an early day. The gouty or lithæmic state is the real disease in these cases, and not this limited area of inflammation of the ear. Hence the temporary character of the effects produced by local treatment. When a well-marked gouty attack involves the fingers or toes, a spontaneous and, sometimes very striking subsidence of the eczema of the ear is observed. A vigorous purge will also at times produce the same beneficial effects. Every now and then in the course of a chronic eczema, the auricle passes through an attack of what appears to the observer to be erysipelas. The organ becomes uniformly red, swells up to two or three times its natural size, pits on pressure, and is painful to the touch. Gradually, the redness and swelling disappear, and the auricle, in the course of four or five days, returns to its former state. Whether these attacks, which recur repeatedly in certain cases—some times as often as twice in the course of a month—are really erysipelalous in character or simply represent a diffuse acute exacerbation of the eczema, I am unable to say. As the inflammation does not extend beyond the auricle and external auditory canal, it would seem more proper to look upon it as non-erysipelalous in character.

*Treatment.*—Careful inquiry should be made, first into the character of the patient's diet, and then into that of his habits with regard to bathing and outdoor exercise. In children a complete and permanent cure may often be attained by simply regulating the diet to such simple articles as milk, oatmeal, hominy, fresh meat and vegetables, and light bread. Pastry, pies, cakes, salt meat and pork, tea and coffee must be rigidly excluded. In adults, it will generally be found easier to induce the patient to take an adequate amount of exercise in the open air, than to persuade him into excluding certain articles of food from his daily fare. If possible, he should be induced to do both.

Local applications form a very important part of the treatment of eczema of the auricle. In the acute stage, if there happen to be pain and tenderness, it may be desirable (though only in adults) to apply leeches (or, better still, Bacon's artificial leech,) for the purpose of allaying the pain and diminishing the inflammation. It is rare, that local blood-letting seems however, indicated in these acute cases. If it be resorted to, the region immediately in front of the tragus and that directly behind the auricle, are the spots which should be selected. Cloths dipped in some cooling and astringent lotion, such as the lead and opium wash, or in simple water to which alcohol or *eau de cologne* may be added in varying proportions, will generally be found sufficient to allay all the acute symptoms. Afterward, if no crusts have formed in the meantime, we may apply some oleaginous preparation directly to the affected skin. If crusts have already formed, these must first be removed with a sponge dipped in hot water; and if the skin is actually ulcerated, I am in the habit of cauterizing such ulcers lightly with nitrate of silver in the form of a bead fused upon the end of a probe or a steel cotton carrier.

Cleansing the inflamed parts constitutes an important feature in the treatment of eczema of the auricle. About twice a day a lather of Castile soap should be applied with a camel's hair brush. Then this should be washed off gently with tepid water; and finally, after the skin has been cautiously dried—the minimum amount of friction being used,—some suitable oleaginous preparation should be thoroughly applied.

The chief value of the different oleaginous preparations lies, I imagine, in their power to exclude the air from the parts affected rather than in the medicinal virtues of the drugs which enter into the composition. There can be very little doubt, however, that some of these drugs do exert a decided curative influence. This, I believe, is true more particularly of the oil of Cade and of certain preparations of lead. I formerly used the oil of Cade in the form of an alcoholic solution (one or two drachms of the oil to seven or six drachms of alcohol), and obtained fair results from its use. Not infrequently, however, I found that the inflammation was aggravated by these strong preparations. Of late I have substituted vaseline and vaseline oil for the alcohol, and am well satisfied with the results which I now obtain with this combination. Very weak preparations (two drops of oil of Cade to one drachm of vaseline or vaseline oil) seem to accomplish the desired effects. The patient is advised to apply the remedy twice a day, at night just before retiring, and again the next morning. At night it may be applied very freely, as some kind of cap can be worn for the purpose of protecting the pillow. In the morning,

if the patient is obliged to leave the house, the preparation should be applied so lightly that the ordinary observer will not be able to discover its presence.

Of the lead preparations, I have used only one, *viz.*, Hebra's diachylon ointment. The formula for this ointment, as prepared in Vienna, is (according to Gruber)<sup>1</sup> the following :

- B Olei olivarium optimi..... ℥ xv.  
 Lithargiri..... ℥ iij. et ʒ vj.  
 Coq. l. a. in unguentum molle, dein  
 adde ʒ ij. olei lavand.  
 M. Ft. unguentum.

Unfortunately, it is not always easy to procure this ointment even in a large city like New York, and for this reason I have not prescribed it as freely as I have the oil of Cade preparation. In one or two instances I have known it to prove successful when all the other well-known remedies had failed.

The benzoated oxide of zinc ointment is a favorite remedy with many physicians. I have used it a great deal in children, and have been in the main well satisfied with the results. Vaseline alone or vaseline oil, in mild cases, seems to accomplish nearly as good results as are obtained by the employment of the other remedies mentioned.

Finally, in a certain proportion of the thoroughly chronic cases, in which all the ordinary preparations seem to have been powerless to effect even an amelioration of the unsightly condition of the ear, decided good may be accomplished by painting the diseased parts thoroughly (after all oily substances have been removed), from time to time, with acetum cantharidis.

It is a common mistake to stop using the local applications as soon as the ear appears to have regained its natural condition. It will be found safer to continue the treatment faithfully for at least a week or ten days after a cure has apparently been effected.

*Simple Diffuse Inflammation* of the entire auricle is observed in its purest type in cases in which hot poultices have been used to excess. After the auricle has been exposed for a certain length of time to the combined effects of the heat and the moisture, it becomes highly congested and slightly tender to the touch. The appearance of the organ is precisely the same as if it were affected with acute erysipelas. If the exposure is kept up for a still greater length of time, the auricle becomes quite painful and very much swollen. Abscesses, I am told, may even form at different points. As already stated in the preceding section, such a general inflammation of the auricle may develop in the course of an eczema,

<sup>1</sup> Ueber Eczem am kusseren Ohrtheile. Monatsch f. Ohrenheilk. Nov., 1887.



and I have occasionally seen it in connection with a circumscribed inflammation of the outer portion of the external auditory canal. In these cases, however, it was not quite clear whether the diffuse inflammation of the auricle was to be interpreted as an actual extension of the more localized process in the meatus, or as the result of the application of hot poultices. Cooling applications and the removal of the exciting cause suffice to relieve the inflammation.

*Hæmatoma Auris; Perichondritis. (Othæmatoma; Chondromalacia; Chondromalacosis.)*—These conditions are so closely allied to each other that it is better, I believe, to consider them together in one section. The term hæmatoma auris, or othæmatoma, is usually applied to a peculiar swelling of the auricle, which is most frequently observed in the insane, and which is chiefly due to the escape of a varying quantity of blood either between the cartilage and the perichondrium, or into the substance of the cartilage. The term perichondritis is restricted to those cases in which the symptoms of redness, pain (usually slight), and slowly increasing swelling, point very decidedly to processes that are chiefly inflammatory in their nature. With othæmatoma of the insane I have had no practical experience whatever, and must base my remarks wholly upon information gained through reading; with perichondritis I have also had very little experience, as the disease is comparatively rare. I am persuaded, however, that no sharp dividing line can be drawn between the two classes of cases, whether considered from an etiological, a pathological, or a therapeutical standpoint.

Exposure to severe cold or extreme heat produces an inflammation to which the term perichondritis may fairly be applied. Violence may also produce the same pathological manifestations. Finally, in a few cases, no exciting cause can be discovered; the disease is then said to be idiopathic. In these cases the patients are generally found to be in a poor state of nutrition, and, in the absence of any other adequate cause, we are almost compelled to assume that some local nutritive disturbances—probably of the same nature as those which are now generally admitted to be the chief factors in the production of the typical othæmatoma—have given rise to the perichondritis.

The pathology of othæmatoma proper has for many years past been a fruitful subject for discussion. Some advocate the doctrine that this lesion is peculiar to the insane, and depends upon a pathological condition of the brain. This is the view taken by the late Dr. Hun,<sup>1</sup> of Albany, who has written a very interesting paper on the subject of hæmatoma auris. Others maintain that the lesion is always produced by violence, and that it occurs more

<sup>1</sup> American Journal of Insanity, July, 1870.

frequently among the insane, simply because they are peculiarly liable to violence. Finally, a third party maintains that the othæmatoma is not one of the pathological lesions of insanity, but that the surroundings of the insane, and the debilitated condition which so generally accompanies insanity, are the real reasons for its so frequent occurrence among that class of individuals. This is the view taken by Virchow in his treatise on tumors, and the exhaustive researches of Ludwig Meyer,<sup>1</sup> Pareidt,<sup>2</sup> Guden,<sup>3</sup> Pollak, and Haupt,<sup>4</sup> confirm it in the strongest possible manner. The essential facts developed by these investigations are the following :

First, degenerative changes are quite uniformly found in the cartilaginous framework of the auricle in cases of othæmatoma of the insane. These changes are of such a nature that Pareidt very properly termed the disease a *chondromalacia*,<sup>4</sup> or softening of the cartilage. The progress of the affection is described by Ludwig Meyer essentially as follows : Hæmatoma auris begins as a degeneration and softening of the cartilage at one or more spots. A gelatinous material takes the place of the hard cartilage. As the degenerative process goes on, newly formed blood-vessels shoot out from the perichondrium, or from the vessels that pierce the cartilage at different points, into these softened spots. The newly formed capillary vessels are quite large, and their walls are very thin and richly supplied with nuclei. Thus we have two different processes going on side by side at the same time—a softening of the cartilage, and a granulation process on the part of the perichondrium.

In the second place, a careful macroscopical and microscopical examination of a large number of ears, taken from patients who had died from all sorts of diseases in the hospitals, but who had never manifested any symptoms of insanity, reveals the fact that precisely the same changes as those just described take place in the auricles of the mentally sane. According to the statement of Pollak, whose researches are among the most recent, small nodules, varying in size from a mustard-seed to a lentil, are occasionally found in the cartilaginous portion of the external meatus, and especially in the anthelix. In these, when cut open,

<sup>1</sup> Virchow's Archiv. f. path. Anat., etc. Bd. XXXIII, Heft 4, 1865.

<sup>2</sup> De Chondromalacia, etc. Dissertatio Inauguralis. Halle, 1864.

<sup>3</sup> Ueber den Mikroskopischen Befund in traumatisch gesprengten Ohrknorpel. Virchow's Archiv. f. path. Anat. Bd. LI, 4, p. 157 ; LII, 2, p. 308.

<sup>4</sup> Monatschrift für Ohrenheilkunde. Berlin, July, 1879. (Reviewed in Vol. I. No. 4 of the American Journal of Otology).

<sup>5</sup> Gustav Haupt: Ueber das Othæmatom. Dissert. Inaugur. Würzburg, 1867. Reviewed in A. J. O. vol. iv., p. 143. (Marked changes found in the cartilage of the apparently healthy ear of an insane person whose other ear had been the seat of a well-marked othæmatoma.)

<sup>6</sup> Loosely used in the sense of chondromalacia, which means a softening of the cartilage. According to Kraus (Kritisch-etymologisches medicinisches Lexicon. Göttingen, 1844), the term chondromalacia means simply a softness of the cartilage

it is easy to detect, even with the naked eye, a departure from the normal condition of the reticular cartilage; in some cases, in fact, it will be found that a distinct cavity has already formed. Microscopic examination also reveals spots where the cartilage has broken down into a mass of granules, and others where evidences of new growth of tissue are distinctly recognizable.

In the third place, the number of instances of the occurrence of fully developed othæmatoma in persons who are perfectly free from any mental disorder whatever, is constantly increasing.

These facts justify the belief that insane persons are more liable to the disease under consideration, simply because malnutrition reaches a higher grade among them (taken as a class) than among the mentally sound. The new growth of unusually large and thin-walled capillary blood-vessels also furnishes an explanation

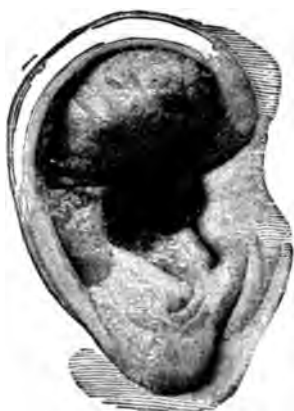

FIG. 21.—Hæmatoma of Upper Part of Auricle. (Sexton.)  $\frac{1}{2}$  natural size.)

of one of the most striking phenomena of othæmatoma, *viz.*, the escape of a comparatively large amount of blood, either between the perichondrium and the cartilage, or into the substance of the cartilage. It can readily be understood how a very trifling exciting cause, such as a slight blow, the pressure of a hard pillow, or even the reflex congestion following some mental emotion, may lead to the rupture of one or more of these delicate vessels and produce the characteristic accumulation of blood.

*External Appearances.*—In a case of well-advanced perichondritis the alterations produced in the external appearance of the auricle are very striking. Where the skin is not stretched by an abundant exudation of fluid between it and the cartilaginous framework, the surface will be uneven—broken up into furrows and doughy looking hummocks, as shown in Fig. 22. Sometimes this uneven surface persists even after the skin has been distended by fluid exudation (See Fig. 21.) The color varies. Generally the skin is livid red or at times even a dark purple.

*Course of the Disease in the Mentally Sane.*—It rarely happens that the physician has an opportunity of seeing a case of idiopathic perichondritis in its incipient stage. The patient generally waits until the discomfort or pain is sufficiently great to make him feel the need of medical aid, and usually by that time the disease has reached its highest stage of development. The

following case is a good example of an idiopathic perichondritis of a comparatively mild type.

Female, thirty years of age, saleswoman in a retail shop, and in decidedly poor general condition. She presented herself at the N. Y. Eye and Ear Infirmary, on the 1st of November, 1878, and gave the following history: About ten days ago she first noticed some irritation at the upper part of the right auricle, not far from the helix. She had not received any injury at this point, nor could she think of any other cause for the development of the soreness in that particular place. In the course of a few days, a circumscribed swelling developed at this spot, and she then consulted her family physician. He made two small incisions into the swelling, one at the upper, the other at the lower limit of the tumor, evacuated the fluid contents, and then passed a seton into one opening and out through the other.

After this, the auricle swelled up rapidly and became very painful. At the time of her visit to the Infirmary, the tumor was fully as large as a butternut. It presented a smooth, red, and inflamed appearance, and occupied the anterior aspect of the upper two-thirds of the auricle. There was also some œdema of the skin above and behind the ear. The seton was still in place, and on removing it a thin fluid spurted out from one of the openings. By aid of the probe it was ascertained that a large cavity existed, the posterior wall of which seemed to be formed by the denuded anterior surface of the cartilage. The two openings were converted into one by an incision, the cavity was carefully cleansed, and a tent was introduced to prevent the edges of the wound from uniting.

When the contents of the cavity were evacuated, it was observed that the larger part consisted of thick, almost gelatinous pus, while the smaller part was apparently a thin serum. The patient was ordered to take twenty drops of the muriated tincture of iron three times a day, and to lay cloths wet with the lead and opium wash upon the inflamed auricle.

On the second day of November she visited my office, and reported that the pain had very markedly abated. I removed the tent and, in so doing, afforded escape to a moderate amount of thick pus and some thin, serous fluid. The parts surrounding the cavity were found to be still very much swollen. From the uniform smoothness of the posterior wall of the cavity it was inferred that no destruction of cartilage had taken place, and that the disease was, strictly speaking, a perichondritis, with effusion

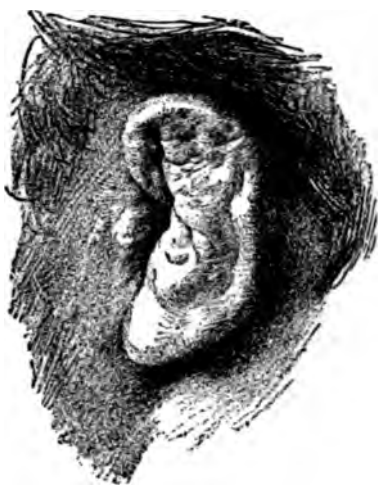

FIG. 22.—General Perichondritis of the Auricle, with areas of destructive chondromalacosis, resulting in marked diminution in size of the entire organ. (After Benni, in *Comptes Rendus du Troisième Congrès International d'Otologie*; Bâle, 1885.)

between the cartilage and the perichondrium. From this time forward the patient was visited regularly by my colleague, Dr. George B. Hickok. The cavity was daily cleansed, and then mopped out with tincture of iodine; afterward, moderate pressure was applied, for the purpose of keeping the walls of the cavity in close apposition.<sup>1</sup> In less than three weeks the cavity had completely healed, and the auricle had so nearly returned to its natural condition that there could no longer be any reasonable doubt about the speedy disappearance of all traces of the disease.

Chimani<sup>2</sup> reports an equally typical case of idiopathic perichondritis, which occurred in a young man, twenty-three years of age. The swelling was incised, and complete recovery took place in a little more than four weeks, without any deformity. Wendt<sup>3</sup> reports a similar instance of the development of a "spontaneous hematoma" in a strong and perfectly healthy young man, twenty years of age. Brunner<sup>4</sup> also reports a similar occurrence in a perfectly healthy individual, twenty-two years of age. In this case, however, it is quite probable that the cartilage was primarily diseased, as a certain degree of deformity remained after the parts had healed. Furthermore, the patient had already a few years previously experienced a similar inflammation of the other auricle, and an examination revealed the fact that some deformity still remained at the seat of this former attack.

In a second case which came under my observation, almost precisely the same conditions were presented as in the case which I first described. The same plan of treatment was followed, and very nearly all traces of the disease disappeared. The two cases, however, differed from each other in the following particulars: a frost-bite was clearly the exciting cause in the latter instance; and, furthermore, the contents of the sac were sufficiently bloody to communicate a bluish tint to the outside of the tumor. As no notes were kept of this case, I cannot say positively whether the fluid contents of the sac were simply stained with the coloring matter of the blood, or whether solid clots were also found to be present.

Dr. Charles J. Kipp, of Newark, N. J., has reported<sup>5</sup> a somewhat similar case of perichondritis—or spurious othæmatoma, as he terms it—of both auricles, the result of a burn.

"The auricles were pushed out from the head, and the upper two-thirds of both were pear-shaped. The swelling was greatest at the top, and measured about an inch and a quarter from before backward. The auricles were hot and very sensitive to the touch. The surfaces of the swellings were

<sup>1</sup>Two short and flat bits of wood were employed for this purpose; one being placed behind, the other in front of the swelling, and rubber bands being used to exert the requisite pressure. The localization of the pressure was secured by interposing suitable pads of sheet lint between the skin and the bits of wood.

<sup>2</sup>Archiv für Ohrenheilkunde, Bd. II, S. 169.

<sup>3</sup>Ibidem, Bd. III, S. 29.

<sup>4</sup>Ibidem, Bd. V., S. 26.

<sup>5</sup>Transactions of the American Otological Society for the year 1873.

convex and smooth, and the skin of normal color, but it looked as if it had been blistered. Fluctuation could be distinctly felt in both. An incision through the entire length of each swelling gave escape to a considerable quantity of a yellowish, glairy fluid. The swellings did not collapse after the evacuation of their contents. In each was found a cavity of about the size of a hickory-nut, lined by a smooth, shining membrane. The anterior wall of each was about a line thick, and was apparently composed of thickened perichondrium; the posterior wall was formed by the cartilage. Under the daily application of tincture of iodine to the interior and exterior of the swellings, the auricles gradually diminished in thickness, and at the end of two months they had regained their normal size and shape. The only deformity remaining when I last saw him was a wrinkled condition of the fossa helix.

Finally, in a third case which came under my observation, the conditions found were essentially different from those observed in the two preceding cases.

The patient, a man thirty years of age, and in robust health, consulted me on the 11th of December, 1878. He stated that four years previously both of his ears had been frost-bitten, and that from that time to the present he had had four sores on the left ear and two on the right, as the results of the acute inflammation which immediately followed the freezing of the parts. All efforts to make these ulcers heal permanently had failed, although during the summer season some of them would present all the appearances of having spontaneously healed. As soon as cold weather returned, however, these spots again became scabbed over. Upon examination, I found four spots on the left auricle and two on the right, occupied by scabs of moderate thickness. They were nearly circular in shape, and measured from five to eight millimetres in diameter. Five out of the six scabs were located on the outer aspect of the helix, above the level of the orifice of the external auditory canal; the sixth was located on the anthelix, on the same level with the external orifice. The edges of the scabs seemed to rest upon healthy skin. After they had been removed, it was ascertained that they each covered an ulcer with sharply defined and undermined edges. The bottom of each ulcer was smooth, hard, and of a pale color. The undermined edges had a markedly bluish hue, which faded gradually into that of the perfectly sound skin.

Nitrate of silver, tincture of iodine, and pure nitric acid were tried in succession, at brief intervals, but none of these reagents seemed to induce the slightest evidence of a healthy reparative process. I then tried the following plan: with a pair of curved and slender-pointed scissors I cut away the bluish undermined edges; then, as soon as the bleeding had ceased, I applied compound tincture of iodine freely to the base of the ulcer, and to the surrounding raw surface. A very thin layer of cotton-wool was next laid upon the exposed surface, and then liquid collodion was applied for the purpose of supplying an artificial scab. At the end of three or four days the collodion and cotton were removed and the ulcer was found to be healing slowly both from the edges and from the bottom. The compound tincture was applied a second time and the wound was sealed up again with cotton and collodion. Nine such applications in all were made

during the latter part of December, and on the second day of January I found the newly formed skin firm and dry over the spot which before had been the seat of the ulcer. The depression of the surface at this point was too slight to attract attention.

The remaining ulcers were treated in much the same manner as the first one, and with equally good results.

In the cases described above it is reasonably safe to assume that the cartilage itself was either not at all involved, or at most, only very superficially. The term *perichondritis* seems therefore more appropriate for this class of cases than either of the other expressions—*othæmatoma* and *hæmatoma auris*. It would be better if we could abandon the use of these two terms altogether and employ some term which indicated the essential nature of the disease, and not merely one of its comparatively unimportant manifestations—the escape of blood into the tissues. Pareidt's *chondromalacia* (or the correct expression, *chondromalacosis*) is certainly the best term that has thus far been proposed. I hesitate, though, to urge the abandonment of terms to which we have all been habituated for so long a time.

I have already said that this *chondromalacosis* is occasionally observed among the mentally sane. Through the courtesy of Dr. Oren D. Pomeroy, of this city, I once had the opportunity of seeing a very marked instance of this disease.<sup>1</sup>

The patient, a cooper, forty-two years of age, and of perfectly sound mind, gave the following history: In the early part of May, 1874, he experienced a violent pain in the right ear, which continued for eleven days, with very little abatement. A discharge of thick creamy pus then made its appearance in the external auditory canal. Five days after the discharge began, he presented himself at the Brooklyn Eye and Ear Hospital. Owing to the swollen condition of the canal it was not found possible at that time to determine satisfactorily whether the disease had commenced in that region or in the middle ear. In the course of a few days the swelling extended outward from the canal, and involved the auricle, causing it to become very much thickened. An incision made in the swelling gave exit only to a thin, serous fluid. An opening in front of the meatus and just below the tragus afterward formed, from which the discharge was more purulent in character. On the 1st of September, when Dr. Pomeroy first saw the patient, a large abscess occupied the region of the fossa conchæ, and extended upward, downward, and backward, involving at least half the area of the auricle. In front of the meatus, near the tragus, was a circumscribed swelling, with a fistulous opening in its apex. The large tumor was somewhat nodulated, but fluctuation was easily recognized throughout, both in front and behind. An incision was made posteriorly, where the wall of the abscess was very thin, and about five drachms of pus were evacuated. On exploration with the finger, it was found that the cavity of the abscess was bounded, both in front and behind, by integument

<sup>1</sup> This case is reported in detail in the Transactions of the American Otological Society for the year 1875.

and connective tissue only, the cartilage having entirely disappeared from the region involved. At subsequent times small abscesses made their appearance in other localities, viz.: in the region of the lobule, three; in the tragus, one; in the upper portion of the helix, two. The larger cavity closed in three weeks without special treatment, beyond a thorough daily cleansing with tepid water. The discharge from the abscess in the helix was somewhat glairy in character. Early in November the last abscess healed, and the auricle then presented the deformed appearance shown in the cut accompanying the published report of the case.

This case, when studied in the light of Meyer's and Pollak's investigations, adds strength, it seems to me, to the theory that othæmatomata owe their origin primarily to a softening of the cartilage in spots. An intercurrent acute inflammation of the skin, or of the perichondrium at some one spot, may be required to fan these smouldering fires into a rapidly destructive conflagration, such as that observed in the present instance; but, without the predisposition supplied by the existence of several centres of softening in different parts of the cartilage, it is difficult to understand how an inflammation, beginning in the middle ear or external auditory canal, and extending to the auricle, should result in such serious damage to the cartilaginous framework.

Wendt,<sup>1</sup> under the heading, "A Case of Subacute Inflammation of the Cellular Tissue of the Auricle," describes a case which corresponds in all essential particulars with the one just narrated. With this exception, I can find no other case on record in which the extent of the destruction of the cartilage and the degree of the deformity resulting therefrom were so great as in Dr. Pomeroy's case.

The case reported by Dr. Roosa, under the title of "Deformity of the Auricle, resulting from Inflammation of the External Auditory Canal," seems to me to belong properly to this category.<sup>2</sup> The subject is one of such importance that I make no apology for giving somewhat in detail the history of this case.

The patient, a female, forty years of age, consulted Dr. J. Orne Green, of Boston, on the 13th of November, 1871. She was then suffering from a diffuse inflammation of the meatus, of one week's standing. "The swelling was greatest about the middle of the meatus, closing the passage there. There was not much swelling externally. During that week she had a furuncle on one eyelid, and when seen was suffering from inflammation of one ala of the nose." As the application of poultices failed to reduce the swelling, Dr. Green made an incision nearly the whole length of the meatus. This evacuated a little pus and relieved the pain. Three or four days later the ear began to swell again, and all the old symptoms returned. Another thorough incision was made, evacuating a little pus and causing slight relief. On the 22d of De-

<sup>1</sup> Archiv. für Ohrenheilkunde, Bd. III., S. 30.

<sup>2</sup> Transactions of the American Otological Society, 1873, p. 123 (with an excellent woodcut of the deformed auricle).



ember—that is, several days after the last incision had been made—she came under Dr. Roosa's care. The auricle, which had in the meantime been poulticed a great deal, presented a somewhat reddened appearance. The whole meatus was occluded by a fungous growth springing from the middle of the anterior wall of the auditory canal. Dr. Roosa removed this by a snare, applied nitric acid to the base, and ordered the warm douche to be continued. The patient's general condition was not good. Tonics were continued. As the fungous growth still persisted in sprouting after its removal, Dr. R. found it necessary to remove portions of it from time to time. Toward the end of January the whole auricle became very red, swollen, and tender. Fluctuation could be felt in different parts, and especially in the concha. Incisions were made at different times into these fluctuating swellings. A bloody serum was evacuated, but no pus. "On February 12th the canal had thoroughly healed, but the auricle was still swelled, red, painful, and tender, and the natural features of the part, except the helix, were removed by this swelling, so that the ear was considerably deformed. The meatus was but a minute opening, but when the walls were drawn apart the hearing was found to be unimpaired. The membrana tympani was never affected during the whole course of the trouble." The patient returned to Boston at this time, and was under the care of Dr. Henry L. Shaw. The swelling of the auricle increased, and at different times incisions were made, and pus was evacuated. All active inflammatory symptoms did not cease until during the following April or May.

Dr. Lucien Howe, of Buffalo, some years ago reported a case, which may possibly belong in this same category.<sup>1</sup> The degree of deformity observed in this case, and caused, as Dr. Howe believes, by a chronic purulent inflammation of the middle ear, is so slight that, when examined by itself, the auricle presents simply a somewhat peculiar appearance. When, however, it is compared with the auricle of the opposite side, where the middle ear shows no evidences of ever having been the seat of a chronic purulent inflammation, the deformity is seen to be quite marked. In the first place, the auricle, as a whole, is considerably smaller than its fellow; and, in the next place, the fossa conchæ is noticeably contracted and also more or less distorted in its outlines. It is a very common experience, in cases of chronic purulent inflammation of the middle ear, to find the external auditory canal greatly diminished in size from protracted inflammation of its walls, but I cannot recall a single case in which the auricle had become, through similar causes, so deformed as to attract my notice. It is quite possible that in cases where pus is discharged for weeks and months continuously over the walls of the cartilaginous meatus, over the posterior aspect of the tragus, into the fossa conchæ, and through the incisura intertragiea, a chronic subacute perichondritis may be kindled and kept up until a considerable

<sup>1</sup> Buffalo Medical and Surgical Journal, Dec., 1879.

amount of cicatricial tissue is produced. As the tendency of this newly formed tissue is to contract powerfully, it is easy to understand how, in course of time, the auricle may become noticeably diminished in size and otherwise twisted out of shape. But how are we to distinguish these cases with certainty from those in which the deformity owes its origin to an attack of chondromalacosis? This latter disease may perfectly well run its course contemporaneously with a chronic otitis media purulenta; in fact it is not unlikely that the irritation produced in the canal and vicinity by the stream of more or less acrid pus which flows over it, may even fan into activity an otherwise latent chondromalacosis. A careful inquiry into the past history of cases like that which Dr. Howe has reported may in time solve some of these questions which now must await a solution until our store of facts shall have become larger.<sup>1</sup>

*Diagnosis.*—Perichondritis of the auricle presents, in its acute stage, such salient features that no physician would be likely to mistake it for any other form of disease. The conditions presented are practically those of an abscess, generally of large size; but the abscess has peculiar anatomical relations, and its contents are usually different from those of an ordinary abscess. Thus, we find, after an incision has been made, that the cartilage forms one wall of the abscess, and the perichondrium the other. We also find that the contents of this abscess are composed, not of thick, healthy pus, such as is usually found in acutely formed abscesses, but of a glairy yellowish fluid, or of a bloody serum, or partly of thick pus, and partly of thin, yellowish serum. From the external appearance alone it is impossible to decide whether the abscess owes its origin to a burn, to a frost-bite, to a blow upon the ear, or to nutritive changes in the cartilage or perichondrium.

If, in addition to the perichondritis, softening processes are going on in the subjacent cartilage, the combined destructive and proliferative changes may give to the auricle such a knobbed and distorted appearance as to suggest the presence of cancer. In Dr. Pomeroy's case I frankly confess that I leaned more toward the diagnosis of epithelioma of the auricle than toward that of a chronic inflammation of the perichondrium. I had under my care a short time previously, a well-marked case of epithelioma of the auricle, and the outward resemblance between that case and the one I have just referred to was so strong that I could not help being struck with it. Besides, I had never before seen a case of

<sup>1</sup>From a very superficial examination of the literature I find that three cases of othematoma, in mentally sound persons, have been reported in addition to those already mentioned, viz., one by Schwartze (Arch. f. Ohrenh., Bd. II., S. 213), in which a blow upon the ear was the exciting cause; and two by Brunner (Op. cit., Bd. V., S. 30), in one of which a frost-bite was the exciting cause.

chondromalacosis, and was not aware that it could produce such extensive destruction of the cartilage in one part of the ear, and such marked hypertrophy of the perichondrium in another. On closer examination, however, an appreciable difference between the two conditions can be made out even with the naked eye. In cancer, for instance, the skin will be found to have lost its suppleness, and to be rough and uneven on its surface; while in chondromalacosis the skin is either smooth or is capable of being made smooth by stretching, and it can readily be shown that the unevenness of surface is due to the unevenness of the subjacent parts rather than to any changes in the skin itself. As a matter of course, a microscopic examination of the suspected tissues would set at rest all doubts about the correctness or incorrectness of the diagnosis.

*Prognosis.*—The prognosis in this class of cases has reference simply to the degree of deformity which is likely to result from the disease. In simple perichondritis the prognosis is good. If the abscess is opened early and freely, very little, if any, deformity will be left after the parts have healed. In chondromalacosis the degree of permanent deformity will depend chiefly upon the extent of cartilage destroyed, and only to a slight degree upon the inflammatory thickening of the perichondrium.

*Treatment.*—Cases of perichondritis or of chondromalacosis of the auricle rarely come into the physician's hands until a distinct cavity, with fluid contents, has formed. The most urgent indication in this stage of the disease is to relieve the tension and prevent further separation of the perichondrium from the cartilage. This can best be accomplished by making an incision into the swelling; not a small one, which will allow only the fluid portions of the contents to escape, but a liberal one, that will afford ample room for the thorough daily cleansing of the cavity. If the cartilage seems to be in a healthy condition, we may begin at once, on the day following the incision, to bring moderate pressure to bear upon the separated cartilage and perichondrium, in the hope of thus hastening their union by adhesion. For this purpose Dr. Hickok's contrivance, described on p. 44, will be found very useful; or two pads may be adjusted, one in front of and the other behind the auricle, and a bandage may then be passed over the top of the head and under the chin, in such a manner as to keep the pads in position and exert moderate pressure upon the walls of the cavity. In addition to the daily cleansing of the cavity with tepid water, and the readjustment of the pads and bandage, it is doubtful whether we can do anything that will materially hasten the process of healing. My own preferences would lead me to mop out the cavity with tincture of iodine after each cleansing, but I cannot say positively that this procedure

materially hastens recovery. Instead of the simple tincture, the compound tincture of iodine may perhaps be used with equal advantage. In cases of chondromalacosis it would probably be better to omit making pressure until we are confident that the processes of softening have come to an end. If new collections of fluid form in other parts of the auricle, these must each be treated separately, in exactly the same manner as the original collection.

Probably in a majority of these cases, it will be found desirable to prescribe quinine, iron, cod-liver oil, and a more liberal diet. It is unnecessary, however, for me to enter any more fully into this aspect of the subject.

*New-Growths.*—*Fibroid tumors* of the auricle are observed quite frequently among negroes, and occasionally among white women, as a result of the operation of piercing the lobule, or of the irritation caused by wearing an ear-ring. Through the kindness of my colleagues I have had the opportunity of examining two or three cases of this form of new-growth, but I have never had a case under my immediate care. The tendency to recur, after apparently complete extirpation with the knife, is perhaps the most interesting feature connected with these growths. In one of the cases referred to above, the extirpated tumor—the second or third return of the growth—was placed in my hands for microscopic examination. To my surprise, the most careful search failed to discover cellular elements in any part of the mass, which was as large as a hickory-nut and slightly lobulated in structure. The growth seemed to be made up entirely of fibrous tissue, which appeared under the microscope in the form of wavy bands.<sup>1</sup>

Next to the fibroma, *epithelioma* is probably the commonest form of new-growth observed in the auricle. The following is the only case of this nature that has come under my observation.

The patient, a coachman, forty-three years of age, and otherwise in excellent health, presented himself at the Infirmary with an auricle which, at first sight, seemed to be affected with eczema. The larger part of the upper half of the auricle presented, on its anterior aspect, an almost continuous mass of scabs. On the posterior surface there was also one moderately large scab. Between these crusts, and surrounding them, the skin presented a bright red and infiltrated appearance, with quite sharply defined limits at the points where it merged into the surrounding healthy skin. After the scabs had been removed, it was found that they covered quite deep ulcers. At one spot, corresponding to the location of the crust on the posterior aspect of the auricle, the cartilage was completely destroyed, and a mop of cotton-wool, at least four

<sup>1</sup> Cases of fibroid tumor of the auricle have been reported by Bertolet (Trans. Amer. Otol. Soc., 1871), Clarence J. Blake (Arch. Ophth. and Otol., Vol. III., No. 1, p. 87), Burnett (Treatise on the Ear), and others. A very interesting case of myxofibroma of the auricle is reported by the late Dr. C. R. Agnew, in the Transactions of the American Otol. Soc. for 1878. In this case the tumor returned four times after the original operation.

millimetres in diameter, could readily be passed through the opening from one side to the other. The orifice of the external auditory canal was not involved. The patient gave the following history of the development of the disease: During the previous winter his right auricle had been frost-bitten, and the affected portion had subsequently remained quite sore. Different plans of treatment had been tried, but the area of soreness had steadily increased despite all treatment. As the neighboring glands were not enlarged, I thought the progress of the disease might be arrested, or at least be retarded, by excising the diseased portions of the auricle. The patient's consent having readily been obtained, he was etherized, and, while he was under the influence of the anæsthetic, a V-shaped piece, including the diseased tissues, was excised by means of a strong pair of scissors. The remaining upper and lower portions of the auricle were then fitted to each other as neatly as possible, and held in coaptation by means of several very fine interrupted sutures. The wound healed promptly, but very soon afterward fresh evidences of the disease manifested themselves along the line of the cicatrix, showing quite clearly that all the diseased tissues had not been excised. In 1877 I heard that the man was still alive, but could learn no particulars with regard to the condition of the affected auricle.

The case reported by Dr. J. Orne Greene, of Boston,<sup>1</sup> resembles in all essential particulars, the one which I have just described.



FIG. 23.—Cornu humanum of the auricle. (About  $\frac{1}{2}$  natural size.)

In his case, however, the disease had made further progress, and complete amputation of the auricle and cartilaginous portion of the meatus was found necessary. Roosa,<sup>2</sup> and Burnett<sup>3</sup> each report a case, and the latter gives full reference to the literature of the subject.

In 1871, at the meeting of the American Otological Society, I reported a case of *cornu humanum*<sup>4</sup> of the auricle (Fig. 23). The details of this case are as follows:

The patient, a man 55 years of age, and in good general condition, stated that nearly two years previously he first noticed a small sharp point on the top of the ear. He picked it constantly with his nails, until it became sore. At the same time he noticed that what he supposed to be a simple scab covering the spot, grew to be quite thick, hard, and prominent. Whenever it reached such a size as to be an object of disfigurement, he was in the habit of paring it down with a razor. During the past two months it had grown, he thought, rather more rapidly than before, and he was therefore anxious to have it removed.

At the time when he visited me the growth presented the following appearance: a blunted, horn-like protuberance, three-fourths of an inch long and nearly as broad at its base, springs from the upper and posterior portion of the left helix. Of a

<sup>1</sup> Transactions of the American Otological Society, 1870.

<sup>2</sup> Treatise on the Diseases of the Ear. New York, 1873.

<sup>3</sup> Treatise on the Ear. Philadelphia, 1877.

<sup>4</sup> See Rindfleisch; Pathologische Gewebelehre, Leipzig, 1866. § 293.

whitish color at its base, it gradually grows quite smoky at its summit, which is more or less jagged in appearance. It is distinctly striated, the markings running in a slightly divergent direction from the summit to the base. At the extremity, and in the middle portion it is hard like horn, but near the base it can easily be compressed, though yet comparatively hard. The line of demarcation between the growth and the normal skin is very abrupt. There is no tenderness on pressure.

The patient having been brought under the influence of ether, I made two converging incisions on either side of the base of the tumor. The tissues included between these incisions comprised every trace of the new growth, and the wedge-shaped wound which remained was obliterated by approximating the opposite edges of skin and keeping them in close apposition by means of fine interrupted sutures. Union took place by granulation, and at the end of the third week scarcely a trace of the operation could be detected. Six months later the patient was seen again. There were no signs of a return of the growth. A small, sharp point, however—similar, he says, to the one first noticed on the ear—could be distinctly felt and seen on the outer surface of the left eyelid.<sup>1</sup>

*Miscellaneous Affections.*—I have never seen a case of *herpes zoster* of the auricle, and must refer the reader, for information upon this topic, to a monograph by Gruber,<sup>2</sup> to a paper by J. Orne Green, on "Neuralgia in and about the Ear,"<sup>3</sup> and to Burnett's "Treatise on the Ear." I have also never seen a case of *lupus* of the auricle. Strawbridge,<sup>4</sup> of Philadelphia, reports one case of the disease, and Neumann,<sup>5</sup> makes the statement that the auricle is the favorite seat of *lupus*.

*Syphilitic gummata* and *syphilitic ulcerations* are occasionally seen on the auricle. The following two cases are the only ones that have come under my personal observation:—

First case. Male, *ætat.* 26. May 27, 1874. Syphilis (primary) four years ago. Sore throat and eruption on face last December. Three weeks ago he began to have some pain in the left ear, without tinnitus or noticeable deafness. During the past week the pain has been more pronounced, and there has been a slight discharge from the outer canal. Tragus and outer portion of meatus red, swollen, and tender, especially superiorly. Deep ulceration of the auricle at the commencement of the helix just above the orifice of the external auditory canal. It measures fully half an inch in diameter, and extends down to the cartilage.

The ulcer was cauterized with the stick of nitrate of silver, and three leeches were applied in front of the tragus. (Patient did not return.)

Second case. Male, *ætat.* 32, in a rather poor physical condition, June 16, 1875. He is now suffering from syphilitic disease

<sup>1</sup> Soon after the manuscript of this chapter had been sent to the printer's I saw a second case, of apparently the same character, in a lad fifteen years of age. The situation of the growth was exactly the same in both cases.

<sup>2</sup> Die Bläschenflechte am Ohre. Monatschrift für Ohrenheilkunde, IX, 5, May 1873.

<sup>3</sup> Transactions of the American Otological Society, 1874.

<sup>4</sup> *Ibid.*, 1878.

<sup>5</sup> Monatschrift für Ohrenh. III., 5, May, 1869.

of the nasal bones or cartilages, the contour of the nose being already disfigured. A large part of the fossa conchæ of the auricle is occupied by a dry scab, from beneath one edge of which a little pus escapes. The removal of this scab brought to view a roundish ulcer about the size of a three-cent piece. The ulcerated surface, which was not depressed below the surrounding surface of healthy skin, seemed to be composed of a soft, succulent tissue, in places apparently papilliform in structure. A single application of a saturated solution of nitrate of silver caused the ulcer to heal entirely in the course of a few days. It should be stated, however, that the patient had been taking iodide of potassium for some time previously.

Chimani reports an interesting case of *cirsoid aneurism* of the auricle, involving the branches of the superior, anterior, inferior, and posterior auricular arteries.<sup>1</sup> A somewhat similar case is reported by Weinlechner.<sup>2</sup> Repeated injections of a solution of the chloride of iron accomplished a complete cure in the former case, but in the latter it was found necessary to ligate the carotid artery.

In both of these cases a dilatation and perhaps lengthening of existing arterial vessels constituted the chief feature of the disease, while in the case of "*angioma cavernosum*" reported by Kipp,<sup>3</sup> an actual new-growth of blood-vessels appears to have taken place. The case of an "erectile tumor" of the auricle, reported by Martin,<sup>4</sup> and referred to by Schwartze,<sup>5</sup> was probably of the same nature as that observed by Kipp. In the treatment of these vascular growths Prof. Politzer recommends the employment of Paquelin's thermocautery. If the tumor be of small size he says that it may be destroyed at a single sitting, but that in the larger growths the cauterization should be confined to a limited area, and that the procedure should then be repeated as often as may be found necessary, at intervals of five or six days. He also advises that, if any comparatively large artery (for example the posterior auricular) be found acting as a feeder to the growth, it should be tied percutaneously. According to the same author, ligature of the carotid should not be resorted to until after the repeated use of the cautery has demonstrated clearly that the tumor cannot be destroyed by its employment. Successful results following ligature of the carotid have been obtained by Dupuytren, Mussey, and Weinlechner.

*Cleft lobule*, due to the wearing of ear-rings, is a comparatively common deformity of the auricle. I have several times seen a double cleft, but have never observed either the single or the double cleft in a patient who considered the deformity sufficiently great to impel her to have it remedied by an operation.

<sup>1</sup> Archiv f. Ohrenheilkunde, Bd. VIII., S. 62.

<sup>2</sup> Monatsschrift f. Ohrenheilkunde, XI., 1877.

<sup>3</sup> Transactions of the American Otological Society, 1875.

<sup>4</sup> Gazette des Hôpitaux, 102, 1857.

<sup>5</sup> Archiv f. Ohrenheilkunde, I., S. 337.

It would seem as if *wounds* and *contusions* of the auricle ought to come under the aural surgeon's observation quite frequently, especially in a large city like New York. As a matter of fact, I have seen but one case of this kind. Furthermore, on looking over one of the annual reports of the New York Eye and Ear Infirmary, that for 1878, I find that out of a total of nearly 2,800 cases of ear disease, there was but one case of lacerated wound of the auricle; from which I infer that traumatic disease of this part of the body is quite rare. In the single case which came under my observation, the patient, a strong healthy woman, had fallen in such a manner as to strike heavily with the side of her head upon the sharp edge of a tin pail, which was standing upon the floor. She was probably intoxicated at the time. After she had risen to her feet, she discovered that the lower part of the ear (the entire lobule and the lower portion of the helix) had been almost severed from the head. When she appeared at the Infirmary, three days after the accident had happened, the lobule was found to be hanging loosely suspended by a small band of flesh. The raw surface had begun to suppurate, but there was very little redness or swelling of the adjacent parts. At the suggestion of my colleague, Dr. J. N. Beekman, the raw surfaces were kept in close apposition by means of a series of delicate supporting loops or bands of frayed lint held fast by a coating of collodion. By this device the edges of the wound were brought together in as perfect a manner as if a series of fine sutures had been used. The extreme posterior end of the wound was left open for drainage purposes. When the patient returned to the Infirmary, exactly one week later, the dressings were found to be still firmly in position, and the parts presented every appearance of having practically united by first intention; at all events, there was no evidence that further suppuration had taken place. To ensure thoroughly firm union, the patient was instructed to wait three or four days more before removing the dressings. As she did not return a third time, it is fair to infer that the cure proved successful.

Triquet<sup>1</sup> mentions two well-authenticated instances of restoration of vitality in a severed portion of the auricle, and Schwabach<sup>2</sup> says that this successful result is often obtained after student-duels, in which a part of the auricle has been cut off by the sword.

Severe *burns* of the auricle present either the picture of a decided perichondritis, or that of a localized death or gangrene; both of which conditions have been discussed sufficiently in a previous paragraph. In the milder cases the pain and soreness

<sup>1</sup> *Traité pratique des maladies de l'oreille.* Paris, 1857.

<sup>2</sup> *Eulenberg, Real-Encyclopædie.* 1882.



may be greatly mitigated by the local application of carbolated oil (3 ij of carbolic acid to ʒ iij of olive oil) or carbolated vaseline. Cooling applications also afford relief.

*Frost Bite.*—The auricle, by reason of its exposed position, is very apt to suffer from the effects of extreme cold. At first the cold produces contraction of the blood-vessels of the skin, but paralysis of their muscular elements soon follows, and the ear then presents a red or even purplish appearance, and is likely to be somewhat swollen. If actual freezing takes place, the ear assumes a whitish appearance, and may even, under the influence of prolonged cold, become brittle. Under favorable circumstances the frozen auricle (usually only its upper portion) may gradually resume its natural condition, though very commonly a certain degree of paresis of the blood-vessels remains, causing permanent redness of the affected part. The best method of thawing out a frozen ear is to rub it with snow at first, and then afterward with cold water. This must be done gently, as there is danger of breaking the frozen organ. When the circulation seems to have been re-established, tepid water may be used instead of cold. These procedures must be carried on either out-of-doors or in a cold room, the aim being to restore the frozen part very gradually to its proper temperature. In unfavorable cases—those, for example, in which the ear has been allowed to remain for too long a time in a frozen condition, or in which no precautions have been taken to secure its gradual restoration to a normal temperature—inflammation sets in, and, according to its severity, we may have as a final result either gangrene and sloughing away of the part affected, or a perichondritis, presenting the picture of a well-marked othæmatoma. The treatment required for the first of these conditions is amputation of the gangrenous portion; that required for the perichondritis has been already set forth on a preceding page.

*Herpes Zoster* of the auricle is a disease of rare occurrence. Instances of it have been reported by J. Orne Greene and C. H. Burnett, in this country, by Anstie in England, and by Anspitz, Gruber, Hermet and others on the continent. The disease is characterized, according to Politzer, by the development of transparent, confluent vesicles in groups, upon an inflamed skin surface. (See Fig. 24.) The favorite locations are the posterior surface of the auricle, the lobule, the region in front of the tragus, and the anterior upper wall of the orifice of the meatus. For several days before the vesicles appear there will be pains shooting through the head and involving the region of the ear. Narcotics, administered internally or by the hypodermatic method, may be found necessary when the pain is unusually severe.

Comparatively few cases of *congenital malformation* of the auricle have come under my personal observation. In one instance (a young infant of the female sex) both ears were deformed, though in a very different degree. The right auricle was perfect in all its parts, but just in front of the tragus, and perhaps continuous with its cartilaginous framework, was a loosely attached, irregular mass, which might perhaps be considered as a supernumerary tragus. It consisted of three distinct lobes, of which the central one was considerably larger than the other two. The external auditory canal was normal. The left auricle was represented by a small, irregularly shaped, flattened mass, which bore no resemblance whatever to a normal auricle. Very nearly in the centre of this mass, externally, there was a small depression, which ended in a cul-de-sac at a depth of three or four millimetres. Beyond the depression, I could feel a short, solid cord, representing undoubtedly the obliterated or imperfectly developed external auditory canal. In all other respects, the child seemed to be perfectly formed and well nourished.

In another case (female child, nearly three years old) the malformations of the auricles were exactly the same on both sides. The lobe was perfectly formed and of full size, but the upper parts of the auricle seemed to be shrivelled up into a small shapeless mass. As in the previous case, a small depression indicated the situation of the rudimentary external auditory canal. With the finger the tympanic ring could readily be outlined; it appeared to be of normal size. The parents were positive that the child heard quite well. I was not able myself to determine satisfactorily what degree of hearing she possessed. Apart from the deformities described above, the child appeared to be perfectly formed.

Finally, in still another case, the deformity consisted in an imperfectly developed cartilaginous framework of the auricle. The child, a twin, four years old, and otherwise well developed, possessed two large, but very thin, auricles. The fossa helix of each ear was obliterated, and the upper part of the auricle drooped, somewhat after the fashion of a dog's ear. The changes

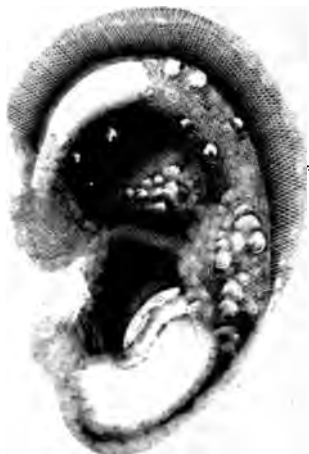

FIG. 24. — Herpes Zoster of the Auricle, in a child nine years old. Case of Dr. Hernet, of Paris. (Copied from Politzer's treatise.)

noted were more marked on the left than on the right side. The impression made upon my mind at the time was that undue pressure *in utero* had flattened both auricles, and had arrested the development of their cartilaginous frameworks.<sup>1</sup>

*Congenital fistula of the ear* is an affection which is quite rare and at the same time very easy to be overlooked. Just in front of the tragus a small scab may be seen, and when it is removed there will be brought to light the orifice of a sinus containing creamy pus. Pressure upon the skin from below upwards, or from above downwards, generally causes an appreciable amount of pus to escape from the opening. The history given by the patient is simply that of a discharging sinus which occasionally heals up for a short time and then breaks open again. Only two cases have come under my observation, and in only one of these did I have the opportunity of examining the parts somewhat carefully. The skin surrounding the orifice was perfectly natural in appearance, and at the time of the examination there was not even a scab covering the minute orifice. There was also no depression of the skin at the point where the orifice existed, and the only way in which I could locate the exact situation of the opening of the sinus was by forcing out pus through pressure. My probe passed directly inward, without encountering any resistance, for a distance of about one-quarter inch. There it encountered firm resistance; but when I elevated the outer end of the instrument so as to bring it into a nearly vertical position, it slipped easily downward (no force being used) a further distance of fully three quarters of an inch. At this point it seemed to reach the natural end of the channel. Cauterization of the sinus had been tried by another physician, but without success. I therefore proposed to the boy's mother that I should convert the channel into an open wound, and in this way endeavor to destroy the secreting surface. My suggestion was not received favorably, and I never saw the patient again. In some cases the situation of the opening of the fistula is indicated by a depression of the skin just in front of the tragus.

---

<sup>1</sup> Dr. C. J. Blake reports an interesting case of congenital malformation of the auricle, in the Archives of Ophthalmology and Otology, vol. iii., No. 1, p. 86. Strawbridge reports a case in the Transactions of the American Otological Society, for 1875, and gives some references to the literature of the subject. Dr. Knapp also reports a case in the Transactions of the American Otological Society for 1870. Further references to the literature of the subject will be found in the treatises of Roosa and Burnett.



## CHAPTER IV.

### DISEASES OF THE EXTERNAL AUDITORY CANAL.

THE affections to which this portion of the ear is liable comprise those which may equally well affect the auricle, those which have extended to it from the middle ear, and others which are peculiar to the canal itself.

The most frequent affection of this part of the ear is that which is known as *impacted cerumen*. In the cartilaginous portion of the external auditory canal, and also, to a very limited extent, in the osseous portion, there are glands which secrete the peculiar substance known as cerumen, or ear-wax. These glands, when examined under the microscope, in thin sections of the meatus, are seen to be similar in all respects to the sweat-glands. The secretion from these glands is a transparent yellowish fluid. It is only after exposure to the air that it gradually becomes inspissated and of a darker color. Under certain conditions the ceruminous glands secrete this yellowish fluid in such abundance that it escapes from the orifice of the external auditory canal in the form of a watery discharge. I have several times been told by patients that they had a discharge from the ear, and, on making an examination, have been surprised to find that what both they and I supposed to be a *bona fide* discharge of pus or seropus, was in reality simply an excessive secretion of fluid cerumen. As a rule, however, the rate of secretion is so slow that the cerumen becomes inspissated very soon after it leaves the mouths of the glands. For the further propulsion of this material out of the canal, Nature seems to have made a very curious provision. It is now an established fact that at least the uppermost layer of the epithelium lining the external auditory canal moves constantly from within outward. Thus, for example, if on a certain day we find a scab resting wholly upon the drum-membrane, five or six days from that time we shall find it resting partly upon the drum-membrane, and partly upon the wall of the osseous canal. At the end of another week it will be found to have travelled outward entirely beyond the limits of the membrana tympani. This same surface movement undoubtedly takes place symmetrically throughout the entire length of the canal, and supplies the force required to extrude all ordinary accumulations of cerumen. In the Eustachian tube and in the bronchial tubes we find the epi-

thelial cells provided with cilia which constantly vibrate in such a manner as to propel any mucus or foreign substance that may happen to be in the tube, in the direction of the naso-pharyngeal space or of the larynx, as the case may be. The conditions that exist in the external auditory canal do not require any such vigorous propelling power as that supplied by the movement of the cilia in the other channels mentioned, and, accordingly, Nature supplies a less active power, but, at the same time, one that is better adapted to stand the rough usage to which this part of the body is specially liable.

It is not an easy task to harmonize the existence of such an extruding power in the walls of the external auditory canal with the extremely frequent occurrence of the condition known as impacted cerumen. An abnormal activity on the part of the ceruminous glands is undoubtedly the most important factor in the production of this condition. At the same time hypersecretion alone can hardly be held responsible for the production of the impacted state; other factors must certainly aid in producing it. The sharp bend which the canal makes near the external orifice is often associated with such a marked shortening of one of its diameters that for all intents and purposes the canal is very much narrower at this point than it is at a short distance deeper in, where the larger part of the cerumen is secreted. This narrowing of the canal varies greatly in different individuals, and in some no narrowing whatever is found. Where it exists, one can easily conceive how it may prevent a mass of cerumen, of comparatively small size, from being extruded from the canal. When the mass has once been arrested in its movement outward there is no difficulty in understanding how it may grow, by accretions upon its surface, to the full size of the cavity which contains it. Furthermore, it is not unlikely that the individual's own efforts to keep the orifice of the external auditory canal clean, or to relieve the sensation of itching which is so often present in this condition, sometimes result in pushing the accumulation farther inward toward the drum-membrane.

Excessive secretion of cerumen is so often associated with naso-pharyngeal catarrh that it is hard to resist the belief that the former is a reflex phenomenon dependent upon the latter. On the other hand, in certain cases of well-marked deafness, it is a common experience to hear the patients say,—of their own motion, and not in response to a question,—that they never find wax in their ears, and have not for several months or years past. The few cases that I have examined, since my attention was attracted to the coincidence of deafness with absence of the secretion of cerumen, presented the following conditions:—The *membrana tympani* was unusually thin and translucent, though

not appreciably sunken; through its posterior half could be seen the darkly shaded niche of the fenestra rotunda, and, above this, perhaps also the faint outlines of the long process of the anvil. The whiteness of the promontory was also easily recognized through the membrane. On inspection of the pharynx the mucous membrane of this region was found to be pale and very thin; apparently the follicles had all disappeared through atrophy. As I shall have occasion to speak of these conditions again farther on, it is not necessary to enter more minutely into details in this place. If it be once admitted that increased functional activity of the pharyngeal glandular elements may in a reflex manner increase the functional activity of the ceruminous glands, the question at once suggests itself, Why may not the subsequent atrophy of the pharyngeal glands bring about, in the same reflex manner, a wasting of the glands in the external auditory canal? As long ago as 1872, Dr. Oren D. Pomeroy, of this city, expressed himself as follows in regard to this question: "In view of the fact that frequently an absence of a normal amount of cerumen is observed in old cases of aural catarrh, it may, together with the present observations, cause one to infer that the ceruminous function is greatly affected in catarrhal diseases.

"Perhaps a theory of this kind may sometimes be borne out by a sufficient number of facts; that the earlier stages of catarrh result in hyperæmia and consequently augmented function of the ceruminous glands, which, continued, may result in atrophy with abolition of function, precisely as results in inflammation of the mucous membrane lining the fauces," etc.<sup>1</sup>

It is perhaps more in accordance with established facts to consider atrophy as the natural termination of the prolonged increased functional activity of the ceruminous glands, than to consider it as the result of reflex influences. With regard, however, to the first step in this series of changes, I should rather favor the view which refers its origin to a reflex influence, than that which makes the irritation spread directly from the mucous membrane of the middle ear to the skin of the external auditory canal.

*Symptomatology.*—During the formation of the mass, before it has reached such a size as to occlude the canal, the patient, as a rule, experiences no symptoms which would be likely to call his attention to the ear. In cases, however, where the canal is slit-shaped, a sense of fullness or discomfort may be experienced long before the canal is actually occluded,—that is, as soon as the accumulation is large enough to bridge the space between the opposite walls. Complete occlusion may take place so gradually

<sup>1</sup> Transactions of the American Otological Society for 1872: article on an "Examination of 100 cases of Impacted Cerumen."

that the patient's attention is attracted to only one symptom, viz., the gradual diminution of the hearing. In very many cases, however, the statement is made that the diminution in the hearing came on quite suddenly, as, for instance, after a bath, after washing the head, or after some mechanical interference with the ear (introduction of the end of a towel, etc.). This sudden diminution of the hearing may then pass away as suddenly as it came, to return again after the lapse of a few days or weeks. When the canal has become fairly occluded, other symptoms may develop. In a few cases there will be tinnitus, which may be ascribed to pressure exerted by the ceruminous mass upon the drum-membrane, or possibly to the obstruction of the venous circulation in the external auditory canal, thus causing a passive congestion of the veins of the middle ear, which pour their contents in part into those of the meatus. In any given case, however, it is nearly if not quite impossible to determine what share the ceruminous mass, and what the coexisting catarrhal inflammation of the middle ear, take in producing this symptom. Pain can hardly be mentioned among the symptoms of this condition, as it is due to an intercurrent inflammation of the walls of the canal. Cases are on record which seem to show that impacted cerumen may produce, in a reflex manner, epileptiform convulsions. I have also recently read the report of a case in which a chronic bronchial catarrh seemed either to owe its origin to, or to be kept up by, the presence of a mass of impacted cerumen in the patient's auditory canal.<sup>1</sup> At all events, the removal of the mass caused the cough and expectoration to cease in a very short time. Furthermore, cases have been reported in which a high degree of dilatation of the osseous canal is ascribed to the pressure of a mass of cerumen. I believe that cases have also been reported in which even a fatal issue has been referred back to the gradual increase in size of a mass of impacted cerumen. My impression is, that if all these cases could be carefully analyzed, the great majority of them would be found to be in reality cases of desquamative inflammation of the canal (secondary to middle ear trouble), or of otitis media purulenta, with hardening of the purulent secretion in the meatus. Inspissated cerumen forms on the outer side of, and becomes mingled with, these purulent and epidermal products, and so the cases come to be classified among those of impacted cerumen. While it may not be possible in all cases to draw a sharp line of distinction between the milder cases of desquamative inflammation of the canal and those of inspissated cerumen, it is of decided practical importance to make the distinction whenever we can. So far as my

<sup>1</sup> The case is reported in either the British Medical Journal or the London Lancet, in one of the November numbers, (1879).

own experience goes, I may say that I have never seen a case in which the pressure made by a mass of impacted cerumen has caused absorption of the bone and consequent increase in the size of the canal. Nor have I ever seen one in which bronchial catarrh, epileptiform convulsions, or any other equally grave symptoms could fairly be attributed to impacted cerumen, in the strict sense of the term. Tinnitus and moderate dizziness, due probably to the pressure of the mass upon the drum-membrane, are certainly not rare symptoms, but I have never seen a case in which the impacted cerumen had produced actual fainting or loss of consciousness.

*Diagnosis.*—Inspection with the speculum and reflected light reveals the presence, in typical cases, of a black or dark-brown mass, filling the canal, and obstructing the view of the deeper parts. Until the contents of the canal have been thoroughly removed, it is not safe to say positively that the case is simply one of impacted cerumen. All sorts of conditions may be found beyond the outer mass or shell of cerumen, and the physician must therefore withhold or qualify his diagnosis until he can ascertain fully the true state of the ear.

*Prognosis.*—In cases of impacted cerumen, associated with difficulty of hearing, the physician will do well to express his opinion very guardedly with regard to the question of restoration of the hearing-power. It is such a common experience, as I have already stated, to find a chronic naso-pharyngeal and middle-ear catarrh associated with impacted cerumen, that he should always be prepared to find that the catarrhal affection and not the obstructing mass has diminished the acuteness of the hearing. The marked tendency to relapses must also not be forgotten, when a prognosis is given.

*Treatment.*—The question of treatment resolves itself practically into the question, How can the obstructing mass be removed most thoroughly, quickly and pleasantly—both for the patient and for the physician? In the earlier period of my practice I pursued the orthodox plan of employing the syringe and warm water for this purpose. Little by little, however, I became satisfied that in the great majority of cases the removal of the mass could be effected much more quickly and pleasantly by the use of the curettes and the angular forceps than by any other plan; and from that time forward it has been my uniform practice to use the syringe only in certain exceptional cases, for instance, in those in which, after the removal of the greater part of the mass by instrumental means, a semifluid or very tenacious cerumen was found plastered over the drum-membrane; and also in those in which the extreme smallness of the canal rendered it unusually difficult to follow the movements



of the curette with the eye. The objection raised by some authors against the instrumental plan of removing impacted cerumen, *viz.*, that it requires great skill, and may prove highly dangerous in unskilful hands, does not seem to me to be a valid one. Therapeutic methods should be recommended in accordance with their absolute merits, and not because they will be likely to prove the least harmful in unskilled or clumsy hands. The merits of the instrumental plan have already been alluded to, but I will repeat them here. In the first place, when a case of impacted cerumen presents itself for the first time, we cannot say positively what is the condition of the membrana tympani and deeper portions of the canal. The drum membrane may be defective in its posterior and upper portion, thus leaving the stirrup and oval window exposed to the direct shock of the stream of water coming from the surgeon's syringe. Fainting is almost sure to follow the use of this instrument under such circumstances. In the second place, in a large number of cases, the instrumental plan will accomplish in ten or fifteen minutes what the most skilful employment of the syringe cannot possibly accomplish in even an hour's time. In the third place, it is easily possible for a man with average manual skill to acquire such dexterity in the manipulation of the curette, and the other instruments mentioned, that he will be able to remove impacted cerumen from the auditory canal with less discomfort to the patient than is usually experienced when the syringe is used.

As the cases of impacted cerumen differ from each other in important particulars, only very general directions can be given with regard to the proper mode of removing the impacted mass with instruments. In the first place, the physician must follow every step of the operation with the eye. He should use as large a speculum as the size of the canal will permit, and the illumination should be good. If the wax is quite soft, a small channel should be cleared, with the curette, for a short distance along the upper wall of the canal, in order to afford room for the introduction of the cotton-holder armed with a mop of cotton of suitable size. Two or three introductions of the cotton-holder, armed each time with a fresh mop, will usually suffice to remove all the cerumen lying between the external orifice and the farther end of the channel made by means of the curette. The remainder of the mass is to be treated in precisely the same manner, until the whole of it shall have been removed from the auditory canal. If the wax is moderately firm in consistency, the entire mass may be removed piece by piece with the curette. The occasional use of the forceps will also be found advantageous, especially if the surgeon has succeeded, by means of the curette, in separating the mass, or a large portion of it, from its attach-

ment to the walls of the canal. There are certain conditions in which the slender silver probe will be found a more useful instrument than the curette; as, for example, where a mass of cerumen is wedged in between the drum-membrane and the anterior and lower wall of the canal. By giving to the end of the probe a slight curve, one can readily dislodge the mass and bring it within reach of the forceps. In those cases in which, after removing almost all of the obstructing mass, I have found the membrana tympani plastered over with soft cerumen, I have usually resorted to the syringe as the quickest and (to the patient) pleasantest means of removing this remainder of the accumulation. So long as the curette is made to pass flatwise over the walls of the auditory canal, and so long as the force employed is applied in the direction from the periphery toward the centre of the canal, the patient will experience no pain and perhaps not even discomfort. If the canal is quite large and straight, the end of the curette may be bent in such a manner as to make the plane of the ring form an obtuse angle with the shank; and the same kind of dissecting manipulation as that to which I have just referred, can then also be applied to the surface of the drum-membrane. As a rule, however, a sort of scraping motion is the only effective one that can be communicated to the ordinary curette when brought in contact with the membrana tympani. Such a mode of employing the curette is not to be recommended, and therefore, under these circumstances, the syringe is to be preferred.

If the physician, for any reason, decides not to use the instrumental method, he will find that in exceptional, though by no means rare cases, syringing alone will fail to dislodge the impacted mass. The only course left open to him, under these circumstances, is to employ some chemical reagent which possesses the power of softening masses of inspissated cerumen. Water alone, it is true, possesses this solvent power, but its action is extremely slow. Bicarbonate of soda, on the other hand, is quite rapid in its solvent action, and yet at the same time it may be used freely in concentrated solutions, without fear of injuring the walls of the canal.

Dr. Blake, of Boston, employs liquor potassæ, or a solution of caustic potassa, for the purpose of softening hardened masses of cerumen. He arms the end of a probe or cotton-holder with a small mop of cotton, dips it into the solution, and then applies it accurately to the centre of the outer end of the mass. Under the influence of such a strong alkali, the cerumen softens very rapidly, and so, little by little, he is able to bore a channel through the centre of the plug. The remaining shell can then be easily broken into a mass of loose fragments which syringing will quickly bring away from the canal.

Finally, one word more with regard to syringing in cases of impacted cerumen. One of the chief reasons why syringing so often fails to wash out the mass of impacted cerumen, is this: the force of the current is spent upon the broad surface of the outer end of the plug, and tends therefore rather to drive it farther inward. The most effective plan is to direct the stream against one edge (preferably the upper edge) of the mass, in the hope of washing out a channel between the main body of the plug and the upper wall of the meatus. As soon as this has been accomplished, it will be found that the current begins to exert a *vis a tergo* force upon a portion of the mass, and soon brings away fragments of considerable size.

*Complications.*—It sometimes happens, in these cases of impacted cerumen, that a furuncle develops in the obstructed meatus, or that an acute inflammation is set up in the adjacent middle ear. In the presence of such a complication, the question arises, shall we allow the intercurrent inflammation to run its course before we make the attempt to remove the impacted cerumen, or shall we undertake the latter operation without further delay? The pain attending either of the two combinations mentioned is apt to be very severe, and the inflammation is generally more extensive and of a more serious character than when the auditory canal is free from obstructions. If, therefore, we can, by any means at our command, remove these obstructions at once, it is clear that this is the proper course to pursue. If the orifice of the canal is closed, through œdematous swelling of the soft parts, it will be found comparatively easy to dilate it gradually by means of Wilde's specula, or by the aid of conical mops of cotton, wound firmly around the end of a probe or cotton-holder, and smeared with vaseline. As soon as the ceruminous mass has been exposed to view, we should proceed in precisely the same manner as if the case were one of a simple nature.

*Circumscribed Inflammation.*—The external auditory canal seems to possess a special predisposition to furuncular inflammation. Our knowledge of the causes which give rise to the disease is very scanty. An irritating discharge from the middle ear, or from the deeper parts of the meatus (as, for example, in eczema), very often leads to the formation of furuncles in the outer or cartilaginous portion of the canal. It has also been observed that the disease is often encountered in persons whose general health is not quite up to the proper standard.

In a few cases what seems at first to be a furuncular inflammation of the outer portion of the canal proves, later, to be a localized chondromalacosis. The more decided severity of all the symptoms, the greater depth to which the probe may be made to penetrate after the abscess has ruptured, the longer duration of



## DISEASES OF THE EXTERNAL AUDITORY CANAL. 67

the course of the disease, and the necessity, oftentimes, of cauterizing the abscess cavity with strong nitric acid before we can cause it to heal ; all these facts, it seems to me, justify the view that we are dealing with something more profound, more destructive than a simple furuncular inflammation.

Furuncles of any considerable size are encountered only in the cartilaginous portion of the external auditory canal. They probably originate in the sebaceous or the ceruminous glands, which are very large and very numerous in this region. The base of the tragus on the anterior wall of the orifice, is a favorite seat. In the osseous portion of the canal there are very few and very small ceruminous glands, situated chiefly along the upper wall, and, consequently, the furuncles encountered in this part of the ear are very small and insignificant. If a larger abscess is seen in this part of the ear, we may justly suspect that it is connected with disease of the adjacent bone, or with a sinus passing through the soft parts which lie above the drum membrane.

Furuncles as a rule develop gradually. The patient first notices a little pain in the region of the ear, and, on pressing with his finger upon the parts, finds that they are slightly tender. Gradually the pain increases in severity, and the ear feels full and heavy. Deafness is not observed until the tumor reaches such a size that the meatus is closed at the point involved. The motions of the jaw are apt to cause pain, and in some cases there is well-marked œdema in the neighborhood of the affected ear. Rupture of the abscess may take place spontaneously as early as on the second day, but, as a rule, we must not look for this event before the third or fourth day. Healing and subsidence of all inflammatory symptoms usually soon follow. In those cases in which the cartilage seems to be involved, the abscess may go on developing for a week or longer. The whole course of the disease in these cases is much more protracted, and a depressed scar may remain after the parts have healed.

The *diagnosis* is easily made in the majority of cases. The absence of deafness and tinnitus, or the development of these symptoms only after the pain has lasted for two or three days, points clearly to an inflammation that has originated outside of the middle ear. But when the inflammation is of a violent type, when the case is seen only at an advanced stage, and especially when the patient is not very clear in regard to the mode of onset and sequence of the subjective symptoms, considerable difficulty may be experienced in arriving at a correct conclusion in regard to the nature of the disease. Indeed, often it is simply impossible to make a positive diagnosis, and we are obliged to treat the urgent symptoms without regard to what the origin of the trouble may have been.

The *prognosis* is favorable. If there has been no precedent eczema, we may confidently look for a speedy and permanent return of the parts to a natural condition. On the other hand, a chronic eczema renders it highly probable that the first furuncle will be succeeded by others, before the tendency to such outbreaks is overcome, for a reasonably long period. Permanent damage to the parts, even after the most severe attacks of inflammation of the external auditory canal, is not to be expected.

*Treatment.*—The chief indication in this disease is to relieve the patient's suffering. It is a disputed point how this may best be accomplished. Some of the highest authorities unhesitatingly advise the early employment of the knife. My own experience, however, leads me to adopt the rule laid down by Wilde: "As soon as we believe matter is formed and come some way to the surface, but not till then, we should make an incision." I prefer, generally, to wait and let the abscess open by natural processes; and, as a means of hastening these, and also for the purpose of mitigating the patient's suffering in the meantime, I am in the habit of prescribing hot poultices. These should be of sufficient size to cover the entire region of the ear (say 5 or 6 inches square) and they should be renewed at frequent intervals. While the flaxseed-meal poultice is perhaps the best that can be used for this purpose, there are various substitutes which will be found to answer almost equally well; for example, a rubber bag filled with hot water, a flannel or muslin pillow filled with dried hops and heated in the oven or in front of a hot open-grate fire, hot bran bags, a large sponge or several thicknesses of flannel wrung out of hot water, and so on.

I have very little faith in the local use of anodynes, and the introduction of glycerine, sweet-oil, or almond-oil, commends itself still less to my judgment. Glycerine is by no means a bland and soothing fluid, and the oils may furnish a nidus for the subsequent development of the *penicillium glaucum*, or some other variety of fungous growth, which the surgeon may find it difficult to dislodge. Vaseline, on the other hand, may be used with impunity in the ear.

Local blood-letting by means of leeches (or Bacon's artificial leech) is very apt to fail in this form of disease, and I do not often resort to its use if I am sure of my diagnosis. In acute affections of the middle ear it is a much more valuable remedy.

If the knife be employed, the best pattern for this special purpose is a curved, sharp-pointed bistoury. If the swelling is well defined, the incision should be made through the centre of it, the point of the knife being carried from within outward. The operation should be performed under illumination from the forehead mirror, and the incision should be made of such a length

and depth as will afford a free exit to the pus. If the swelling is not well defined, my plan is to introduce a cotton-holder, well protected with cotton, into the swollen canal, and then to exert pressure in different directions. The region of greatest tenderness is that into which I make the incision. It is well to have at hand a large sponge and a basin filled with hot water. Immediately after the incision has been made, the hot and moist sponge should be held against the ear, for the purpose of quieting the pain, which for a few minutes is generally very acute. When the pain subsides, dry warmth may be substituted for the hot and moist application. The only objection to the prolonged use of moist heat under these circumstances is, that it favors the development of granulation-tissue in the wound, and is also apt to set up a painful inflammation of the auricle.

In addition to these local antiphlogistic measures it is well to employ other means which exert constitutional effects. A dose of calomel (one or two grains) or a blue pill (five grains) at night, followed by one-half or two-thirds of a tumblerful of Rubinat-Condal water, or a full dose of Rochelle salts (a tablespoonful in a tumblerful of water), on the next morning (at least half an hour before taking food), will promote the subsidence of the inflammation. Rest in bed constitutes an important part of the general treatment. Finally, it will generally be found desirable to prescribe a tonic (Huxham's tincture of cinchona in teaspoonful or dessertspoonful doses), or even, in the more protracted cases, cod-liver oil (teaspoonful doses of an emulsion with the hypophosphites). If the patient gives a history of eczema, the treatment should be modified by the adoption of such measures as are appropriate for the relief of this condition. These are described elsewhere in this work.

*Diffuse Inflammation.*—Under the head of "diffuse inflammation of the external auditory canal," may be grouped the different pathological conditions to which the names "otitis externa diffusa," "periostitis," "eczema," "desquamative inflammation," and "otomycosis," or "parasitic disease of the external auditory canal," are commonly applied. It is not always easy to separate these different conditions, and to apply to them their proper distinguishing terms. In fact, it is only in a few typical cases that a distinct line of separation can be drawn. Furthermore, no great scientific or practical gain is effected by the establishment of these subdivisions, and I may therefore be allowed to include all under the single head of diffuse inflammation.

A simple diffuse inflammation of the osseous portion of the meatus externus may be set up by the presence of some irritating substance or fluid in the canal. For example, salt water may produce such an inflammation, and so may the irritating dis-

charge from an inflamed middle ear. Among the internal or constitutional causes may be mentioned a predisposition to eczema (rheumatic? gouty?). An inflammation of the medullary spaces or of the air cells of the surrounding bone, may give rise secondarily to a diffuse otitis externa. Direct violence is also not a rare cause of this form of disease.

The physical characteristics of a diffuse inflammation of the external auditory canal are, at first, a general redness and swelling of the skin lining the osseous portion. The membrana tympani almost invariably participates in the inflammation, though sometimes only to a very slight degree. At a later stage of the affection, an exudation of a thin, serous fluid will be found to have taken place from these red and swollen surfaces, and at a still later period the discharge will be found to contain small white flakes, or even large white sheets, representing the cast-off uppermost layers of epithelium. Eventually, ulceration may take place.

*Symptomatology.*—I am quite confident that I should fail if I were to attempt a description of the symptoms which characterize a diffuse inflammation of the external auditory canal (osseous portion). This description might be quite truthful for some one particular case, but for all the others it would be inaccurate. The better plan, it seems to me, is to describe a few typical cases, and then to call attention to the salient points of these. I warn my readers, however, that these typical cases, although valuable because they furnish proof that the disease in question may have an independent existence, are in reality quite exceptional. In actual practice they must expect to find the great majority of cases so complicated that the statement of the correct anatomical diagnosis would require a comparatively long description. No short title, such as will be found at the beginning of this or other chapters of this treatise, would be likely to convey to the mind of any person who might read it, more than a very crude conception of the pathological picture presented. It is often a very difficult task for the physician to acquire a clear conception of the actual sequence of events in any given case of ear-disease; and this is particularly true of the form which I am now endeavoring to describe.

Now and then we have the opportunity of seeing a case of primary inflammation of the skin lining the osseous portion of the external auditory canal, which is so free from complication that we can no longer doubt the existence of such an independent form of aural disease. The following case is one in point:

The patient, a lady, twenty-two years of age, and in a fair general condition of health, stated that four days previously she had experienced quite a sharp pain in both ears. From that time for-

ward she had suffered more or less with pain, but there had been no discharge and only a little deafness and tinnitus. On examination, it was found that the inner half of the canal, on both sides, was red, swollen, and covered with a pasty material consisting chiefly of epithelium. The membrana tympani on both sides was also red and swollen, but chiefly so on the right side. There was tenderness on pressure over both mastoid processes. There was no appreciable impairment of the hearing for ordinary conversation, and the watch, which at first could be heard at a distance of only one inch, was heard at a distance of at least six inches after the pasty epithelium and pus had been removed from the canal. There were no evidences whatever of an acute nasal or naso-pharyngeal catarrh, or of an external eczema, and the patient did not give any history of exposure to cold. The posterior half of the right membrana tympani was incised, but the middle ear was found to be quite free from secretion. Two leeches applied behind each ear, and the frequent use of the hot douche, speedily removed all the pain, and in the course of a few days the parts returned to their natural condition.

So far as the appearances presented to the eye are concerned, this case might perfectly well have been interpreted as one of primary acute inflammation of the middle ear, with secondary inflammation of the contiguous lining membrane of the osseous portion of the auditory canal. The correctness of this diagnosis, however, is rendered improbable by the following considerations: An acute inflammation of the middle ear, of sufficient severity to seriously involve the osseous portion of the auditory canal in the short space of four days, would certainly have been associated with more decided impairment of the hearing, with a more highly swollen and vascular condition of the tympanic mucous membrane, or with a free exudation into the cavity of the middle ear. In the absence of these conditions it seems perfectly proper to classify the case as one of a primary acute inflammation of the skin and periosteum of the osseous portion of the external auditory canal. The inflammation of the cutaneous surface of the membrana tympani is an almost inseparable accompaniment of such an otitis externa diffusa. In a few cases, however, I have found the drum-membrane so little involved that, after I had wiped away the secretion which covered it, and which came from the inflamed lining of the neighboring walls of the canal, it presented only very trifling evidences of inflammation. I have observed this non-participation of the membrana tympani more particularly in those cases which were apparently eczematous in their nature.

I may mention in this connection a second case of diffuse inflammation of the osseous portion of the meatus.

The patient, a physician, thirty-two years of age, and in fair general health, stated that for a period of several months previous to the time at which I first saw him, he had been troubled with a serous or sero-purulent discharge from both ears, associated at times with pain. Occasionally the discharge ceased for several



days or even weeks at a time. He had tried different plans of treatment, but they had all failed to give the desired relief. On examination, I found both auricles perfectly natural, and both external orifices free from any evidence of irritation. The hearing was not appreciably affected, either for the ticking of a watch or for conversation. The osseous portion of the auditory canal was found, on both sides, to be moderately swollen and congested, and covered with a pasty, whitish secretion. The peripheral and manubrial portions of both drum-membranes were moderately congested. The only treatment attempted consisted in the application of a strong solution of nitrate of silver (gr. 120- $\frac{3}{4}$  j.) to the inflamed walls of the canal, two or three times a week. A few such applications were made, but without producing any material benefit. Four months later I saw the patient again, and learned that he had had in succession, at short intervals, at least a dozen abscesses in both canals. He expressed himself as feeling very much discouraged about the condition of his ears. Everything else having failed, I suggested to him the idea of smearing the inflamed canal with Hebra's diachylon ointment, at regular intervals of time. At a later date I learned from the patient that this plan of treatment had proved entirely successful.

The following case must also be classed as one of diffuse inflammation of the external auditory canal:

The patient, a lady, about twenty years of age, and in excellent general condition, consulted me in July, 1871, on account of a constant watery discharge from both ears. She said that during the previous month of March she had passed through an attack of scarlet fever, and that during convalescence she had experienced pain in both ears, followed by a watery discharge which had continued ever since. There had been no appreciable deafness, and no tinnitus. Once or twice the discharge had ceased entirely for a few days. On examination, I found the inner half of the meatus, on both sides, reduced in size by the swollen condition of its lining membrane. The latter was also moderately red. The manubrial and peripheral portions of the membrana tympani were congested, and the intervening portions presented a soaked and opaque appearance. There was very little fluid in the canals—barely enough to moisten them. The ticking of a watch was heard at a distance of four feet, on both sides. The Eustachian tubes were freely pervious to air, and there was no noticeable catarrhal irritation of the naso-pharynx. Instillations of a solution of sulphate of zinc were prescribed. Four weeks later the patient returned to the city and reported that the discharge had rather increased than diminished under the treatment which I had advised. On examination, I found that no material change had taken place in the condition of the canals. I carefully wiped away all moisture from the inflamed surfaces and then filled the canal with a strong solution of nitrate of silver (120 grains to the ounce), the patient's head being turned well over toward the opposite side. As soon as she felt a distinct sensation of warmth in the ear, I removed the solution from the meatus by syringing it out with warm water. Both canals were treated in this manner. Two weeks later I saw the patient for the third time. No discharge whatever had been observed by her during the interval, and the ears then felt perfectly natural in every respect.



## DISEASES OF THE EXTERNAL AUDITORY CANAL. 73

On the 11th of September, 1878,—that is, seven years later,—she again came to see me with regard to her ears. According to her statement there had been a discharge from both canals since the early part of the preceding July. There had been no deafness, and the parts presented very nearly the same appearance as they did seven years previously. After drying the canals thoroughly, I applied powdered iodoform to the inflamed surfaces, and instructed the patient not to syringe the ears unless a discharge showed itself at the outer orifice. On the 14th I found the ears in precisely the same condition as on the 11th, and the patient had not observed any diminution in the activity of the discharge. I again dried the canals, and applied powdered burned alum instead of iodoform. On September 20th, very little, if any, improvement having taken place in the meantime, I mopped out the inner half of each canal with a saturated solution of nitrate of silver; the parts being kept thoroughly moistened with the solution until a distinct sensation of warmth was experienced by the patient. On the 25th of September, I found the walls of the canals and the drum-membranes perfectly dry and free from noticeable redness.

On the 25th of October she came again to see me, as her ears felt full and the discharge had returned. I again used the saturated solution of nitrate of silver, but allowed it to remain longer (about five minutes) in contact with the inflamed parts. Three days later she reported that she had experienced some pain after the last application of the silver solution, but that on the following day her ears again felt quite natural, and the discharge had not returned since. As the patient never returned after this visit, I infer that the cure proved to be permanent.

In a fourth case, which came under my observation a few years ago, the eczematous nature of the affection was very plainly indicated.

The patient, a girl eighteen years of age, stated that for nearly a year she had had an intermittent discharge from both ears. On examination, I found both auricles noticeably red and covered with crusts. The canals were filled with pus and flakes of epidermis, in about equal proportion. The walls, however, showed very slight evidences of active irritation. The drum-membranes also showed merely a soaked and opaque appearance, but no marked swelling, such as we should have a right to expect if they had participated actively in the inflammation. The discharge seemed to come chiefly from the walls of the osseous portion of the meatus. The hearing, after the pus had been removed from the canals, was found to be quite good, both for the watch and for spoken words. The results of treatment may be briefly stated as follows: at the end of seven days, under the use of oil of cade (ʒj.) and vaseline (ʒvij.), the auricles presented as natural an appearance as if they had never been covered with repulsive masses of crusts. At the end of four weeks, the discharge from the auditory canals was still as active as ever, and the patient's faith in an ultimate cure had so nearly vanished that she was unwilling to submit to further treatment. Insufflations of powdered burned alum and of iodoform failed to exert the slightest influence upon the activity of the discharge. Twice the affected parts, the drum-membrane included, were painted thoroughly with acetum cantharidis, but it also seemed to exert

no restraining influence upon the activity of the discharge, and—what was stranger still—did not even produce the stinging sensation, or sensation of warmth, which it almost invariably produces when applied to the auricle. On two or three occasions I succeeded in arresting the discharge entirely for several days at a time, by employing a strong solution (120 grains to the ounce) of nitrate of silver. The last time, however, I employed a saturated solution, and allowed it to remain in the canal for several minutes. It failed, not only to arrest the discharge, but even to produce the customary sensation of warmth in the ear. As already stated, the patient at this stage became discouraged, and discontinued her visits.

A few cases—perhaps half a dozen in all—have come under my observation, which undoubtedly belong in this category, but which nevertheless present either no physical evidence of their eczematous nature or only such as can be discovered on a very close scrutiny. The following case, which I saw recently, will serve as a type of the entire class.

The patient, a lady about forty years of age, and a sufferer from some form of uterine disease, stated that during the preceding two or three weeks she had experienced every night, whenever she lay upon the right side, a distressing sense of heat in the right ear, followed by a slight watery discharge. As she could not lie upon the left side for any great length of time, the symptom complained of interfered seriously with her night's rest. During the day time she was propped up in bed, and then she experienced absolutely no discomfort in the ear. There was no tinnitus and no impairment of the hearing. On examination with the speculum I found a limited and very small area of barely recognizable redness of the skin, on the floor of the canal, about midway between the external orifice and the membrana tympani. I could discover no other lesions in any part of the ear. On the opposite side of the neck and on the forearms were three small areas of what seemed to be a circumscribed eczema. I prescribed the use of a hair instead of a feather pillow, and advised her to fill the external auditory canal two or three times daily with a fluid preparation which is sold in the shops under the name of "Bacon's Canadian Emollient," and which seems to have been derived—to judge from its agreeable odor—from Canada balsam. I also suggested the free use, internally, of lithia-water, as there were reasons for believing that the disease was gouty in its origin. In a very few days she was relieved entirely of the distressing nocturnal heat and discharge, and the area of redness in the meatus entirely disappeared.

So far as my small experience with this particular group of cases goes, the favorable issue just described is entirely exceptional, and sufficient time has not yet elapsed to enable me to say whether it is permanent in character.

In this connection I may mention the fact that during the past six or eight weeks I have made a practice of prescribing the free use of the Canadian Emollient in all the cases of eczema of the canal that have come under my care, and I am disposed to believe

that it will be found in certain cases to be a good substitute for the oil of cade and vaseline mixture. The odor is very pleasant and the skin is not discolored by it—two decided advantages. It remains to be seen, however, whether the excellent curative effects produced by its use in perhaps eight or ten cases will be experienced in a larger series of cases.

The instances already narrated illustrate sufficiently the symptomatology and course of the more typical cases of acute and chronic diffuse inflammation of the external auditory canal. The primary acute cases are comparatively rare; on the other hand, acute exacerbations of the chronic form of the disease are often seen in aural practice, and are very apt to be associated with abscesses of the cartilaginous portion of the canal. This latter complication requires no further consideration in this place. There is another complication, however, which must be discussed at greater length. I refer to the growth of the different varieties of *aspergillus* in the inflamed canal. In this connection I may say that I agree entirely with those authorities who consider the presence and growth of this vegetable parasite in the auditory canal




FIG. 25.—*Aspergillus* from External Auditory Canal. —*M*, mycelium; *H*, hypha; *S*, spores; *Sp*, sporangium; *G*, gonidium. (After Urbantschitsch.)

or middle ear as simply an accidental complication, and not as an independent cause of disease in either of these localities. The diffuse inflammation of the canal or the chronic inflammation of the middle ear, especially if a large perforation in the membrana tympani leaves this cavity unnaturally exposed to the air, supplies a soil suitable for the growth of the sporules or germs with which the air is everywhere and at all times filled. An ear in a state of active secretion of pus or other fluid, is not likely to furnish more than a momentary lodgment to these germs. The character of the fluid secreted also probably has much to do with their development; certain secretions being better suited for their growth than others. The cases in which the parasitic growth is most frequently observed are precisely

these cases of diffuse inflammation of the osseous portion of the auditory canal. In the early stages of this disease the red and swollen skin lining the osseous portion of the meatus, and covering the outer surface of the membrana tympani, secretes just enough fluid to keep the parts moist, but not enough to give rise to a current. The conditions supplied here—moisture, absence of motion either in the fluid or in the surrounding air, and possibly darkness—are eminently favorable to the further development of the aspergillus germs. On two or three occasions I have had the good fortune to examine the ear just at the stage in which the fungus had reached its full aërial development. This happened in the following case :

The patient, a female, thirty-five years of age, stated that about four weeks previously she noticed a sensation of fullness in the right ear, and, supposing that it was due to the presence of hardened wax, she dropped some sweet oil into the meatus for the purpose of softening it. In the course of a few days she experienced a little pain in the affected ear, and again quite frequently during the following three weeks, but at no time was there any discharge. At the time I saw her, the hearing for the watch was reduced to  $\frac{1}{4}$ . On examination with the speculum and reflected light, the outer half of the meatus was found to be perfectly normal. The lower half of the drum-membrane and the lower wall of the osseous portion of the canal were covered with a continuous, white, fuzzy material, which looked very much like cotton-wool. Here and there the whitish surface was dotted with small black specks. The upper portion of the membrana tympani and the rest of the osseous canal presented a red and moderately swollen appearance. Portions of the material removed from the auditory canal were examined with the microscope and found to be composed of the whitish or yellowish-white variety of the fungus, intermingled with occasional specimens of the black variety.

Under the use of instillations of a weak solution of carbolic acid, the ear slowly improved, and when seen for the last time, about six weeks subsequent to her first visit, the parts had nearly returned to their normal condition.

So far as my experience goes, it is quite common to find the black and white varieties growing side by side in the same ear. The white variety usually preponderates. Beside these two commoner varieties of fungus, there are others with which I have had no personal experience. Those who are interested in the subject will find these rarer varieties fully described in a paper published in 1879 by Dr. Charles Burnett.<sup>1</sup> In former years I made a careful search with the microscope for the fungus in every suspicious case. Perhaps once in five or six times I was successful in finding the parasite ; but, as the discovery never materially altered my plan of treatment, and as the searches consumed a great deal of time, I soon abandoned the practice altogether.

---

<sup>1</sup> American Journal of Otology, vol. I., No. 2. New York, 1879.

*Diagnosis.*—There is no difficulty whatever in recognizing the red, swollen, and perhaps moist condition of the osseous portion of the auditory canal. We can then say positively that a diffuse otitis externa exists. If the drum-membrane presents at the same time a normal or at least a non-inflamed condition, we can, with considerable confidence, make the diagnosis of a *primary* inflammation of the osseous portion of the canal. The question of its *acute* or *chronic* nature can only be determined after we have heard the history of the case; and even then we may readily be misled, as patients are often not aware of the existence of a chronic or subacute otitis externa diffusa until their attention is called to it by the pain or sense of fullness caused by an acute exacerbation of the inflammation. The point, however, around which the greatest interest centres, is the condition of the middle ear in many of these cases. The drum-membrane being red and swollen, we naturally ask ourselves the question: Is the diffuse inflammation of the auditory canal merely an extension of that which is apparently going on in the middle ear? or, Is the membrana tympani, by virtue of the intimate relations existing between its outer layer and the skin of the osseous portion of the canal, involved secondarily in an inflammation which really began in this latter region? This question, as I have already stated, cannot be determined by inspection alone. We must test the hearing, examine the condition of the naso-pharyngeal mucous membrane, and ascertain, by auscultation, during the act of inflation, the condition of the middle ear and Eustachian tube. If there is comparatively little disturbance of the hearing, if there is no evidence of an acute naso-pharyngeal catarrh, and if the air enters the tympanic cavity freely and without râles or crackling sounds, we are fairly justified in pronouncing the disease an acute primary diffuse inflammation of the external auditory canal.

The presence of *aspergillus* can only be determined positively by placing some of the suspected products under the microscope, and demonstrating the presence of the stalks, and perhaps also of the fruit of the parasitic plant.

*Prognosis.*—The different forms of diffuse inflammation of the auditory canal have very little tendency to damage the hearing, and apparently none whatever to spread toward the middle ear or mastoid cells. By direct extension it may excite a subacute mastoid periostitis. It is very apt also to occasion, or be associated with, furuncles of the cartilaginous portion of the canal. In the acute cases the prospects for an early and complete cure are good; in the chronic ones, our prognosis must be guarded, as the disease is at times exceedingly stubborn, and relapses are very common.

*Treatment.*—Our treatment of this disease must vary according

to the stage or condition in which the disease happens to be. Thus, for example, if pain is a prominent symptom, the warm douche will be found very effective in allaying it. Other methods of applying dry or moist heat may answer the same purpose equally well. If the pain still continues, after these measures have been fairly tried, leeches may be employed with advantage. It is rare, however, that a primary diffuse inflammation of the canal gives rise to severe pain. If the parts have begun to secrete fluid, we should resort to the use of astringents. The rules which guide me in the choice of these local remedies are very simple. Now and then I yield to the temptation to try some new remedy in the hope of obtaining better results than those which I usually obtain. Whenever I do so, however, I almost invariably meet with ill-success, and am glad to return to the use of silver nitrate in solutions of different strengths. While the pain continues, I abstain entirely from the introduction of any other fluid but water into the canal. After the pain has subsided, and moisture begins to show itself in the meatus, I resort to the employment of the remedial solution. In cases of recent origin, and especially when it may not be convenient for the physician to make the applications himself, a weak solution of acetate of lead may be prescribed (two grains of the salt to an ounce of distilled water, with the addition of ten minims of dilute acetic acid). I instruct the patient to syringe out the ear as well as he can, and then to turn his head over toward the affected ear, in order to remove from the meatus any free water that might otherwise remain in it. After he has done this, he should hold his head in such a position that he can readily fill the auditory canal, by means of a dropper, with the solution which he proposes to use. It is not necessary to warm the solution beforehand, unless the bottle containing it has been standing in a very cold room or closet. I have arbitrarily chosen five minutes as the proper length of time for the solution to remain in the ear, and instruct my patients accordingly. It is not necessary to syringe out the solution after it has remained for a sufficient length of time in the canal; it is enough to allow it to run out of itself by holding the head in the proper position. The instillations should be repeated two or three times a day, as circumstances may permit.

In the more chronic cases, and especially in those which are characterized by a rather abundant secretion of fluid, it is almost useless to employ acetate of lead, or any of the milder remedies often recommended. I have repeatedly tried powdered burned alum and iodoform in cases of this kind, but rarely with any appreciable benefit. I might almost say that I have never obtained prompt and decided results in this class of cases except by the employment of the stronger solutions of nitrate of silver. This

astringent seems to possess certain properties which apparently do not belong to any other astringent; or else the properties which are common to them all are much more strongly marked in nitrate of silver than in any of the others. However this may be, it appears to me to be a well-established fact that no other drug possesses, in so high a degree as does nitrate of silver, the power of restraining, in inflamed tissues, the production of lymphoid corpuscles. In the disease which I am now considering, the best method of applying the remedy is by instillation. The physician should always make the applications himself, as a person who is not in the habit of handling solutions of nitrate of silver will be quite sure to stain the patient's neck or clothing with the remedy.<sup>1</sup> Before we introduce the solution into the thoroughly cleansed meatus, the syringe and vessel of warm water should be placed within easy reach. After the solution (not previously warmed) has been dropped into the canal, my plan is, not to leave it there for any fixed period of time, but to allow it to remain until the patient experiences a distinct sense of warmth, or a throbbing sensation, in the ear. I always ask the patient beforehand to direct his attention to his ear, and to notify me as soon as he perceives either of the sensations referred to. With a solution of only sixty grains to the ounce, the sensation of warmth will generally not be felt by the patient until after the lapse of three or four minutes; with a solution of double or treble that strength, the sensation is usually experienced much sooner. As soon as decided warmth, throbbing, or perhaps even a little pain, is felt by the patient, I proceed to syringe out the solution with tepid water. Very often a single such application of the nitrate of silver will be found sufficient to arrest the discharge completely. In other cases several applications will be found necessary. While I am not aware that there is any serious objection to the daily employment of these strong solutions, I have followed the practice of making such applications only on alternate days, assuming that it is better not to interfere with the inflamed parts too frequently. If the discharge is quite active, the patient should be instructed to syringe out or douche the ear with tepid water once or twice a day.

If these measures fail, we may try the plan of smearing the canal with Hebra's diachylon ointment, or, better still, with the oil of cade and vaseline oil mixture, or the patient may be put upon a course of internal treatment with Fowler's solution of arsenic. I have had too little experience, however, with the latter plan of treatment, in cases of diffuse inflammation of the osseous portion of the canal, to express a decided opinion with regard to its effi-

<sup>1</sup> While the stains are fresh, it is easy to remove them with potassic cyanide, or even, in some cases, with potassic iodide.



cacy. In a single case I have known beneficial effects to follow a prolonged radical change in the patient's diet and mode of life. To prescribe such a radical change, however, to a person who has been accustomed to rather high living, and who experiences comparatively trifling annoyance from his chronic diffuse otitis externa, would probably appear to him like suggesting the substitution of a greater for a lesser evil.

Finally, it is necessary to consider the question how far we should modify our treatment when we discover that a diffuse otitis externa is complicated by *aspergillus*. During the early part of my practice I attached great importance to the local use of such remedies as carbolic acid, absolute alcohol, etc., in the belief that the employment of some form of parasiticide was almost absolutely essential to a speedy cure. So far as the carbolic acid was concerned, I soon found that, even in very weak solutions (two grains or even one grain to the ounce), it frequently rather added to, than diminished, the existing inflammation; and as for the alcohol, I could not satisfy myself that it possessed any special advantages as a local remedy in this disease. In one case I found that powdered iodoform seemed to act directly as a parasiticide. As this case presented other features of decided therapeutic interest, I may be permitted to narrate it briefly.

The patient, a lady, thirty-five years of age, in excellent general condition, though about six months advanced in pregnancy, stated that for a period of five or six weeks she had experienced uncomfortable sensations in the left ear, amounting at times to decided pain. During the previous twenty-four hours there had been a slight discharge from the auditory canal, and the pain had been more acute than usual. On inquiring more particularly into her mode of life, etc., I learned that she had had so many miscarriages that her physician, as soon as the fact of the present pregnancy had been established, advised her to remain quietly in her room throughout the remainder of her term. At the time when I saw her, in the month of November, she had been confined to her room at least three months, and had not—so far as I could judge from her well nourished condition and rather ruddy face—materially changed her previous habits of eating. On examination, I found that a furuncle occupied the upper wall of the left meatus, close to the outer orifice. The inner half of the canal and the drum-membrane were covered with a whitish, pasty material, which I interpreted to be chiefly cast-off epidermis from the underlying inflamed skin. The *membrana tympani* was entire, and the ticking of the watch was heard readily at a distance of two feet. As the abscess had just broken, I advised no other treatment beyond the occasional use of the warm douche.

Two weeks later, she reported that the pain had not returned, but that the ear felt full and heavy. She had also noticed that the water which had been used in douching her ear was full of whitish flakes. On examination I found the deeper portion of the canal stuffed full with a whitish material, interspersed with black spots, which, on microscopic examination, was found to consist partly of *aspergillus* (*A. flavescens* and *A. nigricans*) and

partly of exfoliated epithelium. I prescribed instillations of a weak solution of carbolic acid (1½ gr. to the ounce).

On the following day, for reasons which are not stated in my notes, I discontinued the use of the carbolic-acid solution, and mopped out the inner half of the canal with a saturated solution of nitrate of silver.

Two days later she stated that considerable pain followed the application which I had last made, but that afterward her ear felt much better than it had for some time past. On examination I found the membrana tympani and adjacent walls of the canal covered with a dirty-looking dry crust. With the view of softening and ultimately removing this scab-like formation, I advised her to resume the use of the douche, which had been discontinued during the previous two days.

At the next visit, two days subsequently, I again found the canal almost filled with the parasitic growth. I removed it as thoroughly as possible, and then applied powdered iodoform very freely to the inflamed tissues. I also instructed the patient not to use the douche for several hours, in order that the remedy might be allowed sufficient time to exert its full curative effects.

At the end of forty-eight hours I found the canal more tightly packed with the fungus than on any previous occasion. I cleaned and dried it thoroughly, and again applied the powdered iodoform freely to the inflamed surfaces. This time I instructed the patient not to use the douche unless a discharge should show itself at the outer orifice, or unless the pain in the ear should become quite severe.

On the next day but one, the patient reported that she had experienced occasional twinges of pain in the affected ear, but had not discovered any evidences of a discharge. On examination I found the yellow powder still lying upon the drum-membrane and coating the inner end of the canal. The parts were still red and swollen, but they were perfectly dry, and not a trace of the fungus could be seen. As some of the hard, scab-like formations still remained in the canal, I ordered two or three instillations of a weak solution of bicarbonate of soda, for the purpose of softening them.

On the following morning she had quite a sharp attack of pain in the ear. Later in the day I made an examination, and found the meatus dry and free from scabs, but decidedly more swollen. I accordingly recommended that two leeches should be applied in close proximity to the tragus. This was done, and on the following day I found her in a much better condition. The leeches had removed the last vestige of pain; there had been no discharge; she could hear the watch a distance of 2½ feet; and, on examination with the speculum, I found that the redness and swelling had diminished in a very marked degree. Perfect recovery followed in the course of a few days.

This case presents certain features which are of decided therapeutic interest. In the first place, the application of the saturated solution of nitrate of silver had arrested all secretion from the inflamed wall of the canal and dermoid surface of the membrana tympani. The meatus, therefore, no longer provided a suitable soil for the growth of the aspergillus. If I had paid no attention to the scab-like formations in the canal, whose presence there could certainly have done no harm, and had abstained from

introducing water into it, the patient would probably have made a rapid recovery from that day forward. The douching, however, probably relaxed again the recently secreting skin of the deeper parts of the canal, and so invited a new growth of the fungus; in any event, it supplied again the moisture necessary to the development of its germs. The same mistake was also made after the first application of iodoform. Water was introduced into the canal only a few hours after the powder had been placed there, and the result was the speedy development of the fungus a second time. The next time I used the iodoform, no water was introduced into the meatus for forty-eight hours, and inspection at that time showed a complete absence of the fungus. Water, however, was then introduced for a third time. A rather violent reaction followed, but, for some reason unknown to me, no visible growth of the fungus took place.

I have so frequently, in this form of disease, had good reasons for believing that the presence of free water, or even simply of moisture, in the auditory canal, has caused a return of the inflammation and discharge, that I now make a practice of carefully drying the meatus and the drum-membrane, and then of smearing them with the mixture of vaseline oil and oil of cade, before dismissing the patient from my office.

*Desquamative Inflammation.*—This form of disease differs from the other forms of diffuse inflammation of the osseous portion of the auditory canal in that its products consist almost entirely of continuous sheets of epithelium. I was formerly<sup>1</sup> disposed to consider the disease as quite distinct from that form of diffuse inflammation of the canal which we sometimes encounter in well-marked cases of eczema of the auricle. More recently, however, I have seen several instances of fully developed desquamative otitis externa in patients whose auricles or neighboring skin surfaces were affected with unmistakable eczema. I am therefore quite ready to admit that the disease may have some connection with eczema, or that all these different forms of diffuse inflammation of the auditory canal may be essentially one and the same disease. As a matter of convenience, however, it is advisable to keep these different varieties or types distinct in our minds, and to know them by separate names.

A certain amount of desquamation almost always takes place in every case of acute diffuse inflammation of the auditory canal. No special importance is attached to the phenomenon, and it passes for one of the regular manifestations of the disease. In those cases, however, to which the term "desquamative" should be restricted the canal is often found tightly filled with layer upon

<sup>1</sup> See an article, by the author, on Desquamative Processes in the Ear, in the Medical Record of Dec. 15, 1877.

layer of epithelium. We remove these products, and clean the canal thoroughly, but in a comparatively short time we find it again filled tightly with the same sort of laminated sheets of epithelium. Some of these cases have been under my observation now for a period of several years, but the desquamative tendency is apparently as strong to-day as it was when they were first seen. Furthermore, I have not observed the slightest disposition in any of these cases to change their peculiar desquamative type for one in which the secretion of pus is the predominant feature. It seems to me, therefore, that this form of diffuse inflammation of the auditory canal is better entitled to recognition as a separate disease than is any other form of diffuse inflammation of the canal.

*Etiology and Symptomatology.*—This disease, in its early stages, does not seem to be accompanied by any symptoms that would be likely to call the patient's attention to the ears. At all events, I have never seen a case in which a perfectly healthy ear became the seat of changes, which I should be justified—in the light of the subsequent progress of the case—in considering as the early manifestations of this disease, and I am therefore unable to describe the conditions which characterize these earlier stages. When the canal has become filled with the exfoliated epithelium, the resulting deafness or discomfort leads the patient to consult a physician, and it is in this advanced stage, therefore, that we first see this form of disease. Occasionally we see cases of diffuse inflammation of the canal which run an acute course, and which are characterized by the exfoliation of very large quantities of epithelium in sheets of perfect whiteness. In these cases, however, the canal returns to a normal condition after the subsidence of the acute symptoms, and we can therefore hardly consider the pathological picture presented as that of a commencing (chronic) desquamative inflammation of this region. How the disease begins, and what are its exciting causes, are questions which I am unable to answer. I believe, however, that in many instances the process may be looked upon as a chronic periosteitis, excited originally by an inflammation of the underlying bone, the result of an extension (perhaps years previously) of inflammation from the middle ear.

The simpler forms of the disease are undoubtedly of common occurrence, and will be found grouped, by many authors, among the cases of impacted cerumen. The appearances presented to the eye, before any efforts have been made to remove the obstructing mass, are very often those of impacted cerumen pure and simple. As we proceed to dissect out the mass, we find that beyond the outer layer (that nearest to the external orifice) of cerumen, lies a tough, leathery mass, composed of laminated

epithelial sheets at the periphery, and of a conglomeration of dried pus, variously shaped masses of epithelium, crystals of cholesterin, cerumen, etc., in the centre. When we separate the outermost layer from the underlying skin, we find the latter in various stages of inflammation. In the milder cases, the skin will simply present a vivid red color; in the severe ones I have found even well-marked ulceration. In many of these cases the drum-membrane seems to take no part in the desquamative process, which may be confined to the outer half or two-thirds of the osseous portion of the canal, and the inner third of the cartilaginous portion. In one of the cases, of which I kept a careful record, the region of vivid redness ended quite abruptly at a distance of about five or six millimetres from the posterior and inferior margin of the drum-membrane. In another case I found the desquamative process limited to a boat-shaped depression in the lower wall of the osseous portion of the canal. No satisfactory history could be obtained in this case, but it seemed reasonably clear that at some time in the past, probably in the man's boyhood, caries and exfoliation of quite a large portion of the lower bony wall of the canal had taken place. The chronic desquamative inflammation of the skin lining this excavation had caused the patient no pain or discomfort until the steadily increasing laminated mass of epithelium, no longer finding room for itself in the excavation, began to exert pressure. Then the patient experienced moderate pain in the ear and consulted a physician. The true condition of the parts was fully recognized, and prompt relief was afforded by dissecting the tough mass out from its bed in the bony canal. About once a year, for a period of five years, this patient experienced more or less discomfort in the ear, and each time he obtained entire relief by having the impacted mass removed. In a third case, I saw the patient for the first time in 1875, and for the second in 1877. Both times I found the impacted masses to be composed of quite small flakes or fragments of epithelium intermingled with hardened pus. The face, neck, and hairy scalp bore unmistakable evidences of eczema. The walls of the canal, after the impacted mass had been removed, were found to be red and swollen, but comparatively smooth. The drum-membrane had apparently escaped altogether. As the impacted masses, on both the occasions mentioned, were found to consist of only small epithelial flakes, which did not show the slightest disposition to assume a laminated arrangement, and which furthermore were largely intermingled with dried pus, I was disposed to consider this case as distinctively eczematous in character, and quite different from those cases in which the desquamative process shows a disposition to produce chiefly laminae of epithelium intermingled with very

little pus. More recently, however, I have had opportunities of examining this patient's ear, and on each occasion I have found the laminated arrangement of the cast-off epithelium as well characterized as we ever see it. The last time I examined the ear I found that the inflammation of the canal had produced actual ulceration of the cutaneous surface, especially along the lower wall and near to the drum-membrane. It is therefore clear that a strict separation cannot be made between these two classes of cases—the eczematous and the desquamative.

I have already alluded to the fact that when the desquamative tendency becomes established, it seems to persist for a long time, and to retain its own peculiar type. The following case affords a good illustration of this fact, and also shows how the membrana tympani itself may participate in the desquamative process.

The patient, a strong, healthy sailor, consulted me at the New York Eye and Ear Infirmary, on the 23d of February, 1876. He complained of constant dizziness, and almost unbearable tinnitus in both ears "for some time past." No satisfactory information could be obtained from him with regard to the condition of his ears in previous years. The deafness was so marked that I was obliged to speak to him quite loudly in order to make myself heard. On examination both auditory canals were found to be filled with cerumen. After the removal of these masses, which were found to be composed entirely of cerumen, it was ascertained that a tough, leathery mass of laminated epithelium covered each membrana tympani to a depth of not less than one millimetre, and completely filled the recess at the lower and anterior portion of the inner end of the meatus. When touched with the probe the outer surface of the mass felt as hard and almost as smooth as parchment. The removal of these epithelial deposits was accomplished by means of the slender probe, the forceps, and the curettes; a solution of bicarbonate of soda having first been employed for the purpose of softening them and loosening their connections. The difficulty of the task was greatly increased by the circumstance that, whenever the instrument touched the wall of the osseous portion of the canal, the patient was seized with an irresistible desire to cough. This "ear cough," interfered so seriously with my manipulations that it was not until the fifth or sixth sitting that I finally succeeded in removing the last layer of epithelium. The pain caused by the manipulations also increased the difficulty which the patient experienced of keeping his head perfectly quiet. After the removal of these masses from both ears, the drum-membrane, on each side, was found to be red, somewhat thickened, and adherent in its central portion to the opposite promontory. The neighboring walls of the canal also presented an inflamed appearance, but no recognizable ulceration or inequalities of the surface. The dizziness and distressing tinnitus were in a great measure relieved by the removal of the obstructions, and there was a little improvement in the hearing.

Since 1876 I have seen the patient twice, and on both occasions I found that the pathological condition described above had reproduced itself.

In a fifth case, finally, the desquamative process was allowed to

go on unchecked for a long time—probably for a period of twenty years. The bony canal containing the laminated epithelial mass was found to be enlarged to fully twice its normal size. After the impacted mass had been removed with considerable difficulty, the walls of the dilated portion were found to be in an ulcerated and granulating condition, with a limited area of exposed bone surface. The inner wall of this large cavity presented the appearance of a uniform granulating surface, in which not a trace of the membrana tympani, ossicles, or labyrinthine fenestræ could be distinguished. While a great deal of this damage may legitimately be looked upon as the effect of prolonged pressure exerted by a mass located in the auditory canal, and constantly increasing in size, it seems to me scarcely doubtful that the original disease, out of which this desquamative affection subsequently grew, was a destructive inflammation of the middle ear, with probably exfoliation of part of the bony wall of the canal. However, the patient, a woman of average intelligence and forty-one years old, was positive that she had never had a discharge from the affected ear, but admitted that, for a period of twenty years, she had experienced frequent earaches and more or less deafness in that ear.

*Diagnosis and prognosis.*—The products of this form of inflammation are so easily distinguished from pus and cerumen that an error in diagnosis can scarcely occur. It is only in cases like that of the sailor (see preceding page) that some difficulty might be experienced in recognizing the true condition of things in the ear. In this particular case the dry, hard, and comparatively smooth cul-de-sac at the inner end of the auditory canal would be very likely, at first sight, to be taken for a greatly thickened drum-membrane. The correct interpretation of the condition observed suggested itself at once as soon as the curette was used. At almost all points the hardened mass that occupied the inner end of the meatus, merged, without any noticeable line of demarcation, into the neighboring skin of the canal. In one or two places, however, a free edge of thin cuticle indicated where the line of separation occurred. The curette was applied to these points, and, with a little cautious dissecting, the fact was ascertained that the thin, free edge of cuticle constantly grew thicker as the dissection was continued farther and farther inward. The desquamative nature of the affection was thus established beyond a reasonable doubt.

With regard to the *prognosis* of the disease, I should not be justified in expressing any very positive opinion. The simple removal of the obstructing mass almost always affords the patient such marked relief that he does not care to submit to a course of treatment which would have for its object, not the relief

of a present trouble, but the prevention of a future one. My experience in the radical treatment of the disease is therefore very small, and I must limit myself to the statement that, if left to itself, the disease is quite certain to reproduce the impacted state in from two months to two or three years.

*Treatment.*—If the auditory canal is filled with laminated epithelium, dried pus, and other matters, the first step in the treatment should be to remove the impacted mass. The quickest way of accomplishing this is to dissect out the mass, or loosen its attachments with the curette, and then to extract it with the forceps, or with the curette used as a pry or shallow hook. If the mass does not form a connected whole, it must be broken down into fragments and removed piecemeal. The syringe alone, in this class of cases, will be found a very inefficient instrument. I have repeatedly seen cases where, after the syringe had been used several times in succession without success, the mass was easily removed in a few minutes by means of the curette and forceps. If the desquamated epithelium is found firmly adhering to the membrana tympani, in the form of a continuous leathery mass, it is advisable to soften it first before we make the attempt to detach it from the membrane. Strong solutions of bicarbonate of soda may be used for this purpose.

Once the impacted mass has been removed, the question confronts us, How can we prevent the canal from again becoming obstructed with a similar accumulation? or, in other words, How can we radically cure the desquamative inflammation of the auditory canal? So far as my own experience goes, I am unable to give any very satisfactory answer to this question. I have obtained the best results from the daily use of the lukewarm douche, continued for a period of several weeks; but I cannot report a single instance in which, by this means, or by instillations of weak solutions of the acetate of lead, a well-marked chronic desquamative otitis externa, with intact drum-membrane, was really cured. It would be manifestly unfair, however, to pronounce the disease incurable upon the very limited experience which I have had, and yet it is hard to see how anything like an extended experience in the radical treatment of the disease is to be gained. In private practice persons whose ears feel perfectly natural, and whose hearing is fairly good, are usually not disposed to undergo a long course of treatment directed solely to the ear. In infirmary practice, it is useless to even suggest such a course of treatment.

*Ulcers, Polypoid Growths and Caries.*—The pathological conditions enumerated in this title are sometimes encountered as independent affections. By this I mean, first, that ulcers and polypoid growths—and possibly also caries—may occur as genu-



ine primary affections of the auditory canal; and second, that all three conditions, although at first simply accompaniments or sequelæ of a purulent inflammation of the middle ear, or of some other local disease, may be raised to the dignity of primary or independent diseases through the complete subsidence of the original affection. Thus, for example, no one will dispute the primary<sup>1</sup> or independent nature of syphilitic ulcers and condylomata of the auditory canal; and with regard to the occurrence of similar non-syphilitic lesions in this part of the ear my impression is that they always represent the effects of some antecedent more general disease of either the meatus itself or of the middle ear, and as they form an essential part of those diseases, it will be more appropriate, I think, to describe them under those headings than in the present section. So far as the independent occurrence of the lesions under consideration is concerned, the following brief histories of cases contain all that I have to say on the subject:

The first case is that of a healthy boy, seventeen years of age. On the 7th of April, 1877, he consulted me for the first time, and gave the following history of his trouble. During the previous summer he had passed through an attack of typhoid fever, and while he was convalescing a large abscess developed in the right parotid region.<sup>2</sup> This abscess broke and discharged its contents through an opening in the right auditory canal. From that time to the present there had been more or less discharge from the ear, but on the whole it had been diminishing in quantity. He had experienced no deafness with it, except temporarily, when the discharge filled the canal. About three months previously he had discovered a small fragment of bone in the discharge. On examination, I found a flattened, succulent mass of granulation tissue lying on the lower and posterior wall of the canal, apparently at the junction of the osseous with the cartilaginous portion. This mass, as I ascertained by careful probing, grew from the edge of a not very deep ulcer, at the bottom of which denuded bone was readily felt. A short distance beyond, in the osseous or membranous part of the canal, a second superficial ulcer was found. At all other points the canal presented an uninfamed and natural appearance. The membrana tympani also appeared to be normal.

Treatment was commenced on the 19th of April, and on the 29th, ten days later, the larger ulcer was found to be completely healed. The polypoid mass was first removed with the snare, and then the remaining raw surfaces were freely cauterized (daily) with nitrate of silver, fused upon the end of a cotton-holder. Five or six such cauterizations were made, and then the rapidly contracting ulcer was completely covered with pellets of powdered burned alum. After two or three such applications, complete cicatrization of the parts was found to have taken place. The more deeply situated, superficial ulcer, which seemed a very trifling affair in comparison with that which lay nearer to the

<sup>1</sup> That is, not developed by extension from a neighboring region.

<sup>2</sup> Parotid abscesses are said to be among the many very rare sequelæ of typhoid fever.

external orifice, proved the more rebellious of the two. In fact, it had not yet entirely healed on the 20th, when the boy returned to his home in the country. A few weeks later, however, he visited me again, and I then found that this ulcer too had completely healed, no further treatment having been carried on in the meantime.

If this case could have been seen from the very beginning, it would probably have been an easy matter to trace the connection between the parotid abscess and the superficial ulcer which was situated near the drum-membrane. In all probability the abscess did not break until it had kindled an acute inflammation of the entire lower and posterior wall of the osseous meatus. The outer ulcer probably represented the spot where the rupture finally took place, and the inner one a spot where the inflammation was more severe than at other points. At the time I saw the case, however, the isolated position of this ulcer, and the absence of any evidence of inflammation of the parts lying between it and the outer ulcer, added a certain element of mystery to the case.

In the second case, which was first seen on the 20th of November, 1877, the conditions observed were even more difficult to explain.

The patient, a very intelligent lady, thirty-eight years old, and in fairly good health, stated that during the previous five weeks she had experienced at times quite severe pain in the right ear. There had been no discharge, and very little disturbance of hearing, so far as general conversation was concerned. Her regular medical adviser had attributed the painful affection of the ear to impacted cerumen, and had syringed the canal very thoroughly with tepid water, but without beneficial effects. On examination, I found the orifice of the right auditory canal tender on pressure, and obstructed by the presence of a moderately large mass of granulation tissue springing from the mouth of a recently ruptured furuncle. Beyond this fleshy mass, which I at once removed with the snare, the canal was found to be tightly plugged with a whitish mass which felt as hard as chalk. By means of the curette and forceps I was able to break down and remove piecemeal the entire mass. It presented throughout every appearance of being a chalky substance, and probably represented a calcareous transformation of pus that had first undergone cheesy degeneration. (The patient belonged to a gouty family.) The inner end of the mass extended to within a few millimetres of the drum-membrane. After it had been entirely removed I found that the only lesion in the osseous part of the canal, beyond a moderate degree of redness and swelling, was a circumscribed ulcer, situated posteriorly and superiorly, not far from the junction of the osseous with the cartilaginous portion. On exploration with the probe, I ascertained that denuded bone surface constituted the base of the ulcer. The membrana tympani appeared to be perfectly normal.

An examination of the patient's left ear, which she had always supposed to be healthy in every respect, revealed the existence of a small, pale, succulent, polypoid mass, springing from the poste-

rior wall of the osseous canal, close to the drum-membrane. The secretion from this mass was so scanty that no fluid could be seen in the canal except in the immediate neighborhood of the growth. Exploration with the probe showed that the polypus was simply a superficial outgrowth, not connected with any demonstrable disease of the bone. The membrana tympani appeared to be perfectly natural, and there was no appreciable redness or swelling of the walls of the canal in the vicinity of the growth.

I questioned the patient carefully with regard to the condition of her ears in the past, but could elicit no information that threw any light upon the peculiar lesions found. The pain of which she had complained during the previous five weeks was evidently due to the development of a furuncle near the outer orifice, and the mass of granulation tissue found in this location was simply the effect of continued irritation from some source or other. These lesions were clearly of comparatively recent date. The presence of the calcareous mass in the right meatus pointed clearly to a discharge of much earlier date; but it was not so easy a matter to define the location from which this discharge came. The middle ear, for instance, could safely be excluded as a source of the pus, as the patient was positive that she had never experienced any pain or discomfort in the right ear until recently, and also because the condition of the drum-membrane, as found after the chalky mass had been removed, showed no trace of any recent or former inflammation of the middle ear. The discharge, therefore, in all probability, came from the auditory canal. The patient, however, it will be remembered, stated distinctly that she had never observed a discharge from either ear. In explanation of this apparently contradictory state of things, the assumption seems almost unavoidable that in the outer portion of the canal there must have been some obstacle which prevented the escape of the pus secreted in the inner portion. Impacted cerumen would present such an obstacle, and, by greatly diminishing the rate of evaporation which would take place in the pus under ordinary circumstances (*i. e.*, in an unobstructed meatus), would favor its gradual accumulation and slow transformation first into a cheesy and then into a chalky mass. No cerumen, it is true, was found in the canal at the time I examined it; but it is more than probable that the thorough syringing which the ear had received at the hands of the attending physician had removed all that was there.

The question relating to the exact source of this assumed discharge—whether the latter came from the circumscribed ulcer described above, or from some previous diffuse inflammation, of which this ulcer was the last remaining trace—is one which I am unable to answer. With regard to the treatment and subsequent

## DISEASES OF THE EXTERNAL AUDITORY CANAL. 91

progress of the case, there is very little of interest to communicate. Both ulcers healed slowly under the use of nitrate of silver (in the form of a bead) and (later) powdered iodoform. A dry eczema, affecting the orifices of the canals, continued for several weeks after the ulcers had healed, and then itself finally disappeared. As late as during the summer of 1879 I found both canals still quite natural in appearance.

In the foregoing cases the bony structure of the meatus was involved to only a very slight degree, and after the ulcer had healed no irregularity of the surface remained to indicate the spot which it had recently occupied. In the following cases the disease of the bone constitutes a more prominent characteristic. In common with the case last described, however, they both were seen for the first time only after they had reached a more or less advanced stage of development. Neither the condition of the parts nor the patients' own statements furnished the slightest clew to the antecedent pathology of the disease.

The first of these cases was seen at the N. Y. Eye and Ear Infirmary on the 25th of October, 1871. The patient, a healthy man, twenty-two years of age, sought relief at the institution on account of an acute affection of the left ear. As a matter of routine, I also examined the right ear, of which the patient had made no complaint, and found the canal blocked by a large and hard plug of cerumen. After the mass had been extracted, I discovered that a ridge of bone, about two millimetres high, crossed the lower wall of the osseous canal, at right angles to its long axis, and only a short distance from the line of junction of the cartilaginous and osseous portions. Along its sides this ridge was covered with small, soft granulations. Quite firm pressure with the probe failed to break off any portion of the irregular, free edge of the ridge. The drum-membrane showed only insignificant changes, and there was simply moderate redness of the canal in the neighborhood of the carious region. The watch was heard at distance of six feet. No evidences of syphilis could be found, and the patient was very positive that he had never had a discharge from the right ear, and had never experienced pain in it. (The patient was seen again only once, a few days later.)

The second case was seen on the 17th of March, 1873. The patient, a strong, healthy man, of fifty years of age, consulted me for a slight diminution in the acuteness of his hearing. On examination, I found both canals filled with cerumen. The impacted masses were removed, and the patient obtained the desired relief.

On the 23d of June he consulted me a second time, and on examination I was surprised to find that the canals were again obstructed with the same material, though in smaller quantity. The removal of the impacted masses again afforded the desired relief.

On the 26th of July the patient consulted me for the third time. The right ear, he said, had felt full, and at times he had experienced pain in it. On examination, very little cerumen was found in the outer portion of the canal, but in the immediate



vicinity of the membrana tympani there was a small mass of what appeared to be cerumen. As this mass was firmly impacted in the anterior cul-de-sac, between the drum-membrane and the wall of the canal, I instructed the patient to use instillations of a warm solution of bicarbonate of soda for two or three days, and then to let me examine the ear again. This he did, and when I afterward saw him, I found no difficulty in syringing out the accumulated material. An inspection of the canal then revealed the fact that an irregularly shaped body still occupied the extreme inner end of the meatus; part of it, in fact, seemed to be touching the membrana tympani. The free surface of this mass was made up of three or four jagged elevations, which felt like bone when they were touched with the probe. One of them was so prominent that I found no difficulty in seizing it firmly with the forceps. It was perfectly immovable, however, and there could therefore no longer be any reasonable doubt that this jagged ridge was in reality an exostosis or hyperostosis associated with a limited ulcerative process or caries; the material which I had last syringed out being in all probability hardened pus which had accumulated around the bony mass. The membrana tympani was moderately thickened and opaque, but free from all other evidences of old or recent inflammation. The ticking of the watch was heard at a distance of two feet on the right side, and four feet on the left. Careful inquiry into the patient's past history failed to throw any light upon the origin of this local caries of the meatus. The left ear was not examined.

On the 4th of September, 1874, I again saw the patient. He said that he had experienced no unpleasant sensations in either ear until a short time previously, when a slight discharge developed in both ears. On examination I found that the carious spot in the right meatus was covered with foul and cheesy pus, and that almost the same lesion existed in the left canal. In both ears the carious spot was situated on the lower wall of the meatus, close to the drum-membrane, and on both sides the spots were of about the same size.

On the 14th of November, 1876, the patient reported that during the previous summer he had experienced two or three attacks of moderately severe pain in the left ear, accompanied by a discharge of foul matter. At about the same time he had found two small fragments of bone in the discharge. The right ear had given him no trouble, though on one or two occasions he had noticed a slight discharge from it. On examination I found that the carious excavation in the left ear had increased decidedly in extent, and that a ridge of newly formed bone, about two millimetres in height, traversed the canal along the inner limit of the ulcer, and in close proximity to the membrana tympani. A very foul, dark pus covered the region of the ulcer. On the right side no material change could be made out in the condition of the ear.

The subsequent treatment consisted simply in the regular use of the warm douche, for the purpose of removing the foul pus from the canal; the patient being unwilling to submit to any more systematic efforts to induce permanent healing of the carious spots, especially as I could not promise to him successful results.

The thought of syphilis suggested itself to my mind, as soon as I discovered that both osseous canals were symmetrically dis-

eased; but the patient's ruddy countenance and splendid physique, his age, his high social standing, and the absence of any other evidence of constitutional syphilis, made me look upon this disease as a very improbable cause of the peculiar lesions described above. The only hypothesis which I can offer in place of the syphilitic one, is that which represents these lesions as being the sequelæ of a double otitis media that ran its course during the patient's infancy or childhood, but of which all traces had long before disappeared.

In the following case, which deserves the title of *primary caries of the osseous portion of the external auditory canal* more fully than does any case that I have ever seen, the exact pathology or mode of development of the disease is by no means clear.

The patient, a healthy woman about thirty-five years of age, a member of one of the sisterhoods of the Episcopal Church in this city, consulted me on the 9th of June, 1880, for the purpose of having a "tumor" removed from the left ear. The only history that she could give was this: About three weeks previously she experienced a slight pain in the left ear, and a few hours later she noticed that there was a slight discharge from the ear. She paid very little attention to the discharge, as it was very slight and gave her no special annoyance. Two or three days before she came to see me, she noticed that her hearing had rather suddenly become impaired; and on examining the ear to ascertain what might be the cause of it, she discovered that the outer orifice was nearly closed by a red, fleshy mass. Thinking that she might have made light of the degree of pain experienced at the beginning of the disease, I questioned her very closely on this point. She was very positive, however, that she had experienced only a few twinges of pain at intervals during a part of one day, and these twinges, she said, were almost too trivial to deserve the name of pain. The hearing, so far as she knew, had always been perfect up to the time referred to above. On examination, I found the outer orifice blocked by a red, moist, firm, fleshy mass which sprang by a broad base from the lower and posterior wall of the meatus, a very short distance outside the line of junction of the cartilaginous with the osseous portion of the canal. From the firmness of the mass, from its uneven surface, from the painless manner in which it had developed, and from its rapidity of growth, I was at first disposed to consider it as a cancerous growth; but after I had cut it off flush with the level of the surrounding healthy skin—a procedure which caused her very little pain—I observed that a canal ran through the centre of the tumor, from its base to its summit, and I at once abandoned the idea of a cancer. These hollow tumors, in my experience, grow only from the mouth of an abscess, be the latter simply furuncular in its nature, or of deeper origin (dependent on bone caries). In the present case, the introduction of a curved probe revealed the existence of a limited area of exposed bone, which felt like the free outer edge of the osseous meatus. The drum-membrane and the inner half of the external auditory canal seemed to be normal, and the removal of the growth restored the hearing perfectly.

On the 20th of June, after fruitless efforts to arrest the growth

by means of nitric acid, I again resorted to the use of the knife. I took this step because the fleshy mass had again nearly filled the orifice of the auditory canal, and therefore threatened to diminish the patient's hearing power during her vacation, which she was then about to take.

On the 16th of July she returned to the city, and reported that during the first two or three days of the month her ear became very much swollen, below and behind the meatus; and while it was in this condition she discovered, at the orifice of the canal, in wiping it out, a small fragment of bone. The swelling then rapidly subsided, the discharge ceased, and the ear seemed to her to return to a perfectly natural condition. The only trace of the former disease that I could find, when I examined the ear, was a small nodular cicatrix, at the spot where the granulation-tissue had previously existed.

It would be extremely interesting to know what were the precise changes that led to the limited death of the bone in this case, but unfortunately we can only speculate with regard to their nature. The almost entire absence of pain during the incipient stage of the disease, coupled with the fact that a separation was found to have taken place between the projecting end of the bone and the cartilaginous framework of the auditory canal, suggests the possibility of a change akin to chondromalacia (see p. 46) as the starting-point of the entire series of morbid phenomena.

In all the five cases described in the present section, the lesions observed in the auditory canal presented every appearance of being primary in their nature, or, at all events, independent of any recognizable disease of the middle ear.

*False membranes.*--These formations, which are only very rarely encountered in the external auditory canal, are probably always due to some of the secondary effects of an inflammation of the middle ear. If they are seen for the first time in a case in which all other evidences of the middle-ear disease have disappeared, there may be some difficulty in understanding their true nature and origin; but it is a very easy matter to understand the pathology of these formations when we have the opportunity of actually witnessing the different stages of their development, as was my good fortune in two of the cases now about to be narrated.

The first case furnishes an instance of the development of a *cord-like bridge of flesh in the auditory canal.*

The patient, a female, twenty-five years of age, and in good general health, presented herself for treatment at the New York Eye and Ear Infirmary, on the 30th of August, 1871. She stated that there had been a discharge from the left ear during the previous three years. On examination I found the outer orifice filled with a polypoid growth. With Blake's snare I then removed in succession four distinct polypoid masses, all of them growing from the walls of the auditory canal, and not connected, so far as I could discover, with carious bone.

On the 6th of September I saw the patient a second time, and found that the stumps of the polypi removed on the 25th of August had already markedly increased in size. I used the snare a second time, and cauterized the remaining raw surfaces with nitrate of silver.

On the 23d of September I examined the ear again and discovered that two of the stumps—situated opposite to each other, one on the upper, the other on the lower wall of the meatus—had coalesced so as to form a distinct cord-like bridge of flesh, stretching from the upper to the lower wall of the meatus. Moderate stretching of this band with the probe failed to produce a rupture, and, being anxious to see whether it would shrivel up and disappear of itself, or what would become of it, I abstained from any further interference, and simply advised the patient to syringe the ear daily with lukewarm water.

On the 4th of October I found that the fleshy band had perceptibly diminished in diameter. There was also very little discharge.

On the 6th of December I found that the discharge had ceased entirely, and that the walls of the meatus were perfectly dry. The fleshy band had diminished to the proportions of a slender cord scarcely one millimetre in diameter; and when touched with the probe it felt dry and stiff, as if it were made of parchment. The mass of granulation-tissue had undoubtedly become completely covered with epidermis, and then the process of contraction, which is common to all newly formed connective tissue as soon as suppuration ceases, had reduced its proportions to those of a slender cord.' (The patient did not subsequently return.)

In another case I had an opportunity of watching the same series of pathological changes take place on a much larger scale.

The patient, a rather dull boy of twelve, was brought to the New York Eye and Ear Infirmary by his parents, on the 9th of July, 1873. Three years previously he had passed through an attack of scarlet fever, but no discharge from the ear had been noticed until a short time before his visit to the Infirmary. On examination, I found the entrance to the canal blocked by quite a large mass of granulation-tissue. The removal of this mass by means of Blake's snare brought to view a dark body, which felt hard when touched with the probe, and seemed to be tightly wedged in between the anterior and posterior walls of the canal. Steady traction, by means of a steel hook introduced flatwise between the foreign body and the upper wall of the meatus, and then turned point downward as soon as the inner end of the hard mass had been reached, brought it away entire. It proved to be a prune-pit of moderate size. Neither the boy nor his parents could account for its presence in the ear. That portion of the meatus in which the greatest breadth of the pit lay seemed to be larger than the natural size, while just beyond and just this side of the dilated portion the soft parts of the canal appeared to be swollen.

Nine days later I saw the patient a second time. The inner limit of the dilated portion—corresponding to the junction of the inner and middle thirds of the osseous part of the canal—was

<sup>1</sup> Dr. George T. Engleman, of St. Louis, has reported a very similar case in the *Archiv für Ohrenheilkunde*, vol. vi., p. 203.



then the seat of a ring-shaped mass of granulation-tissue, which encroached very decidedly upon the calibre of the meatus.

Sixteen days later still (August 4th), I found the calibre of the canal almost obliterated by this mass. Although the probe could still be passed through the centre of the obstructing granulations, the appearance presented was as if the calibre of the canal had been completely obliterated at this point.

During the following week three applications of chromic acid (in crystalline form) were made to the central portion of the mass. This caustic, however, set up so much inflammation that I was obliged to abandon its use. The boy was not seen again until the 2d of September. The canal was then found to be perfectly dry, and the patient said that the discharge had ceased several days previously. The ring-shaped mass of granulation-tissue had become transformed into a solid *cul-de-sac*, completely obliterating the calibre of the canal. The tissues were dry, smooth and firm, and no longer resembled granulation-tissue. In the centre of the mass, a small scab, about the size of the head of a pin, was visible. After this had been torn off, the probe could readily be pushed through to the broad part of the canal beyond.

Efforts at dilatation, by means of small laminaria bougies, were kept up during the following two or three days, but they caused considerable pain and proved of no avail. On the 28th of September fuming nitric acid was freely applied to the centre of the mass. The pain caused by this application was only moderate.

On the 4th of October I found that the acid had made quite a free opening in the mass. The application was not repeated, and yet the tissues forming the annular constriction continued to contract (centrifugally), and the calibre of the canal to enlarge, until, on the 22d of November, when I saw the boy for the last time, very little trace remained of the mass,—which, if it had been left to itself, would undoubtedly have formed a permanent obstruction in the canal, in the shape of a diaphragm or false membrane. The discharge, which made its appearance soon after the application of the acid, had entirely ceased. Beyond the narrowed portion of the canal, which was very near its inner limit, the membrana tympani was plainly visible. Its lower half was perforated near the centre.

The following case completes the picture which nitric acid spoiled in the preceding case :

The patient, a female, twenty-six years of age, consulted me at the New York Eye and Ear Infirmary, on December 1, 1873. She had been somewhat hard of hearing all her life. In childhood there had been a discharge from both ears, but during recent years there had not been any from the right one. In this ear the watch was heard only when pressed firmly against it. The left ear presented the ordinary appearance of an uncomplicated chronic purulent inflammation of the middle ear. An examination of the right ear revealed the following condition : the meatus was normal ; at its inner end it terminated in a smooth, parchment-like membrane, of uniform but slight concavity outwardly, and looking very much like a membrana tympani from which the malleus had been removed. When tapped with the probe this membrane gave forth quite a loud sound, such as is heard when a stiff piece of parchment is bent. It appeared to be considerably thicker than the normal drum-membrane, and, at every

point of the periphery, passed without the slightest break or irregularity into the skin of the auditory canal. A superficial observer might very readily, I think, have taken this strange diaphragm for the membrana tympani. Its greater proximity to the external orifice, however, and the absence of the handle of the hammer, showed almost conclusively that, notwithstanding its dry, membranous character, it was not the drum-membrane, but a new-formation of some kind.

So far as its influence upon the hearing was concerned, such a membranous diaphragm could only act as an obstacle. I therefore had no hesitation in making a free crucial incision through it. The angular flaps thus made showed very little disposition to retract. They were readily bent over toward the walls of the meatus, however, and thus a view of the deeper structures was obtained through the irregular opening. All that could be seen at that time was the red and moist mucous membrane of the promontory, situated about four or five millimetres beyond the plane of the false membrane. As an evidence of the vitality of the latter, I might mention the fact that, a very few minutes after the incisions had been made, a glistening border of bloody serum was noticed along each of the cut edges of the angular flaps. The improvement then observed in the hearing, at least for conversation, was quite marked; for the watch, the hearing distance was increased to four inches.

At the next visit, a week later, the patient reported that there had been a constant discharge from the right ear since the day following the operation. The perforation was then circular in shape, from three to four millimetres in diameter, and through it the relations of the deeper parts could be distinctly made out. It was thus ascertained that the handle of the hammer was still entire, though adherent to and covered up at its tip by the tissues of the promontory. The short process of this ossicle could be distinctly recognized at the inner edge of the base of the false membrane.

When last seen the patient still complained of a slight mucopurulent discharge, and no marked change had taken place in the condition of the parts.

The two preceding cases throw light each one upon the other. In that of the boy, for example, there can hardly be any reasonable doubt that if I had not interfered vigorously with nitric acid, a false membrane or diaphragm, similar in every respect to that which was observed in the case of the woman, would have developed at the seat of the constriction. On the other hand, had I not previously watched the peculiar behavior of the granulation-tissue in the boy's case, and also in that of the first case (p. 94), I might have experienced difficulty in explaining the presence of such a parchment-like diaphragm in the osseous portion of the auditory canal. In all three cases the different steps of the process were essentially the same. Under the stimulus of some irritating cause, granulation tissue was produced. Two granulating surfaces met at a time when there was not a sufficient current of fluid secretion to prevent them from uniting, and they accordingly united into a single mass. The original irri-

rior wall of the osseous canal, close to the drum-membrane. The secretion from this mass was so scanty that no fluid could be seen in the canal except in the immediate neighborhood of the growth. Exploration with the probe showed that the polypus was simply a superficial outgrowth, not connected with any demonstrable disease of the bone. The membrana tympani appeared to be perfectly natural, and there was no appreciable redness or swelling of the walls of the canal in the vicinity of the growth.

I questioned the patient carefully with regard to the condition of her ears in the past, but could elicit no information that threw any light upon the peculiar lesions found. The pain of which she had complained during the previous five weeks was evidently due to the development of a furuncle near the outer orifice, and the mass of granulation tissue found in this location was simply the effect of continued irritation from some source or other. These lesions were clearly of comparatively recent date. The presence of the calcareous mass in the right meatus pointed clearly to a discharge of much earlier date; but it was not so easy a matter to define the location from which this discharge came. The middle ear, for instance, could safely be excluded as a source of the pus, as the patient was positive that she had never experienced any pain or discomfort in the right ear until recently, and also because the condition of the drum-membrane, as found after the chalky mass had been removed, showed no trace of any recent or former inflammation of the middle ear. The discharge, therefore, in all probability, came from the auditory canal. The patient, however, it will be remembered, stated distinctly that she had never observed a discharge from either ear. In explanation of this apparently contradictory state of things, the assumption seems almost unavoidable that in the outer portion of the canal there must have been some obstacle which prevented the escape of the pus secreted in the inner portion. Impacted cerumen would present such an obstacle, and, by greatly diminishing the rate of evaporation which would take place in the pus under ordinary circumstances (*i. e.*, in an unobstructed meatus), would favor its gradual accumulation and slow transformation first into a cheesy and then into a chalky mass. No cerumen, it is true, was found in the canal at the time I examined it; but it is more than probable that the thorough syringing which the ear had received at the hands of the attending physician had removed all that was there.

The question relating to the exact source of this assumed discharge—whether the latter came from the circumscribed ulcer described above, or from some previous diffuse inflammation, of which this ulcer was the last remaining trace—is one which I am unable to answer. With regard to the treatment and subsequent

## DISEASES OF THE EXTERNAL AUDITORY CANAL. 91

progress of the case, there is very little of interest to communicate. Both ulcers healed slowly under the use of nitrate of silver (in the form of a bead) and (later) powdered iodoform. A dry eczema, affecting the orifices of the canals, continued for several weeks after the ulcers had healed, and then itself finally disappeared. As late as during the summer of 1879 I found both canals still quite natural in appearance.

In the foregoing cases the bony structure of the meatus was involved to only a very slight degree, and after the ulcer had healed no irregularity of the surface remained to indicate the spot which it had recently occupied. In the following cases the disease of the bone constitutes a more prominent characteristic. In common with the case last described, however, they both were seen for the first time only after they had reached a more or less advanced stage of development. Neither the condition of the parts nor the patients' own statements furnished the slightest clew to the antecedent pathology of the disease.

The first of these cases was seen at the N. Y. Eye and Ear Infirmary on the 25th of October, 1871. The patient, a healthy man, twenty-two years of age, sought relief at the institution on account of an acute affection of the left ear. As a matter of routine, I also examined the right ear, of which the patient had made no complaint, and found the canal blocked by a large and hard plug of cerumen. After the mass had been extracted, I discovered that a ridge of bone, about two millimetres high, crossed the lower wall of the osseous canal, at right angles to its long axis, and only a short distance from the line of junction of the cartilaginous and osseous portions. Along its sides this ridge was covered with small, soft granulations. Quite firm pressure with the probe failed to break off any portion of the irregular, free edge of the ridge. The drum-membrane showed only insignificant changes, and there was simply moderate redness of the canal in the neighborhood of the carious region. The watch was heard at distance of six feet. No evidences of syphilis could be found, and the patient was very positive that he had never had a discharge from the right ear, and had never experienced pain in it. (The patient was seen again only once, a few days later.)

The second case was seen on the 17th of March, 1873. The patient, a strong, healthy man, of fifty years of age, consulted me for a slight diminution in the acuteness of his hearing. On examination, I found both canals filled with cerumen. The impacted masses were removed, and the patient obtained the desired relief.

On the 23d of June he consulted me a second time, and on examination I was surprised to find that the canals were again obstructed with the same material, though in smaller quantity. The removal of the impacted masses again afforded the desired relief.

On the 26th of July the patient consulted me for the third time. The right ear, he said, had felt full, and at times he had experienced pain in it. On examination, very little cerumen was found in the outer portion of the canal, but in the immediate



vicinity of the membrana tympani there was a small mass of what appeared to be cerumen. As this mass was firmly impacted in the anterior cul-de-sac, between the drum-membrane and the wall of the canal, I instructed the patient to use instillations of a warm solution of bicarbonate of soda for two or three days, and then to let me examine the ear again. This he did, and when I afterward saw him, I found no difficulty in syringing out the accumulated material. An inspection of the canal then revealed the fact that an irregularly shaped body still occupied the extreme inner end of the meatus; part of it, in fact, seemed to be touching the membrana tympani. The free surface of this mass was made up of three or four jagged elevations, which felt like bone when they were touched with the probe. One of them was so prominent that I found no difficulty in seizing it firmly with the forceps. It was perfectly immovable, however, and there could therefore no longer be any reasonable doubt that this jagged ridge was in reality an exostosis or hyperostosis associated with a limited ulcerative process or caries; the material which I had last syringed out being in all probability hardened pus which had accumulated around the bony mass. The membrana tympani was moderately thickened and opaque, but free from all other evidences of old or recent inflammation. The ticking of the watch was heard at a distance of two feet on the right side, and four feet on the left. Careful inquiry into the patient's past history failed to throw any light upon the origin of this local caries of the meatus. The left ear was not examined.

On the 4th of September, 1874, I again saw the patient. He said that he had experienced no unpleasant sensations in either ear until a short time previously, when a slight discharge developed in both ears. On examination I found that the carious spot in the right meatus was covered with foul and cheesy pus, and that almost the same lesion existed in the left canal. In both ears the carious spot was situated on the lower wall of the meatus, close to the drum-membrane, and on both sides the spots were of about the same size.

On the 14th of November, 1876, the patient reported that during the previous summer he had experienced two or three attacks of moderately severe pain in the left ear, accompanied by a discharge of foul matter. At about the same time he had found two small fragments of bone in the discharge. The right ear had given him no trouble, though on one or two occasions he had noticed a slight discharge from it. On examination I found that the carious excavation in the left ear had increased decidedly in extent, and that a ridge of newly formed bone, about two millimetres in height, traversed the canal along the inner limit of the ulcer, and in close proximity to the membrana tympani. A very foul, dark pus covered the region of the ulcer. On the right side no material change could be made out in the condition of the ear.

The subsequent treatment consisted simply in the regular use of the warm douche, for the purpose of removing the foul pus from the canal; the patient being unwilling to submit to any more systematic efforts to induce permanent healing of the carious spots, especially as I could not promise to him successful results.

The thought of syphilis suggested itself to my mind, as soon as I discovered that both osseous canals were symmetrically dis-

eased; but the patient's ruddy countenance and splendid physique, his age, his high social standing, and the absence of any other evidence of constitutional syphilis, made me look upon this disease as a very improbable cause of the peculiar lesions described above. The only hypothesis which I can offer in place of the syphilitic one, is that which represents these lesions as being the sequelæ of a double otitis media that ran its course during the patient's infancy or childhood, but of which all traces had long before disappeared.

In the following case, which deserves the title of *primary caries of the osseous portion of the external auditory canal* more fully than does any case that I have ever seen, the exact pathology or mode of development of the disease is by no means clear.

The patient, a healthy woman about thirty-five years of age, a member of one of the sisterhoods of the Episcopal Church in this city, consulted me on the 9th of June, 1880, for the purpose of having a "tumor" removed from the left ear. The only history that she could give was this: About three weeks previously she experienced a slight pain in the left ear, and a few hours later she noticed that there was a slight discharge from the ear. She paid very little attention to the discharge, as it was very slight and gave her no special annoyance. Two or three days before she came to see me, she noticed that her hearing had rather suddenly become impaired; and on examining the ear to ascertain what might be the cause of it, she discovered that the outer orifice was nearly closed by a red, fleshy mass. Thinking that she might have made light of the degree of pain experienced at the beginning of the disease, I questioned her very closely on this point. She was very positive, however, that she had experienced only a few twinges of pain at intervals during a part of one day, and these twinges, she said, were almost too trivial to deserve the name of pain. The hearing, so far as she knew, had always been perfect up to the time referred to above. On examination, I found the outer orifice blocked by a red, moist, firm, fleshy mass which sprang by a broad base from the lower and posterior wall of the meatus, a very short distance outside the line of junction of the cartilaginous with the osseous portion of the canal. From the firmness of the mass, from its uneven surface, from the painless manner in which it had developed, and from its rapidity of growth, I was at first disposed to consider it as a cancerous growth; but after I had cut it off flush with the level of the surrounding healthy skin—a procedure which caused her very little pain—I observed that a canal ran through the centre of the tumor, from its base to its summit, and I at once abandoned the idea of a cancer. These hollow tumors, in my experience, grow only from the mouth of an abscess, be the latter simply furuncular in its nature, or of deeper origin (dependent on bone caries). In the present case, the introduction of a curved probe revealed the existence of a limited area of exposed bone, which felt like the free outer edge of the osseous meatus. The drum-membrane and the inner half of the external auditory canal seemed to be normal, and the removal of the growth restored the hearing perfectly.

On the 20th of June, after fruitless efforts to arrest the growth

by means of nitric acid, I again resorted to the use of the knife. I took this step because the fleshy mass had again nearly filled the orifice of the auditory canal, and therefore threatened to diminish the patient's hearing power during her vacation, which she was then about to take.

On the 16th of July she returned to the city, and reported that during the first two or three days of the month her ear became very much swollen, below and behind the meatus; and while it was in this condition she discovered, at the orifice of the canal, in wiping it out, a small fragment of bone. The swelling then rapidly subsided, the discharge ceased, and the ear seemed to her to return to a perfectly natural condition. The only trace of the former disease that I could find, when I examined the ear, was a small nodular cicatrix, at the spot where the granulation-tissue had previously existed.

It would be extremely interesting to know what were the precise changes that led to the limited death of the bone in this case, but unfortunately we can only speculate with regard to their nature. The almost entire absence of pain during the incipient stage of the disease, coupled with the fact that a separation was found to have taken place between the projecting end of the bone and the cartilaginous framework of the auditory canal, suggests the possibility of a change akin to chondromalacia (see p. 46) as the starting-point of the entire series of morbid phenomena.

In all the five cases described in the present section, the lesions observed in the auditory canal presented every appearance of being primary in their nature, or, at all events, independent of any recognizable disease of the middle ear.

*Pulse membranes.*—These formations, which are only very rarely encountered in the external auditory canal, are probably always due to some of the secondary effects of an inflammation of the middle ear. If they are seen for the first time in a case in which all other evidences of the middle-ear disease have disappeared, there may be some difficulty in understanding their true nature and origin; but it is a very easy matter to understand the pathology of these formations when we have the opportunity of actually witnessing the different stages of their development, as was my good fortune in two of the cases now about to be narrated.

The first case furnishes an instance of the development of a *cord-like bridge of flesh in the auditory canal.*

The patient, a female, twenty-five years of age, and in good general health, presented herself for treatment at the New York Eye and Ear Infirmary, on the 30th of August, 1871. She stated that there had been a discharge from the left ear during the previous three years. On examination I found the outer orifice filled with a polypoid growth. With Blake's snare I then removed in succession four distinct polypoid masses, all of them growing from the walls of the auditory canal, and not connected, so far as I could discover, with carious bone.

On the 6th of September I saw the patient a second time, and found that the stumps of the polypi removed on the 25th of August had already markedly increased in size. I used the snare a second time, and cauterized the remaining raw surfaces with nitrate of silver.

On the 23d of September I examined the ear again and discovered that two of the stumps—situated opposite to each other, one on the upper, the other on the lower wall of the meatus—had coalesced so as to form a distinct cord-like bridge of flesh, stretching from the upper to the lower wall of the meatus. Moderate stretching of this band with the probe failed to produce a rupture, and, being anxious to see whether it would shrivel up and disappear of itself, or what would become of it, I abstained from any further interference, and simply advised the patient to syringe the ear daily with lukewarm water.

On the 4th of October I found that the fleshy band had perceptibly diminished in diameter. There was also very little discharge.

On the 6th of December I found that the discharge had ceased entirely, and that the walls of the meatus were perfectly dry. The fleshy band had diminished to the proportions of a slender cord scarcely one millimetre in diameter; and when touched with the probe it felt dry and stiff, as if it were made of parchment. The mass of granulation-tissue had undoubtedly become completely covered with epidermis, and then the process of contraction, which is common to all newly formed connective tissue as soon as suppuration ceases, had reduced its proportions to those of a slender cord.<sup>1</sup> (The patient did not subsequently return.)

In another case I had an opportunity of watching the same series of pathological changes take place on a much larger scale.

The patient, a rather dull boy of twelve, was brought to the New York Eye and Ear Infirmary by his parents, on the 9th of July, 1873. Three years previously he had passed through an attack of scarlet fever, but no discharge from the ear had been noticed until a short time before his visit to the Infirmary. On examination, I found the entrance to the canal blocked by quite a large mass of granulation-tissue. The removal of this mass by means of Blake's snare brought to view a dark body, which felt hard when touched with the probe, and seemed to be tightly wedged in between the anterior and posterior walls of the canal. Steady traction, by means of a steel hook introduced flatwise between the foreign body and the upper wall of the meatus, and then turned point downward as soon as the inner end of the hard mass had been reached, brought it away entire. It proved to be a prune-pit of moderate size. Neither the boy nor his parents could account for its presence in the ear. That portion of the meatus in which the greatest breadth of the pit lay seemed to be larger than the natural size, while just beyond and just this side of the dilated portion the soft parts of the canal appeared to be swollen.

Nine days later I saw the patient a second time. The inner limit of the dilated portion—corresponding to the junction of the inner and middle thirds of the osseous part of the canal—was

<sup>1</sup> Dr. George T. Engelman, of St. Louis, has reported a very similar case in the *Archiv für Ohrenheilkunde*, vol. vi., p. 203.



then the seat of a ring-shaped mass of granulation-tissue, which encroached very decidedly upon the calibre of the meatus.

Sixteen days later still (August 4th), I found the calibre of the canal almost obliterated by this mass. Although the probe could still be passed through the centre of the obstructing granulations, the appearance presented was as if the calibre of the canal had been completely obliterated at this point.

During the following week three applications of chromic acid (in crystalline form) were made to the central portion of the mass. This caustic, however, set up so much inflammation that I was obliged to abandon its use. The boy was not seen again until the 2d of September. The canal was then found to be perfectly dry, and the patient said that the discharge had ceased several days previously. The ring-shaped mass of granulation-tissue had become transformed into a solid *cul-de-sac*, completely obliterating the calibre of the canal. The tissues were dry, smooth and firm, and no longer resembled granulation-tissue. In the centre of the mass, a small scab, about the size of the head of a pin, was visible. After this had been torn off, the probe could readily be pushed through to the broad part of the canal beyond.

Efforts at dilatation, by means of small laminaria bougies, were kept up during the following two or three days, but they caused considerable pain and proved of no avail. On the 28th of September fuming nitric acid was freely applied to the centre of the mass. The pain caused by this application was only moderate.

On the 4th of October I found that the acid had made quite a free opening in the mass. The application was not repeated, and yet the tissues forming the annular constriction continued to contract (centrifugally), and the calibre of the canal to enlarge, until, on the 23d of November, when I saw the boy for the last time, very little trace remained of the mass,—which, if it had been left to itself, would undoubtedly have formed a permanent obstruction in the canal, in the shape of a diaphragm or false membrane. The discharge, which made its appearance soon after the application of the acid, had entirely ceased. Beyond the narrowed portion of the canal, which was very near its inner limit, the membrana tympani was plainly visible. Its lower half was perforated near the centre.

The following case completes the picture which nitric acid spoiled in the preceding case :

The patient, a female, twenty-six years of age, consulted me at the New York Eye and Ear Infirmary, on December 1, 1873. She had been somewhat hard of hearing all her life. In childhood there had been a discharge from both ears, but during recent years there had not been any from the right one. In this ear the watch was heard only when pressed firmly against it. The left ear presented the ordinary appearance of an uncomplicated chronic purulent inflammation of the middle ear. An examination of the right ear revealed the following condition : the meatus was normal ; at its inner end it terminated in a smooth, parchment-like membrane, of uniform but slight concavity outwardly, and looking very much like a membrana tympani from which the malleus had been removed. When tapped with the probe this membrane gave forth quite a loud sound, such as is heard when a stiff piece of parchment is bent. It appeared to be considerably thicker than the normal drum-membrane, and, at every

point of the periphery, passed without the slightest break or irregularity into the skin of the auditory canal. A superficial observer might very readily, I think, have taken this strange diaphragm for the membrana tympani. Its greater proximity to the external orifice, however, and the absence of the handle of the hammer, showed almost conclusively that, notwithstanding its dry, membranous character, it was not the drum-membrane, but a new-formation of some kind.

So far as its influence upon the hearing was concerned, such a membranous diaphragm could only act as an obstacle. I therefore had no hesitation in making a free crucial incision through it. The angular flaps thus made showed very little disposition to retract. They were readily bent over toward the walls of the meatus, however, and thus a view of the deeper structures was obtained through the irregular opening. All that could be seen at that time was the red and moist mucous membrane of the promontory, situated about four or five millimetres beyond the plane of the false membrane. As an evidence of the vitality of the latter, I might mention the fact that, a very few minutes after the incisions had been made, a glistening border of bloody serum was noticed along each of the cut edges of the angular flaps. The improvement then observed in the hearing, at least for conversation, was quite marked; for the watch, the hearing distance was increased to four inches.

At the next visit, a week later, the patient reported that there had been a constant discharge from the right ear since the day following the operation. The perforation was then circular in shape, from three to four millimetres in diameter, and through it the relations of the deeper parts could be distinctly made out. It was thus ascertained that the handle of the hammer was still entire, though adherent to and covered up at its tip by the tissues of the promontory. The short process of this ossicle could be distinctly recognized at the inner edge of the base of the false membrane.

When last seen the patient still complained of a slight mucopurulent discharge, and no marked change had taken place in the condition of the parts.

The two preceding cases throw light each one upon the other. In that of the boy, for example, there can hardly be any reasonable doubt that if I had not interfered vigorously with nitric acid, a false membrane or diaphragm, similar in every respect to that which was observed in the case of the woman, would have developed at the seat of the constriction. On the other hand, had I not previously watched the peculiar behavior of the granulation-tissue in the boy's case, and also in that of the first case (p. 94), I might have experienced difficulty in explaining the presence of such a parchment-like diaphragm in the osseous portion of the auditory canal. In all three cases the different steps of the process were essentially the same. Under the stimulus of some irritating cause, granulation tissue was produced. Two granulating surfaces met at a time when there was not a sufficient current of fluid secretion to prevent them from uniting, and they accordingly united into a single mass. The original irri-



#### DISEASES OF THE EXTERNAL AUDITORY CANAL. 99

paracentesis of the membrana tympani has observed how from day to day the scab resulting from his incision moves from its original situation in the posterior half of the membrane, midway between the umbo and the periphery, toward the latter, and eventually, in its outward course, leaves the drum-membrane entirely.

The same motion has been observed in the external auditory canal in the immediate vicinity of the membrana tympani. Dr. Clarence J. Blake, of Boston, in a paper published in the *American Journal of Otology*, speaks of this motion as taking place in a spiral direction. Dr. C. H. Burnett, in his "Treatise on the Ear" (p. 46), speaks of this outward movement of the skin of the external auditory canal as affording an explanation of the way in which the superabundant cerumen is extruded from the canal. This surface movement, then, of the epidermis of the drum-membrane and external auditory canal, furnishes, I believe, an explanation of the presence—in the case narrated above—of a cuticle-like, membranous diaphragm in the outer canal of the ear. This membrane, according to this theory, would represent a desquamation—probably the result of an acute congestion of the parts—of the entire epidermal coat of the drum-membrane. That part of the cuticle of the membrana tympani which had separated from the underlying living epithelial cells must, in the present instance, have retained (at all points of the circumference) its connections with the neighboring healthy cuticle of the external auditory canal. The surface motion known to exist in the cuticle of the deeper portion of the canal extends without doubt throughout the entire canal. Hence, in the present case, after the cuticle had separated from the drum-membrane, the centrifugal motion of the remoter parts of the separated membrane—due to the traction exerted by the outwardly-moving healthy cuticle of the external auditory canal—must have produced at first merely a state of tension (equilibrium) in the central portions of the cuticular membrane. At a later moment, however, this outward motion of the healthy cuticle must have exerted a symmetrical outward traction upon the cuticular membrane, eventually lifting it completely off the underlying membrana tympani. That in this particular case a rupture did not occur at some point must be ascribed simply to the fact that probably all things conspired to favor a separation of the desquamated cuticle in its entirety. After the act of separation had once taken place there was no reason why the separated cuticle (then an independent diaphragm) should not remain unbroken until acted upon by some force from without. If different parts of the healthy cuticle of the external auditory canal travelled outward at different rates of speed, we might look for a rupture, or at least for a distorted

cuticular diaphragm. The flatness of the membrane, in the present case, and the inclination of the plane which it occupied, to the axis of the meatus, would rather favor the view that the rate of speed is the same for all parts of the canal.

Further observations and experimental researches will doubtless some day determine accurately all the facts connected with this peculiar horizontal cuticular motion, analogous to the growth of the nail, which is a cuticular structure.

*Syphilitic Ulcers and Condylomata.*—So far as I can judge from my own experience and from the publications of writers on otology, cases of syphilitic disease of the auditory canal are comparatively rare. I have never seen the disease in this locality in its first stages; the patients have always presented themselves for treatment at a time when the lesions had reached their full development. The following three cases may serve as typical illustrations:

The first case is that of a man, forty-four years of age, who stated that he had caught cold three weeks previously, but did not notice anything wrong about the ear until about two weeks later. The left ear then began to ache, and very soon afterward a discharge appeared at the orifice of the auditory canal. From that time to the day on which I first saw the patient, the discharge, he said, had been constant. On examination, I found the left membrana tympani red, very much swollen, and perforated anteriorly and inferiorly. The lower wall of the outer half of the meatus was ulcerated for a distance of about half an inch. The ulcer extended outward upon the auricle, and its limits were everywhere quite sharply defined. An examination of the throat revealed the existence of well-marked syphilitic lesions, and, on questioning the patient, he admitted that he had had a chancre one year previously. (This case was not seen again.)

The lesions observed in this patient's ear were not of such a character as to suggest at once a syphilitic origin. It was only after the throat had been examined that the thought of a common origin for the two sets of lesions suggested itself to my mind. And yet, if we reflect for a moment, we shall be obliged to admit that the development of a well-defined ulcer in the auditory canal, after a discharge from the deeper parts of the ear had been going on for only one short week, is a very unusual phenomenon. In children the external auditory canal is very apt to become ulcerated by the constant flow of an irritating secretion over its surface; in adults, however, this rarely happens, and then almost always in connection with a chronic discharge from the ear. In the present case a comparatively large and well-defined granulating area or ulcer had developed in a canal which presented almost no other evidence of active inflammation, and which had been subjected to no other irritating influence than that which may have been exerted by the flow, for the period of a week, of a purulent fluid over its surface. Furthermore, the discharge

was by no means copious, as we should rightly expect it to be if it had been the sole cause of the extensive ulceration observed. These are the points which seem to me to justify the view that this ulcer was a true syphilitic ulcer or gummous degeneration.

The second case is that of a man, twenty-eight years of age, of strong frame and apparently vigorous constitution, who stated that during the month of February, 1878, he first noticed a discharge from the right ear. It came on without pain, lasted for a few weeks, and then ceased of its own accord, without treatment. In the early part of the summer the discharge returned, and from that time forward it had been a constant symptom. He had experienced no difficulty in hearing, but for a short time before I saw him he had noticed some soreness of the affected ear. On examination I found the following conditions: The orifice of the right meatus was almost completely obliterated by the presence of an elevated patch of what seemed, at first sight, to be simple granulation-tissue; the dividing line between this patch, which completely encircled the orifice, and the healthy skin of the auricle, was sharply drawn, the edges of the elevated portion being quite abrupt. When the auricle was pulled upward, backward, and a little outward, the flattened patch opened in the centre and displayed a narrow entrance to the auditory canal beyond. At the same time fissures became visible in the outer surface of the patch. When the auricle was allowed to resume its natural position, these fissures completely disappeared, and the central opening became converted again into a mere depression in the centre of the patch. When examined more closely, this circular patch, which seemed to be composed of granulation-tissue, proved to be made up, in reality, of very numerous minute vegetations or papillomata, the majority of which were of a pale pinkish hue, while a few presented a decidedly red color. A watery discharge oozed from the lower part of the elevated patch. The fissured appearance observed when the parts were put upon the stretch was found to be due to the fact that the minute papillomata sprang in groups from rather broad trunks, and the fissures corresponded with the spaces which separated these larger trunks. Just inside the orifice were found a few growths which were quite large in comparison with the greater number,—as large, *e. g.*, as a hemp-seed, or even larger. The external auditory canal itself, so far as the eye could see with the aid of a small speculum and reflected light, was filled with similar vegetations. Between the larger masses were numerous smaller and more pointed growths, like those observed at the orifice. When touched with the probe, the larger of these growths were found to be considerably harder than ordinary granulation-tissue. Some of them looked precisely like (on a smaller scale, of course) the warts seen on the fingers of young children, the skin covering them being pale and tough like natural skin. The smaller papillary growths, and one or two of the larger ones near the orifice of the canal, were less firm in structure, and bled readily when they were manipulated with the probe. The membrana tympani was not visible. The gland lying upon the mastoid process of the same side was enlarged to such an extent as to cause a visible swelling in this region. The occipital glands were also moderately enlarged. A diffuse discoloration of the skin, with desquamating surface, was observed on the hairy scalp, and also to a slight extent on the forehead of the left side. Two well-marked mucous patches occupied the

left half of the velum palati. On questioning the patient it was ascertained that he had contracted the primary lesion about fifteen months previously.

Treatment was not begun until September 4th. It consisted in daily inunctions of mercury (about a drachm of Squibb's oleate of mercury [5 per cent.]), and also its internal use (one thirty-second of a grain of the bichloride three times a day). The larger vegetations which were within reach were snipped off with the scissors; the smaller ones were touched with nitric acid. The patient was simply instructed to keep the ear clean by syringing it out from time to time with warm water.

September 26th.—The dose of the bichloride was increased to-day to one-sixteenth of a grain three times a day. The patient was also given some calomel with which to dust those vegetations which were within his reach.

October 2d.—Patient feels better in every way, and says that the otorrhœa is diminishing in quantity. The patch of vegetations around the orifice of the external auditory canal has perceptibly diminished in height and in vividness of color.

October 23d.—Patient has gained thirteen pounds in weight since the 4th of September. He has been very faithful in using the remedies prescribed. The squamous eruption on his forehead has almost disappeared. The orifice of the external auditory canal has been steadily increasing in size. Very little change, however, is perceptible in the condition of the deeper portions of the canal. By aid of the probe it was ascertained to-day that the innermost section of the meatus, close to the membrana tympani, was smooth and apparently free from vegetations. The "mucous patches" are still visible on the velum. Iodide of potassium is to be added to the bichloride mixture, in the proportion of ten grains to each dose.

November 6th.—The wart-like growths in the external auditory canal have become less prominent; they encroach less upon the calibre of the canal, and the intermediate bright-red pointed condylomata have lost their bright color and well-defined outlines. Nitric acid (undiluted) applied firmly to one of the more prominent excrescences near the external orifice. The pain which followed lasted but a minute or two, and then entirely disappeared. Appetite good. No evidence of sponginess of the gums.

November 13th.—Application of nitric acid repeated to-day. The orifice is now increasing in size quite perceptibly and the deeper condylomata—simply under the influence of the constitutional treatment—have now shrunk away to mere elevations of the skin. The discharge is also very much less than at first. The inunctions are still kept up. The improvement in the condition of the meatus has been more marked during the past week than during any previous week since treatment was begun. No appreciable change in the condition of the mucous patches on the soft palate. Dose of potassic iodide increased to twenty grains three times a day.

November 20th.—Patient has now gained twenty-six pounds in weight. The discharge from the ear has ceased, and almost every trace of the condylomata has disappeared. Membrana tympani entire.

In a third case, the conditions observed in the auditory canal were in many respects different from those which I have just described.

The patient, a woman, twenty-five years of age, was under treatment at the time, for syphilitic disease of the vulva. The first symptoms referable to the ear were noticed about eight weeks previously. The ear became painful, and soon a discharge took place from the external auditory canal. Three weeks previously the ear again became painful, and relief was only obtained by making a free incision through the mastoid integument, leeching and other simple measures having failed to quiet the pain. At the time I saw her the meatus was obstructed by the presence of several wart-like growths, situated on opposite sides of the canal, and bathed with a thin watery pus. These growths were very firm in texture, being covered apparently with true skin. The largest was equal to a pea in size, and sprang from the base of the tragus by a broad base. The drum-membrane and the deeper parts of the canal were concealed from view by these growths. By aid of the probe, however, I ascertained that the latter were not connected with any fistulous opening in the bone or with any superficial spot of caries. (The case was not seen again.)

In a paper published by H. Schwartze in 1869,<sup>1</sup> he states that in the auditory canal polypoid granulations undoubtedly occur, which must be considered as a local manifestation of constitutional syphilis. "As granulations of this character, however, are exceedingly common in non-syphilitic individuals affected with a purulent inflammation of the ear, it becomes a very difficult matter to decide, in a given case, whether the growths are or are not of a specific nature. From the anatomical examination alone, no definite conclusion can be drawn. The characteristic papillary structure of the tumor which sometimes presents the appearance of a perfectly developed condyloma, is also observed in cases where syphilis is not to be thought of for an instant." As no material modification of this view is put forth in his later treatise,<sup>2</sup> I assume that his opinion still remains substantially the same as it was in 1869. It is quite possible that the two cases of syphilitic "granulations" which came under my observation were exceptionally well-marked types of the disease. This view, however, is rendered improbable by the fact that other authorities (Stoehr,<sup>3</sup> Gruber,<sup>4</sup> and Deprès<sup>5</sup>) have reported quite a large number of cases in which well-characterized lesions of syphilis were observed in the auditory canal. I have also never seen, in non-syphilitic individuals, lesions which resembled in any but a very superficial degree those which I have described above. It seems to me, therefore, that Schwartze's statement is too sweeping in its character, and that it may be set down as a fact that well-defined lesions of constitutional syphilis may occur as well in the external auditory canal as in other parts of the body.

<sup>1</sup> Archiv für Ohrenheilkunde. Vierter Band. Würzburg, 1869. Pages 253 et seq.

<sup>2</sup> H. Schwartze: The Pathological Anatomy of the Ear. Translated by J. Orin Greene, M. D. Boston, 1878.

<sup>3</sup> Archiv für Ohrenheilkunde, 1869. Fünfter Band, S. 130 et seq.

<sup>4</sup> Ueber Syphilis des Gehörorgans. Wiener Med. Presse, 1870. Nos. 1, 3, and 6.

<sup>5</sup> Annales des Maladies de l'Oreille, etc. December 31, 1873.

*Foreign Bodies.*—If we exclude such bodies as sequestra of bone, hardened masses of cerumen, calcareous bodies, and the so-called cholesteatomata—which are essentially laminated masses of epithelium—we may say that foreign bodies in the auditory canal are not of frequent occurrence. Thus, for example, out of 1,652 cases Dr. Blake found (in 1873) foreign bodies in the meatus sixteen times (about one per cent.). According to the statistical report of the New York Eye and Ear Infirmary for 1878, the proportion was about the same, viz., 30 cases out of 2,784. My own records show a still smaller proportion, viz., about half of one per cent. With regard to the ages of these individuals I find that two-thirds of the cases seen were under twenty years of age. The foreign bodies found in the individuals who were under twenty years of age were quite different in character from those found in the adults. They comprised pebbles, glass beads, a cherry-pit, a prune-pit, ordinary beans, both black and white, a locust bean, a coffee bean, a grain of corn, a piece of lead from a lead-pencil, a piece of slate-pencil, and small rolls of paper. These articles, as will be noticed, are all such as a child would be likely to put into his own ear or into that of another child. Those articles found in the ears of adults were exclusively such as would be likely to find their way into the canal through accident or forgetfulness or else wholly without human agency. In one case, for example, it was a fly; in a second, four flies were found; in a third, two living larvæ of the house-fly; in a fourth, a cockroach or Croton bug; in a fifth, a young bed-bug. In several cases stiff hair was found sprung like a bow between the wall of the canal and the drum-membrane; and finally in a few cases a forgotten mass of cotton-wool was found impacted between the drum-membrane and the anterior wall of the meatus.

*Symptomatology.*—In many of the cases which come under observation, the patient complains of no symptoms whatever. Some mischievous playmate, or the boy himself, has introduced a bean, or a bead, or some other small object into the canal, and the parents are afraid that some harm may come to their child if the foreign body is allowed to remain in the ear. It is this fear on their part, and not any deafness or suffering on the part of the child, which usually leads them to consult a physician. Now and then the rough manipulations of medical men who attempt to remove a foreign body from the ear without seeing exactly what they are doing, convert a simple case of this kind into one of a very complicated and painful nature. In former years I saw several cases of this kind, but recently I have not seen a single instance; and I am disposed to consider this fact as an evidence that physicians generally are more careful than they used to be in their management of such cases.



In another class of foreign bodies the patient experiences well-marked symptoms. Thus, for example, in those cases (by no means rare) in which a hair is found sprung between the membrana tympani and the sensitive skin of the outer canal, the sensation of pressure or fulness in the affected ear is sufficiently marked to lead the patient to consult a physician. In other cases in which a piece of dried cuticle is found wedged in between the drum-membrane and the wall of the canal, the patient is apt to complain of a crunching noise in the affected ear whenever the jaw is moved. Although from an anatomical stand-point it is difficult to comprehend how the motions of the jaw can exert traction upon either the membrana tympani or the skin lining the extreme inner end of the auditory canal, the fact remains that the opening and shutting of the mouth may produce sufficient motion in these parts to cause a slight friction between the foreign body and the drum-membrane. In the cases in which dead flies were found in the meatus, the patients had experienced no unusual symptoms, and were unable to say when or how these insects had found their way into the ear. As both patients were affected with a chronic purulent inflammation of the middle ear, it is quite likely that the flies were attracted to the ear by the odor of the discharge. The presence of living larvæ of the house-fly in the canal of another patient, also a sufferer from chronic purulent inflammation of the middle ear, is probably best explained by assuming that the eggs were actually deposited in the auditory canal by a fly, probably while the patient was asleep. The Croton bug and the bed-bug also undoubtedly effected an entrance when the patients were asleep, for in neither of the cases could the patient state at what exact time the insect entered the canal. At a certain time, however, both patients became aware that some living creature had got into the ear, as a sensation of something moving in the canal was felt by each of them. The Croton bug was dead when I extracted it; the bed-bug was alive, and when first seen presented the appearance of a small mass of brownish ear-wax adherent to the upper part of the drum-membrane.

Finally, in those cases in which unskilful and unduly violent efforts had been made to remove the foreign body before the patients finally came under my observation, the prominent symptoms were: marked pain and tenderness in the region of the ear, a bloody discharge from the canal, and a great dread of having the ear touched. In one of these cases I found the pebble lying partly in the meatus and partly in the middle ear, the drum-membrane having apparently been lacerated by the efforts previously made to remove it. In another instance the bony surface of the canal was found to have been laid bare. In a third case

the external orifice was found to be in such a swollen condition that the diameter of the foreign body beyond must have been at least twice as great as that of the canal through which it would have to pass, while being extracted. Were it not for these, now fortunately rare cases, the symptomatology of foreign bodies in the external canal might almost be omitted altogether.

I should perhaps mention the fact that women sometimes consult a physician for the purpose of having an imaginary foreign body (generally a pin) removed from the ear. I have seen two or three such cases, and have observed in each instance that the patient seemed to be annoyed by my assurances that the auditory canal was perfectly natural and contained nothing that did not belong there. Judging from their actions, after the results of the examination had been communicated to them, I have no doubt that they ascribed my failure to find the foreign body to lack of sufficient skill in examining the ear.

*Treatment.*—Hard substances, like beads, pebbles, or buttons, if they do not cause pain, and if they are not actually impacted in the auditory canal, may be allowed to remain there undisturbed for a reasonable length of time. In one of my cases, for example, a glass bead of large size had remained twelve years in the canal without doing the slightest damage that I could discover. As the foreign body, however, may change its position and become wedged in between the drum-membrane and the anterior wall of the canal, and as an intercurrent inflammation of either the meatus or the middle ear might be seriously complicated by the presence of such a foreign body in the canal, it is better not to delay its removal any longer than is necessary to ensure a successful result. If the body is impacted in the canal and is causing pain, the sooner it is removed the better. If the operation is postponed, the outer portion of the canal may become swollen, and the task of extracting the foreign body may thereby be rendered materially more difficult. In the case of substances like dried peas and beans, which may swell up in water to fully twice their original size, it is important to abstain from using the syringe; or else, if we fail by means of it to remove the foreign body, we should proceed, without further delay, to extract it by means of instruments.

Small bodies, which simply lie in the canal without being impacted between its walls, may be removed by means of such instruments as the slender forceps, the curette, or a bent probe, or by means of the syringe and warm water. If the foreign body is of sufficient size to fill the canal, or to press against its sides at two or more points, the use of the syringe seems to me to be thoroughly irrational and unpractical. What is required in such a case is a "force from behind," and not one that spends itself

upon the outer surface of the foreign body, and thus tends to drive it deeper down into the canal. If the shape and position of the body are such that we may with some degree of confidence hope to extract it by seizing it directly with the slender forceps, this plan may be adopted. But it is far better not to make such an attempt, unless we are quite confident of success; for if we lose our grasp upon the body, we may be almost sure that we shall drive it a little beyond the position which it previously occupied, and thus render the problem of removal correspondingly more difficult. The better plan is to explore the circumference of the foreign body with the probe, and thus ascertain whether there is not some point where it is separated by a certain amount of space from the wall of the meatus. This is the point at which we should introduce the instrument by means of which we intend to bring the desired *vis a tergo* to bear upon the foreign body. In the case of a roundish body like a cherry-pit, a pea, or a bean, we shall undoubtedly fail to find such a point. Under these circumstances, if we desire to bring a similar force to bear upon the impacted body, we must employ an instrument that is both slender and strong; slender enough to force its way between the foreign body and the skin of the canal, without injuring the latter, and yet strong enough, after it has once been pushed inward the requisite distance, to exert a decided downward and outward pressure upon the inner end of the mass. The smaller curette and a delicate steel hook are almost the only instruments which I have used for the purposes we are now considering. The curette is made of steel and has been sufficiently described in an earlier section. The hook should also be made of steel, but the shank should be tempered (moderately) and not left in a malleable state like that of the curette-shank. In introducing the curette, which must first be slightly bent flatwise, we must make its ring-shaped end describe an arc of a rather small circle, or we shall cause the patient unnecessary pain, and perhaps fail to carry the end of the instrument beyond the foreign body. In introducing the hook we must follow a somewhat different principle: as in the case of the curette we must introduce it flatwise, but as we push the instrument farther and farther inward, we must make the end of the hook proper hug the foreign body constantly. By pursuing this plan we shall know instantly when the instrument has reached the inner end of the foreign body; for the hook, no longer meeting with the resistance offered by the side of the obstructing mass, will at that very moment perform the rotatory movement which the pressure of our fingers has tended to give it. We must not allow it, however, to perform more than a quarter of a turn, for fear of bringing the free end in contact with the walls of the canal. When the hook has per-

formed this quarter revolution, we should withdraw it cautiously but firmly, and thus dislodge the impacted foreign body. If that portion of the canal which is external to the foreign body is very much swollen, it will be found necessary to first dilate it gradually, by means of a series of well-polished conical specula, or by means of cotton-wool wound tightly around the end of a cotton-holder and moistened with vaseline or oil. In the case of older children it will probably not be found necessary to administer an anæsthetic; and even in the younger ones I have only few a times found it impossible to proceed without the administration of sulphuric ether. Again, let me emphasize the importance of carrying out all these manipulations only when the canal is satisfactorily illuminated.

The after-treatment in the graver cases is based upon the same principles as those which govern the treatment of other acute inflammations of the canal or of the middle ear. In the simpler cases no after-treatment whatever is required.

Before leaving this subject of foreign bodies in the external auditory canal, I must say a few words in regard to the operation of displacing the auricle and cartilaginous portion of the meatus forward, for the purpose of gaining a greater amount of room and a shorter canal. The question of performing this operation can only arise in very exceptional cases, viz.: when all other means have been tried and have proved unsuccessful. My own experience is confined to a single case, the history of which I will give here briefly:

The patient, a boy nine years old, was brought to me by his mother with the statement that on the previous day one of his playmates had pushed a locust bean<sup>1</sup> into his right ear. Efforts were made by the nurse and by a friend to extract the foreign body, but without success. On examination I found that a hard and slippery body was immovably lodged at the inner extremity of the canal, and that at one or more points the skin had been torn from the underlying bone. All the parts were bathed with a bloody secretion. There was no pain and the parts around the ear were free from tenderness. Sulphuric ether was administered, and repeated efforts were made, both by Dr. Francis Delafield and by myself, to dislodge the bean from its remarkably firm anchorage between the anterior and posterior walls. These efforts were made exclusively with steel hooks, which were passed flatwise between the bean and the wall of the meatus, and then turned through an arc of about ninety degrees, so as to bring the short arm of the rectangular hook directly behind the foreign body, between it and the drum membrane. No force that we could bring to bear was found sufficient to dislodge the bean. The boy was allowed to regain consciousness, and the mother

<sup>1</sup> These beans are of a brownish color and vary but little in size. They are highly polished, are exceedingly hard, and do not swell up or grow softer when soaked for a period of several days in water. They are shaped like a hen's egg that has been flattened longitudinally, and they measure 10 mm. in length, 7 mm. in breadth, and 5 mm. in thickness.

was informed that it would be necessary to partially separate the auricle from the underlying skull, in order to gain more ready access to the foreign body. Her consent was easily obtained, and it was decided that the operation should take place after the lapse of four or five days. At the time named the operation was performed. The details given here are copied from a report of the case which I published soon afterward. "As a first step the hair above and behind the ear was cut away for a short distance from the latter, and then a semicircular incision about three inches in length was made through the skin and underlying soft parts, above and behind the auricle. This incision began at a point situated in front of and a little above the upper and anterior margin of the auricle, and terminated at the tip of the mastoid process. The soft parts constituting this flap were then dissected from the underlying periosteum until the membranous part of the external auditory canal was exposed to view. The point of the knife was then passed, from without, through the membrane, as near as possible to the bony margin of the meatus, and the incision was continued both upward and forward and downward and forward until the calibre of the canal was fully exposed to view. Up to this point in the operation it had been found necessary to place ligatures around six or seven small blood-vessels, the hæmorrhage from which, though not considerable, was sufficient to prevent us from obtaining a distinct view of what we were doing. When the calibre of the auditory canal, however, was exposed to view, the constant welling up of blood from the deeper parts proved very annoying, and some time elapsed before it finally ceased. I was then able to see the bean lying transversely across the long axis of the canal, but its distance from the outer orifice was still so great that in my manipulations with the steel hook I was not conscious that I was operating at a materially greater advantage than when the auricle and cartilaginous meatus occupied their natural positions. After numerous efforts, and when I had almost reached the conclusion that I should fail to dislodge the tightly impacted foreign body, it suddenly yielded to a traction force greater than any I had previously dared to exert. No attempt was made at this time to ascertain the exact condition of the drum membrane. The raw surfaces were thoroughly washed with a strong solution of carbolic acid, and interrupted silk sutures were used in bringing the edges of the skin together throughout the upper portion of the wound, while the lower portion was left open for purposes of drainage. The ligatures, which had been applied to the bleeding vessels, had been cut off short, and they were left to take care of themselves. Powdered iodoform was blown liberally all over the raw surfaces, into the external auditory canal, and upon those outside dressings which came in immediate contact with the wound. Over these was then placed a large pad of absorbent cotton, and finally a gauze roller bandage was passed around the head and neck for the purpose of keeping the dressings firmly in position."

Five days after the operation the dressings were removed, and it was found that primary union had not taken place at any point along the edges of the wound. There was no redness or swelling, no evidence of anything like a process of granulation, and only a trace of pus was visible at the lower part of the wound and in the external auditory canal. When the stitches were cut, however, it was found that primary union had taken place in the

deeper parts throughout an area sufficiently great to keep the flap very nearly in its proper position. To favor union by granulation with the minimum degree of visible scar, I brought the edges of the upper part of the wound in close coaptation, and then applied rubber plaster in such a manner as to crowd the auricle and skin of the cheek upward and backward. The only other dressings employed were sheet lint and vaseline; a roller bandage being used simply for mechanical support. It was not until three weeks after the operation that the external wound finally healed; the discharge from the external auditory canal continuing about two weeks longer. It was found that a small perforation existed in the drum membrane,—probably the result of the various efforts made to remove the foreign body. It healed soon after the discharge ceased. The diminution of the hearing power was insignificant.

The case narrated above is the first one in which I have known a smooth and symmetrically shaped foreign body to become tightly impacted in the osseous portion of the external auditory canal. Indeed, had I not been a witness to the fact, I should have felt strongly disposed to doubt the possibility of such an occurrence.

Dr. J. Orne Green, of Boston, Mass., thus briefly summarizes the important facts relating to the history of the operation of displacing the auricle forward: "The operation of displacement of the auricle forward for the removal of foreign bodies is by no means new in theory. The whole subject is thoroughly discussed by Von Troeltsch in the seventh edition of his 'Lehrbuch' (1881). The suggestion of the operation is found in 'Paulus Aegineta' (660), and in recent times has been recommended by Hyrtl. Von Troeltsch approves of it where operative interference is imperative and other methods of removal are impossible, but suggests that in children the auricle and cartilaginous meatus be separated from the osseous meatus by a simple incision above the meatus along the squamous bone, and in adults that the osseous meatus be reached by an incision along the lower wall of the cartilaginous canal. Neither of these methods seems to me adapted for giving a thoroughly free and large opening for the extraction of expanded bodies like those in this case (one of leaden bullets in the ear), and both seem open to the objection of insufficient drainage after the operation, if such becomes necessary, while the latter method must almost certainly wound the parotid gland and add another element of risk. Von Troeltsch narrates four cases where displacement of the auricle forward was performed, one by Langenbeck and three by Schwartz. All were successful and recovered; one healed *per primam intentionem* and the others by granulation."

On this side of the Atlantic, so far as I am aware, the operation

† Transactions of the American Otological Society, vol. ii., part 5, 1881.

has hitherto been performed only twice, at least for the purpose of facilitating the removal of a foreign body from the deeper parts of the ear, viz., by Dr. J. Orne Green and by Dr. D. B. St. John Roosa.<sup>1</sup> In both instances the foreign body removed from the ear was a leaden bullet. In the case which I have narrated above I was led to perform the operation by the belief that I should thereby gain much more space in which to manipulate hooks or possibly even forceps, and that consequently I should be able to bring a greater dislodging force to bear upon the foreign body. I must frankly confess that in this particular case the gain in space did not materially diminish the difficulty of extracting the bean. The location, size, shape, hardness and polished surface of the foreign body rendered the employment of forceps of any size or pattern useless; and yet the gain in space and the diminution in the length of the canal to be derived from the displacement of the auricle forward prove of the greatest value in precisely those cases which permit the use of forceps. Where the foreign body, however, is hard and polished, and particularly where it is impacted in close proximity to the membrana tympani, and occupies a large part of the calibre of the canal, forceps cannot be used. Under these circumstances, therefore, I believe that the operation is not to be recommended.

In this connection I desire to call attention to the great amount of violence that may be inflicted with impunity upon the osseous part of the external auditory canal and particularly upon its lining membrane of skin. In the present case, for example, there was scarcely any portion of the posterior and upper wall of the osseous meatus from which the skin (*i. e.*, the periosteum) had not been torn; and yet, after the lapse of four or five weeks, all these parts were found to have resumed their natural relations and appearance. I have observed this same regenerative power of the periosteal lining of the auditory canal in other cases, and believe that we may safely trust nature to repair any injuries that we may be compelled to inflict upon this part of the ear in our operative procedures.

*Wounds.*—Injuries to the external auditory canal are, according to my experience, of comparatively rare occurrence. I have seen but three cases, and they were all of minor importance. In one of these the patient had introduced the rather pointed end of a pen-holder into the right ear, just as he rose from his seat to get something at the other end of the room. Passing too near an unusually high stove he suddenly felt a sharp pain in the right ear, as if a pointed object had been violently driven into it. Slight bleeding followed, and the patient almost at once experienced a decided sensation of faintness, which lasted, however,

<sup>1</sup> *Trans. Amer. Otol. Society*, p. 477 of vol. II., part 5.



but a short time. For a period of five days the ear gave him scarcely any trouble, and then it began to be decidedly painful. About a week later still, I had an opportunity of examining the ear, and then found that an abscess had formed in the posterior wall of the canal, not far from the external orifice. From the appearances presented to the eye there could be no reasonable doubt that a distinct collection of pus existed at this spot. The patient, however, declined to have it lanced at that time, and I never saw him afterward.

In the second case it was not ascertained exactly how the injury was received, owing to the fact that the patient was intoxicated at the time. The blow or the fall, however, produced unconsciousness for a short time, and when the patient recovered his senses he observed that blood was escaping quite freely from the right ear. The accident occurred on the 9th of March, 1875, and from that time until the day on which I first saw him, viz., March 13th, an intermittent, but in the main abundant, hæmorrhage had continued. On examination, I found a rather deep irregular wound in the cartilaginous wall of the canal, a short distance from its junction with the osseous portion. The bleeding had at that time ceased, and as the patient seemed to be free from pain, I advised him simply to leave the ear alone. Four days later I found the wound healing naturally by granulation.

In the third case the rib of a steel umbrella frame had been accidentally thrust into the external auditory canal, causing quite a small lacerated wound. Nevertheless the hæmorrhage was quite free; and, even after the lapse of twenty-four hours, I found the blood still trickling from the ear in a steady stream. Upon the introduction, however, of a very small piece of styptic cotton, the hæmorrhage instantly ceased.

The persistent bleeding which seems to characterize these lacerated wounds of the external auditory canal, is undoubtedly to be attributed to the fact that those blood-vessels which pierce the cartilaginous framework—as many of them do—are not capable of contracting and retracting beyond a very limited extent; their physical relations being essentially the same as those of the blood-vessels which traverse bony structures.

NEW-GROWTHS.—The commonest form of new-growth in the external auditory canal is the *osteoma*. It is encountered both in the form of an exostosis and in that of a more diffuse hyperostosis. The latter variety is more frequent than the former. As the child at birth has simply a rudimentary osseous canal, a mere ring of bone (the annulus tympanicus), we may safely assume that an exostosis or a diffuse hypertrophy of the bony canal is never a congenital but always an acquired condition. Out of thirteen individuals in whose auditory canals I found hypertrophy of the



bone (in the form of exostoses) the youngest was twenty-two years of age. In two cases I was able to trace the development of well-marked exostoses to the local irritation accompanying a purulent inflammation of the middle ear. A symmetrical hyperostosis, however, is a much commoner result of this local irritation. The resulting stenosis, or narrowing of the calibre of the canal, is sometimes so great that it is impossible to see the drum membrane and deeper parts of the canal. In a large proportion of the cases of exostoses, however, no exciting cause whatever can be found. The presence of the bony tumors is discovered by accident, and their development seems to take place independently of any appreciable local irritation. Syphilis, gout, and rheumatism are mentioned by some authors as predisposing causes, but I have not been able, in a single instance, to trace such a connection.

One of the most interesting questions connected with these bony tumors relates to their rapidity of growth. So far as my own experience goes, I can throw but little light upon this important question. All but three of the patients were seen only once. In each of these three cases the ear was examined repeatedly during a period of several years, and it was clearly established that the bony tumor was slowly but steadily increasing in size. In the first case (that of a young girl, about eighteen years of age) the new-growth of bone took place in the form of a symmetrical encroachment upon the calibre of the inner end of the osseous canal. At first this stenosis was slight, and the deeper parts could still be seen under good illumination. The drum-membrane had been entirely destroyed; at one or two points in the middle ear exposed bone was felt with the probe; near by were areas of granulation-tissue, and there was a constant flow of pus over the walls of the canal. In less than three years the hyperostosis had made such progress that it was utterly impossible to see anything of the deeper parts of the ear through the contracted canal. In this case the growth of bone seems to have been a gradual one, and if it had continued at the same rate, complete obliteration of the canal, at the region of the stenosis, in the course of two or three years more, might have been safely predicted. This case passed out of my hands, and I am unable to report its subsequent progress. In another case, however, three or four large confluent (if I may be permitted to use the term) exostoses developed in the comparatively short period of three years, and then made no further progress during the following two years. When the exostoses ceased growing, the diminution



FIG. 26.—Exostoses nearly filling the lumen of the external auditory canal. (After Gruber.)

in the size of the canal was so great that I could barely pass a slender silver probe through the narrowest part. That no further diminution in the size of the canal took place during the next two years, was shown by the fact that I was still able at the end of that time to pass the same probe through the narrow part of the meatus. I watched this case with considerable interest, fully expecting that the previous rate of growth of the exostoses would be maintained, and that the resulting obstruction to the discharge of pus from the middle ear would necessitate an operation. As the patient (a dry goods clerk, thirty-five years of age) promised to come and see me as soon as he observed any material change in the condition of his ear, and as I have not seen him for about three years, I think it quite probable that no further growth of the bony masses has taken place during this period.

Finally, in a third case, the rate of growth of the exostoses was apparently more rapid. The patient, a physician, thirty-four



FIG. 27. — Exostoses springing from the upper wall of the external auditory canal, in close proximity to the short process of the hammer. (After Politzer.)

years of age, had always heard well, and had never experienced any unnatural sensations in either ear, until toward the end of 1871. He then, for two or three successive days, experienced severe pain in the right ear, and Dr. Hackley, an experienced aurist, who examined the ear, after the severe pain had subsided, found in the meatus a circumscribed swelling which presented the appearance of a furuncle that had not yet reached maturity, or had already begun to subside. In September, 1872, about a year after this condition of the right auditory canal had been observed, the patient consulted me for a troublesome tinnitus in the same ear. On examination I found the canal narrowed by the presence of two broad-based exostoses, situated exactly opposite each other, the one on the anterior, the other on the posterior wall, close to the junction of the cartilaginous with the osseous part of the meatus. Deeper in was a third exostosis, which overhung the drum-membrane, and apparently pressed against it. Smaller exostoses, occupying almost the same positions as those observed in the right ear, were found in the left meatus.

In March, 1873, I examined both ears a second time, and found that the exostoses in the right auditory canal, at least the two outer ones, had increased noticeably in size. Their summits approached within a millimetre of each other, and the outlines of the walls of the canal presented a perfect resemblance to the old-fashioned hour-glass. On the left side, apparently no change had taken place in the size of the bony tumors.

In October, 1876, I examined the patient for the third time, but could find no evidence of further growth on the part of the exostoses in either meatus.

It seems reasonably clear, therefore, that there is no fixed law governing the growth of these exostoses. At one time they increase in size at a relatively rapid rate, and then, for a period of years, without any perceptible change in the condition of the immediate surroundings, they show no further signs of growth. An irritating purulent discharge seems to be an exciting cause of their growth in many cases, and yet in others (*e.g.*, the last case mentioned) the growth of bone proceeds without any demonstrable exciting cause.

The prevailing shape of the exostoses that I have seen has been that of a hemisphere, or low, broad-based cone. I have only twice seen a distinctly pedunculate exostosis, and in only one of these cases was the peduncle noticeably smaller than the body of the tumor. In the majority of cases I have found more than one exostosis in the auditory canal. If at first the growths are more or less separate and distinct, at a later stage they will be found to merge so completely the one into the other that a mere undulating surface is presented to the eye of the observer.

The bony character of the tumor is easily ascertained by means of the probe, or, better yet, by means of the paracentesis needle, or the curved, sharp-pointed bistoury. As a rule the surface of these exostoses is very slightly sensitive, and the sharp point of a knife is felt even less than the pressure of the comparatively broad end of a probe. The skin covering them is exceedingly thin.

There are only two conditions, it seems to me, which justify the surgeon in *recommending* operative interference with these bony tumors. For instance, if there is marked or total deafness in one ear, and the growth of an exostosis in the other auditory canal shuts it up and deprives the individual of the use of his only available ear, operative interference would, it seems to me, be perfectly justifiable and proper. It should first be clearly established, however, that a useful degree of hearing had existed in the ear before the canal became entirely closed by the bony growth. Again, if a chronic purulent inflammation of the middle ear is associated with exostoses, or with a diffuse hyperostosis, of the osseous auditory canal, and if, through the gradual growth of these masses, the canal becomes so narrow that the pus can no longer escape with sufficient freedom, it is clear that the only remaining natural outlet for the pus is through the Eustachian tube. This channel, however, is very often so narrow that comparatively little pus can escape through it. Stagnation follows, and yet pus continues to form in this closed cavity. Under such

circumstances the indications for operative interference are very clear and urgent. It is rare, however, that either of the conditions described above occurs. I have never seen a case in which operative interference seemed to be indicated; but Dr. J. Orne Green, of Boston, reports<sup>1</sup> the case of a young man in whose auditory canal two exostoses so nearly closed the meatus that the pus secreted in the middle ear could no longer escape freely enough, and death soon followed from the meningitis set up by the retention of the pus. Four days before the patient's death, Dr. Green was sent for. By means of a hand-drill he established a channel, 3 mm. in diameter, through the exostoses. With a larger drill he made an opening behind the ear into the mastoid antrum, and, by means of a syringe, passed a current of warm water from the meatus into the middle ear and antrum, and thence out through the external wound. The operation, however, had been performed too late, and the meningitis went on to a fatal termination. In the case reported by Dr. Mathewson,<sup>2</sup> a large exostosis almost entirely closed the auditory canal, and materially diminished the patient's hearing. Through this mass, which proved to be as hard as ivory, Dr. Mathewson established quite a broad channel by means of drills driven by the so-called dental engine. The operation was completed in less than thirty minutes. To judge from this single experience, this form of motive power presents decided advantages over that supplied by the hand. The drill can be guided with at least equal accuracy, and it can be equally well prevented from penetrating suddenly to a greater depth than is desired. In cases such as that described by Dr. Green it may be found desirable to establish a counter-opening in the mastoid process, so that a stream of water, introduced into the meatus, may enter the antrum and then pass out through the artificial opening in the mastoid process. The necessity, or lack of necessity, for the establishment of this second opening will depend chiefly upon the degree of success attained in cleansing the deeper cavities of the ear, through the re-established meatus, and also upon the degree to which the mastoid process appears to be involved in the inflammation.

I can find but one case on record of a primary *cancer* of the external auditory canal, viz., that reported by Kessel.<sup>3</sup> It is quite possible that there are other cases in the literature of this subject, but my limited search has failed to discover them. The cases reported by Delstanche, fils,<sup>4</sup> as one of primary cancer of the external auditory meatus, can hardly be accepted as a well-estab-

<sup>1</sup> Boston Medical and Surgical Journal, April 18, 1878.

<sup>2</sup> Transactions of the First Congress of the International Otological Society. New York, 1877.

<sup>3</sup> Ueber Ohrpolypen. Arch. f. Ohrenh. Bd. IV., S. 184.

<sup>4</sup> Archiv. für Ohrenheilkunde, Bd. XV., S. 21.

lished instance of this disease. I have read the account carefully, and am by no means satisfied, nor does Delstanche himself seem to be, that the disease may not have developed first in the middle ear. Furthermore, Kessel's case can scarcely be considered as entirely satisfactory. Prof. von Biesiadecki gave him, for microscopic examination, twenty-two specimens of polypi that had been removed from the ears of different individuals. No histories accompanied these specimens, and no other data were known to Dr. Kessel beyond the scanty information which he could glean from the labels on the bottles that contained the polypi. One of these growths, which was labeled as coming from the external auditory canal, presented to the naked eye all the features of a medium-sized, knobbed wart. A microscopic examination showed it to be provided with hairs, and with sebaceous and ceruminous glands. It therefore, in all probability, grew from some portion of the outer half of the meatus. Its outer surface was composed of a thick layer of epidermis cells which sent prolongations of epithelium deep into the substance of the wart. The presence of numerous balls of concentrically arranged epithelial cells and of nests of these elements, seemed to Dr. Kessel to establish the cancerous nature (epithelioma) of the growth beyond a shadow of a doubt. Such a conclusion, however, does not appear to me to be warranted by the facts. The minute anatomy of a perfectly benign wart is so like that of the malignant epithelioma, that without other data (the history of the case, the condition of the neighboring glands, etc.), one would hardly be justified in expressing so positive an opinion.

Even secondary cancers of the auditory canal are by no means common. Of the two cases which have come under my observation, one was preceded by a cancer of the middle ear, the other by one that originated in the glands of the neck behind and just below the ear. The former case will be narrated in detail in the chapter on diseases of the middle ear. The facts of interest in the latter case are as follows:

The patient, a female, thirty years of age, and in rather poor general condition, was seen for the first time on the 3d of June, 1872. She stated that nine years previously a hard swelling showed itself on the left side of the neck, close behind the ear. It came without pain, and gradually increased in size until, at the end of five years, it had reached the dimensions of a large egg. It was then removed by Dr. Thomas Markoe, of this city, who found it to be a cystic tumor. The wound healed promptly, and for a period of about three years she remained free from any evidence of a return of the growth. Then, after the birth of her last child, the parts around the ear became swollen and painful. At the end of two weeks the swelling gradually subsided without the formation of pus; the pain disappeared, and the patient remained free from all symptoms referable to the region of the ear

for a period of several months. Early in July, 1872, she passed through a second attack of acute swelling of the parts around the ear, and again the attack passed off without giving rise to the formation of an abscess. Unfortunately, it is not stated in my notes whether complete subsidence of the swelling followed both of these attacks, or whether after each a certain degree of permanent swelling remained. It is stated, however, that throughout both of these attacks no appreciable deafness and no tinnitus or other subjective aural symptoms were present. During the following March she experienced a third attack, more severe than any previous one. This time there were both deafness and tinnitus, and at the end of a few days an abundant, and at times bloody, discharge made its appearance in the external meatus. From that time onward the discharge was constant, and the swelling behind and below the ear steadily increased. Early in May Dr. James Little, through whose kindness I had an opportunity of examining the patient's ear, opened an abscess situated immediately over the left mastoid process. By aid of the probe he ascertained the existence of a sinus, leading from the cavity of the abscess into the external auditory canal. No denuded bone was found. At the time when I saw the patient, about four weeks later, the opening behind the ear still existed, and pus could easily be forced out through it by pressure made upon the skin in the vicinity. Just in front of the tragus an irregularly shaped hard mass could be felt, which extended backward to the mastoid region. The skin was freely movable over the mass. The outer orifice of the auditory canal was filled with a reddish, mulberry-like fleshy mass, bathed with a thin, pinkish pus. When manipulated with the probe it bled easily, but yet was quite firm in texture. By grasping the body of the tumor beneath the auricle, and moving it in different directions, I was able to satisfy myself that the fleshy growth in the meatus was simply an outgrowth from it. By means of the probe I ascertained that the cartilaginous wall of the meatus had been pierced (as already discovered by Dr. Little) at a point situated posteriorly and below, and not far from its junction with the osseous portion of the canal. One of the fibrous gaps in the cartilage (fissure of Santorini) had probably been the point through which first the pus of the abscess and then the offshoot of the tumor had forced their way.

No attempt at an operation was made. The tumor steadily increased in size, and eventually caused the patient's death.

Primary *sarcoma* of the external auditory canal is of very rare occurrence. Only one case has come under my observation, and I have not been able to find reports of any other cases in otological literature. The history of the case referred to is as follows:

The patient, a strong healthy girl, fourteen years of age, consulted me on the 25th of May, 1880, for an affection of the right ear, of recent date. About two weeks previously she noticed a sensation of fulness and perhaps very slight pain in the right ear. This was the first intimation that she received that her ear was not perfectly sound in all respects. She had never previously experienced either pain, discharge, deafness, or any other symptom referable to the ear. In the course of a few days a slight discharge was discovered at the outer orifice, and as the sensation

of fulness still persisted, the family physician, Dr. A. A. Smith, was called in to see the child. On examination with the speculum and reflected light he discovered that the canal was blocked, near the outer orifice, by a rather solid fleshy mass, which bled quite freely when he removed a part of it with the snare. Being convinced that the case was not one of ordinary polypus of the ear, Dr. S. referred the patient to me for further treatment. The tumor at this time extended outward almost if not quite to the plane of the outer orifice of the auditory canal. It presented a smooth, but slightly uneven surface, felt very firm when pressed upon with the probe, was not at all sensitive, and seemed to spring by a very broad base from the upper and posterior wall of the osseous portion of the auditory canal. The cervical glands were not enlarged. The left ear was perfectly healthy. Twice in succession I surrounded the mass with a loop of No. 37 malleable steel wire, but both times the wire broke when I attempted to make it do the work of cutting through the tissues of the tumor. I then employed a blunt-pointed, curved (flatwise) bistoury, and endeavored to cut away the growth close to its base. The cutting edge of the knife, however, encountered bony resistance, and I was obliged, for the moment, to remain satisfied with the removal of two fragments, both together equal perhaps to one-third of the entire tumor. Moderately abundant bleeding followed this operative interference, but it ceased in the course of a few minutes. Exploration with the probe failed to discover any central channel or sinus, such as is found in those very similar tumors of the auditory canal which depend upon a limited area of carious bone. As soon as the bleeding had ceased, the patient noticed that her hearing was as perfect as it had ever been. The fragments removed were placed at once in alcohol (90%), and were then entrusted to Dr. William H. Welch for examination. His report reads as follows: "The larger specimen consists, for the most part, of closely compacted, small, round cells, between which is an ill-defined basement substance or stroma, constituting a reticulum when the cells are shaken out. There are also some larger, endothelial-like cells scattered irregularly among the round cells. The smaller fragment consists more of spindle-shaped cells, with a more distinctly fibrous stroma. The growth is rich in vessels, whose walls are embryonic, being composed simply of an endothelial lining and the surrounding tissue. In some parts of the fragment the epidermis is preserved. From the microscopical appearances the specimen is probably to be regarded as round-celled sarcoma, but the possibility of its being granulation-tissue cannot be wholly excluded."

On the 26th of May I succeeded, by means of as strong a wire as I could pass through Blake's double-mouthed cannula, in removing another portion of the growth. This, too, was submitted to Dr. Welch for examination, with the following results: "The specimen presents in some places the same structure as that which characterized the first fragment; but, in addition, it presents certain points of interest. The central part of the specimen is hard, and, under the microscope, is found to consist of osseous tissue, with wide medullary spaces in which the tissue is rich in cells and fibrillated. The rest of the specimen is composed of a tissue containing numerous round and some irregular cells. Near to the bone the cells are less numerous, more irregular in shape, and have between them a homogeneous, glistening basement substance containing some elastic fibres. Peripherally the cells are

more numerous and the intercellular substance less glistening and more fibrillated. There are places where the tissue is of an osteoid character; that is, the cells, with fine processes, are inclosed in spaces in a homogeneous, bony-looking matrix. These seem to represent transition-stages between the sarcomatous tissue and the osteoid tissue on the one hand, and the osteoid and osseous tissue on the other. There are no cells which can be positively claimed as cartilage cells. The tumor seems to be an ossifying sarcoma (osteosarcoma), taking its origin, most probably, from the periosteum."

The patient was then examined by Drs. Robert F. Weir and D. B. St. John Roosa, separately—both of them experts in diseases of the ear. They both agreed that the tumor was not an ordinary connective-tissue growth, and favored an early operation for the purpose of extirpating it as thoroughly as possible. They thought it advisable, however, that a microscopic examination should first be made by another expert; and accordingly I removed (June 7th) another moderately large fragment and submitted it to Dr. Francis Delafield. His report, which was made on the 9th of June, fully confirms that previously made by Dr. Welch. It reads as follows: "The specimen is a small, rounded mass, about the size of half a pea. It was removed from the wound left by a previous operation. It is evident that the specimen consists of a portion of new-growth situated at the edge of the wound. Part of the specimen is covered by a layer of epithelium, and beneath the epithelium is connective tissue with an excess of cells and mucous tissue. The portions of the specimen not covered by epithelium are composed of connective tissue infiltrated with round cells—granulation-tissue. Part of the specimen, therefore, represents a new-growth—part granulation-tissue from a wound. If we compare this specimen with those already examined by Dr. Welch, it is evident that the tumor is one of those composite growths which sometimes grow from the periosteum. It is composed of connective tissue, mucous tissue, bone, and sarcomatous tissue. The prognosis of such a tumor is bad, but not very bad. If the growth can be completely removed, and if the bone is not involved, there may be no recurrence."

In this connection I should state that, during the short period of ten days that elapsed between the two partial operations, the tumor had again fully reached its former size, but not its former degree of hardness. The fragment submitted to Dr. Delafield represented largely this fresh growth.

On the 10th of June the patient was brought under the influence of an anæsthetic (sulphuric ether), and by means of suitable knives (blunt-pointed and curved flatwise) and a sharp-edged steel scoop I removed the entire tumor, together with a zone of apparently healthy skin surrounding its base on all sides. The growth apparently sprang from the periosteum, as the underlying bone felt smooth and hard. A small nucleus of osteoid tissue was found in the centre of the growth. The bleeding was trivial in character. The denuded bone was carefully scraped, and, in addition, a solution of chloride of zinc (forty grains to the ounce of water) was painted thoroughly over all the exposed surfaces. Dr. A. A. Smith and Dr. Robert F. Weir assisted me in the operation.

For about three hours after the operation the patient experienced a moderate degree of pain in the ear. After that she fell asleep and had a good night's rest. On the following morning



she said that the ear felt perfectly natural. I examined the canal and found the parts covered with healthy pus and moderately swollen. The deeper part of the meatus and the membrana tympani appeared to be perfectly natural. The watch was heard at a distance of nearly four feet.

On the 19th of June the patient went with her mother to Newport, R. I., and placed herself under Dr. Rankin's care. The treatment consisted in daily cleansings followed each time by an application of powdered iodoform to the exposed surface of the wound. At the time of her departure from this city only a small depressed ulcer remained; and about the 28th of June Dr. Rankin reported that this had healed and that no further treatment was required. On the 7th of July I had an opportunity of examining the ear. A slight excavation alone remained to indicate the spot from which the growth had been removed. At the very centre of the depression a small dry scab was still visible, but everywhere else the skin was pale, smooth, and perfectly natural in appearance.

A careful inquiry into the family history revealed no instances of cancer or any form of tumor among members of the immediate family. Both parents are strong and perfectly healthy. The maternal grandmother, however, died of some uterine disease which may have been cancerous in its nature. An aunt had a tumor removed from her neck. A grand aunt had cancer of the breast. Two second cousins also had cancers. Several years have elapsed since the removal of the growth, and there have been no evidences of its recurrence.

**CYSTS.**—I have seen but two instances of what might fairly be designated as a primary cyst-like formation in the auditory canal. In one case a small, yellow body, about the size of a No. 6 shot, and consisting apparently of cheesy or sebaceous material, surrounded by a thin envelope of epidermis, projected from the anterior and upper wall of the osseous portion of the meatus, just beyond the junction of the latter with the cartilaginous portion. In the second case a somewhat larger cyst, with cheesy or almost chalky contents, and slightly constricted at its base, sprang from a point on the upper wall of the meatus not more than one or two millimetres distant from the upper limit of the drum-membrane. It was slightly sensitive to pressure made with the end of the probe, and seemed to be quite solid, though of course not so solid as an exostosis. As isolated glands (ceruminous) are sometimes found in the osseous portion of the auditory canal, and especially along the upper wall, I think that these cysts with cheesy contents should be placed in the same category with the sebaceous cysts observed in other parts of the body. Their significance, in the ear, is simply that of pathological curiosities.

In the vicinity of the membrana tympani, cyst-like tumors are occasionally met with, but they are, I think I may safely say, invariably secondary to some affection of the middle ear. In some instances, however, the primary disease recedes so completely

that the cyst-like formation in the meatus gains proportionately in individuality, and may even be taken for a tumor of primary development. As the description of these secondary cysts belongs more properly under the heading of diseases of the middle ear, I will say nothing further on the subject in the present section.



## CHAPTER V.

### METHODS OF EXAMINING THE MIDDLE EAR.

THE means at our disposal for ascertaining the condition of the middle ear are, direct inspection of the membrana tympani and auscultation of the tympanic cavity while air is being forced into it.

*Direct inspection* is almost always accomplished by means of the speculum and reflected light. In a very few cases it is possible to dispense with the speculum, owing to the large size and unusual straightness of the external auditory canal. This simple inspection of the drum membrane usually furnishes us with all the information concerning its texture, degree of vascularity, position, etc., that it is possible to obtain. Now and then, however, a doubt arises in the mind of the observer in regard to the correct significance of parts of the picture presented to his eye. These doubts are perhaps more likely to arise in the mind of the experienced observer than in that of a person who has examined comparatively few ears; for he will have already learned by humiliating experience how extremely easy it is to mistake one thing for another in interpreting lesions of the membrana tympani. Hence the importance, in these doubtful cases, of ascertaining how the lesions in question act and look when they are touched and handled, so to speak, with the probe or the curette, and when they are subjected to the influence of air forced into the tympanic cavity by way of the Eustachian tube, or to alternate rarefactions and condensations of the air in the external meatus. As regards the probing of the drum membrane and adjacent parts under illumination, very little need be said. As the eye of the observer is watching the effects of the instrumental manipulations no possible harm can be done to the ear. The amount of discomfort caused by such manipulations is very slight, provided they be performed with reasonable gentleness. The Valsalva's experiment, described elsewhere, affords the simplest and best means of inflating the middle ear while the physician is observing the drum membrane. If air cannot be forced in successfully in this manner, it will be necessary for an assistant to effect the inflation either by means of Politzer's method or by aid of the Eustachian catheter. When it seems desirable to rarefy the air

in the auditory canal, in order that the observer may have the opportunity of witnessing the behavior of the drum membrane when moved alternately outward and inward, Siegle's pneumatic speculum must be employed. This instrument consists of a central cylindrical chamber (about an inch and a half in diameter and two inches in length), of either metal or hard rubber, to which is attached a flexible rubber tube about one foot in length. To one end of the chamber a conical speculum is fitted; the opposite end is closed by a glass plate which is placed at such an inclination to the axis of the cylinder that the rays of light used for illuminating the drum membrane may readily pass through it without any portion of them being reflected back to the eye of the observer. The free end of the speculum is sheathed with soft rubber tubing, and may therefore be made to fit air-tight into the auditory canal. When the instrument is in actual use the observer, by holding the free end of the rubber tube in his mouth, has it in his power to condense or rarefy the air in the auditory canal, and, while doing so, to watch the effects of these procedures upon the drum membrane and handle of the hammer.

The methods of studying the condition of the middle ear which I have described above, are based upon the direct observation of the drum membrane. The procedures which I am now about to describe have for their object the introduction of air into the middle ear in such a manner that the physician may hear what takes place in that cavity during the procedure. There are three ways of forcibly introducing air into the middle ear: Valsalva's method, Politzer's method, and that by means of the Eustachian catheter.

In inflating the middle ear by *Valsalva's method* the patient closes both nostrils by grasping the nose with the thumb and forefinger of one hand, shuts his mouth firmly, and then makes a strong expiratory effort. In this way he compresses the air in the pharyngeal and nasal cavities to such an extent that it seeks an outlet through the Eustachian tubes. If the effort is successful, the physician, who has previously established a communication between his own ear and that of the patient, by means of a flexible auscultation tube, will hear a slight puff or thud, as the air enters the middle ear and distends the drum-membrane. Of the three methods at our command, this is altogether the most unsatisfactory, at least for the purposes of auscultation. Whether the fault lies with me or with the method I am unable to say positively; but it has disappointed me so often that I rarely use it now, when I desire to learn by auscultation what is the condition of the Eustachian tube and tympanic cavity. When I wish to observe the changes that take place in the *membrana tympani*, while air is being forcibly introduced into the middle ear,

I still give the preference to Valsalva's method. For this purpose it is undoubtedly more convenient than either of the other two methods. For therapeutic purposes, as will be explained farther on, Valsalva's method must be placed third on the list; or, better yet, it should be omitted altogether from the category of therapeutic agents.

*Politzer's method* is very little better, for auscultation purposes, than that of Valsalva, unless the physician can avail himself of the services of an assistant. If he attempts to inflate and auscultate at the same time he will find the task an extremely difficult one, more so in adult patients than in children. In the latter, as a rule, so little force is required to inflate the middle ears, that one can often perform both acts (auscultation and inflation) with comparative ease. So far as the method itself is concerned, it is in principle essentially the same as that of Valsalva. In both methods, for example, the middle ears are inflated by compressing the air that is imprisoned in the nasal and naso-pharyngeal cavities to such a degree that it overcomes the resistance offered by the walls of the Eustachian tube, and forces its way into the tympanum.<sup>1</sup> There are two respects, however, in which these methods differ from each other very widely. In the first place, Valsalva's plan necessitates a degree of venous congestion of the head and neck that is directly proportionate to the force used in compressing the air contained in the naso-pharyngeal space. This fulness of the blood-vessels must necessarily diminish in a measure the permeability of the Eustachian tubes; it also promotes the very pathological condition which in nine cases out of ten leads the patient to consult a physician. In the second place, Politzer's method, while it is at least equally efficient with that of Valsalva in compressing the air contained in the naso-pharyngeal space, is entirely free from the two objections which I have just mentioned. It produces no fulness of the blood-vessels, nor does it diminish the permeability of the Eustachian tube; on the contrary, it makes the patient open that channel so far as it is possible for him to do so by means of the muscles attached to its walls.

The apparatus which is ordinarily used in carrying out Politzer's method of inflation consists of three parts, viz., a rubber bag, provided at one end with a hard-rubber nozzle, and of such a size and shape that it can readily be grasped with the hand; a short piece of rubber tubing, of such a small calibre that the nozzle of the bag will fit it tightly; and, lastly, either a cylindrical or a bulbous nose-piece. So many modifications of this apparatus have been introduced during recent years that one can no

<sup>1</sup> Occasionally the air also forces its way through the lachrymal ducts.

that the cyst-like formation in the meatus gains proportionately in individuality, and may even be taken for a tumor of primary development. As the description of these secondary cysts belongs more properly under the heading of diseases of the middle ear, I will say nothing further on the subject in the present section.



## CHAPTER V.

### METHODS OF EXAMINING THE MIDDLE EAR.

THE means at our disposal for ascertaining the condition of the middle ear are, direct inspection of the membrana tympani and auscultation of the tympanic cavity while air is being forced into it.

*Direct inspection* is almost always accomplished by means of the speculum and reflected light. In a very few cases it is possible to dispense with the speculum, owing to the large size and unusual straightness of the external auditory canal. This simple inspection of the drum membrane usually furnishes us with all the information concerning its texture, degree of vascularity, position, etc., that it is possible to obtain. Now and then, however, a doubt arises in the mind of the observer in regard to the correct significance of parts of the picture presented to his eye. These doubts are perhaps more likely to arise in the mind of the experienced observer than in that of a person who has examined comparatively few ears; for he will have already learned by humiliating experience how extremely easy it is to mistake one thing for another in interpreting lesions of the membrana tympani. Hence the importance, in these doubtful cases, of ascertaining how the lesions in question act and look when they are touched and handled, so to speak, with the probe or the curette, and when they are subjected to the influence of air forced into the tympanic cavity by way of the Eustachian tube, or to alternate rarefactions and condensations of the air in the external meatus. As regards the probing of the drum membrane and adjacent parts under illumination, very little need be said. As the eye of the observer is watching the effects of the instrumental manipulations no possible harm can be done to the ear. The amount of discomfort caused by such manipulations is very slight, provided they be performed with reasonable gentleness. The Valsalva's experiment, described elsewhere, affords the simplest and best means of inflating the middle ear while the physician is observing the drum membrane. If air cannot be forced in successfully in this manner, it will be necessary for an assistant to effect the inflation either by means of Politzer's method or by aid of the Eustachian catheter. When it seems desirable to rarefy the air

claimed for this form of nose-piece are, that it is pleasanter for the patient (that is, less painful than where the hard-rubber one is used) and less likely to produce nose-bleed. Furthermore, the argument is brought forward that in suspicious cases the patient can, at a trifling expense, be provided with his own special nose-piece. I have tried this flexible form of nose-piece, but cannot say that I like it.

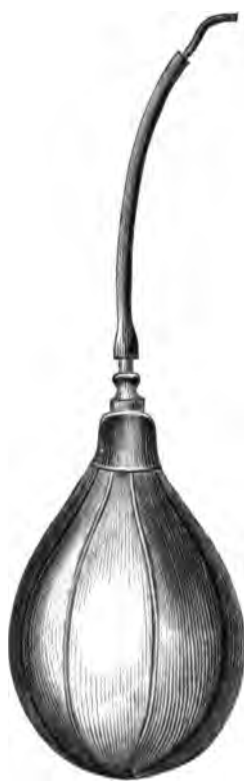

FIG. 29. Politzer's Bag.

I have also tried the plan of slipping a short piece of soft-rubber tubing over the ordinary curved hard-rubber nose-piece, and find it useful in cases where the unprotected instrument causes nose-bleed. In the great majority of cases, however, I find the curved, cylindrical, hard-rubber nose-piece less troublesome to manage, and more effective, than any other instrument of which I have any knowledge.

Before entering into the details of Politzer's method of inflation, I ought to state that this operation of suddenly inflating the middle ears, although in the great majority of cases a perfectly safe procedure, should never be performed until after the condition of the drum-membranes and middle ears has been ascertained by direct inspection with the speculum and reflected light. I can recall the case of a gentleman, an army officer, in whose middle ear there were bands of adhesions which bound the *membrana tympani* down upon the promontory. I did not at that time appreciate the danger of forcibly inflating the middle ear under such circumstances, and consequently made no special effort to moderate the pressure exerted upon the bag. The effect of the inflation was to rupture some small blood-vessel in the middle ear

and fill the cavity with blood, which speedily must have become clotted. The patient, who depended chiefly upon that ear for his power of hearing, at once noticed that the ear felt full, and that everything sounded less distinct than before. He never came to see me afterward, and I accidentally heard, about a year later, that the hearing in that ear had not returned to its previous degree of acuteness, and that my ill-advised interference was looked upon by the patient as the cause of this aggravation of



his disability. On more than one occasion I have ruptured a highly atrophied drum-membrane or a so-called "cicatrical spot," by employing too great force in compressing the rubber bag. I have never known any harm to come from such ruptures of an atrophied or cicatrical drum-membrane. At the same time the effect of an accident like this upon the mind of the patient would be very likely to be of a character prejudicial to the physician who happened to be responsible for its occurrence.

With regard to the different steps of Politzer's method of inflation, very few words will suffice to explain the entire procedure. The patient is told to take a little water into his mouth, and to hold it there, with closed lips, until the physician says, Swallow! At this signal<sup>1</sup> he should forthwith swallow the water. The physician, on his part, is to hold the bag in his right hand, and then, as soon as the patient has taken the water into his mouth, he is to introduce the nose-piece into the patient's left nostril, using, if necessary, the left hand to aid him in accomplishing this. When the nose-piece of the instrument is in its proper position on the floor of the nasal passage, the physician should at once compress the nostrils over the rubber nose-piece, and give the patient the signal to swallow. (Fig. 30.) The act of compressing the bag and forcing air into the nasal cavities should follow the signal almost instantly.

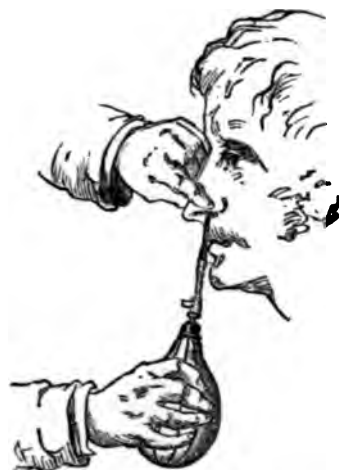

FIG. 30.—Proper Method of using Politzer's Inflation Apparatus. (After Politzer.)

This whole procedure, which seems to be a very simple affair, is found by many physicians to be at first quite difficult of execution. It may therefore prove useful to some if I mention in detail the difficulties which beset the operation. In the first place, it is a common mistake to allow the patient to take too large a quantity of water into his mouth. As the water is taken merely for the purpose of facilitating the act of swallowing, a mere sip is all that is necessary. If a mouthful is taken, the act of inflation is just as likely to force water out of the patient's mouth, over the physician's clothes, as it is to drive air through the Eustachian tube into the middle ear. Then again, the accident of "swallow-

<sup>1</sup> If the patient is very deaf, the operator may use some other signal, such as a nod of his head, or a nudge with his knee.

ing the wrong way" is much more likely to occur when a large than when a small quantity of water is taken.

In the second place, beginners are very apt to delay giving the signal to the patient too long a time after the nostrils have been compressed. The signal should be given and air should be forced into the naso-pharyngeal space as soon as possible after the operator has closed the nasal passages; for it must not be forgotten that, with both nose and mouth closed, the patient is unable to breathe, and consequently is rapidly approaching a condition of discomfort in which a prompt performance of the act of swallowing in response to the physician's signal is no longer possible. Some patients find it very difficult not to open their mouths at the instant of performing the act of swallowing; others, and especially children, do it purposely, in order to escape the unpleasant sensation caused by the sudden compression of air in the nasal cavities. The whole purpose of the act of swallowing, in Politzer's procedure, is to render the naso-pharyngeal cavity a closed space by interposing the soft palate as an air-tight diaphragm between the oral and naso-pharyngeal cavities. There are other ways, however, in which the same result may be attained. For instance, the patient may be told to say "hic" or "hoc," or to distend his cheeks, by either of which means the desired shutting off of the naso-pharyngeal cavity will be effected just as perfectly as by the act of swallowing. At the same time I think it will be found that in every-day practice the swallowing plan gives greater satisfaction than either of the other two methods.

In the next place, if we wish to spare our patients unnecessary pain or the discomfort of a nose-bleed, it is necessary that we should introduce the nose-piece of Politzer's apparatus with some degree of care. The large conical glass nose-piece can scarcely be used in such a clumsy or rough manner as to cause either pain or nose-bleed; but the curved, cylindrical, hard-rubber instrument is very well adapted to cause both, unless introduced gently and in one particular way. Thus, for example, in each nasal orifice there is but one spot where the instrument can properly be allowed to remain while the nostrils are firmly compressed over it, viz., on the floor of the canal, as close as possible to the outer limit. In this position, the instrument, if it has not been pushed in too far, will cause very little discomfort. If the nose-piece is properly curved, it is an easy matter to avoid the danger of pushing it in too far, by always allowing the straight portion of the instrument to rest against the patient's upper lip, in the direction of a line running from the outer angle of the nasal orifice to the outer angle of the mouth.

Finally, the question remains to be considered, how far we

should modify the different steps of Politzer's procedure when the patient is a young child. I have already alluded to the fact that a spherical or cone-shaped glass nose-piece will be found better adapted to young children than the curved hard-rubber instrument. The pressure employed in compressing the bag must also, as a rule, be decidedly less than that usually employed in adults. The device of having the patient swallow a little water at a given signal can scarcely be resorted to in children under four years of age. In an infant it is simply necessary to adjust the glass bulb to one nostril, and then, while the other is kept closed by a finger of the same hand that holds the bulb in position, to compress the bag. It makes no difference whether the child's mouth is open or shut; the inflation seems to succeed equally well in both cases. In children of three, four, or five years of age, it is an easy matter to teach them to distend their cheeks at the moment the signal (blow!) is given. If pain or a sense of fulness in the ear is complained of immediately after the inflation, it is a good plan to let the child swallow two or three mouthfuls of water, in order to facilitate the escape of air that may have become as it were imprisoned in the middle ear.

Finally, the operator must not forget to give the nose-piece a thorough cleaning before he puts the instrument away. Under ordinary circumstances I always place this part of the instrument in scalding water, and whenever I use it upon a suspicious case I first place it in scalding water for a few moments and then allow it to remain for a longer time in a strong bichloride of mercury solution.

The employment of Politzer's method for therapeutic purposes might properly be discussed in this connection. For practical reasons, however, I think it will be better to take up this subject in connection with the individual diseases in the treatment of which this procedure plays an important part.

Of the three methods of inflating the middle ear mentioned at the beginning of this section, Valsalva's and Politzer's have been sufficiently described, and there remains still to be considered that by means of the Eustachian catheter. For purposes of auscultation this method is very justly preferred to both the other methods. When the catheter is used, the air passes through the Eustachian tube into the mid-



FIG. 31.—Eustachian Catheter. (Natural size.)

dle ear in a continuous current of one or two seconds' duration. This steadiness and long duration of the current afford the physician ample opportunity to listen deliberately to the character of the sounds which it produces. For purposes of diagnosis, therefore, this method possesses a decided superiority over the other two.

The Eustachian catheters offered for sale in the surgical-instrument shops are made of hard rubber, of German silver, or of coin metal. Those made of German silver have nothing to recommend them beside their cheapness. A well-made hard-rubber catheter is an excellent instrument, and leaves very little to be desired. It is very difficult, however, to find a well-made hard-rubber catheter; the calibre is rarely as large as it should be, or else, if the calibre is sufficiently large, the total diameter of the instrument is so great that we can use it only in exceptional cases. A good serviceable Eustachian catheter should have a calibre of about two and one-fourth or two and one-half millimetres, and a total diameter of not more than three and one-half millimetres. This proportion of calibre to total diameter is scarcely attainable in an instrument made of hard rubber. The largest rubber catheter that can ordinarily be bought in the shops measures nearly four and one-half millimetres in its total diameter, while its calibre measures only two millimetres. For the majority of patients this instrument is too large, and yet its calibre is barely large enough to allow a current of air of the requisite force to reach the orifice of the Eustachian tube. On the whole, therefore, the silver catheter, if made of coin metal and properly proportioned, will be found to give the greatest satisfaction. I warn my readers, however, that very many of the silver catheters sold in the shops are even less serviceable than those made of hard rubber. The calibre is not one whit larger, in proportion to the total diameter, than that of the average rubber catheter; and when such is the case the latter instrument has decided advantages over the former. There is also another respect in which the silver instrument may be defective; the rim of the free end is often so sharp as to cause the patient pain, either during its passage through the nose, or while it lies in the mouth of the Eustachian tube. This defect, however, can easily be remedied.

With regard to the curve which a good Eustachian catheter should have, I may say that the one represented in the accompanying cut is that which I have found suited to the great majority of adult patients. Some of my colleagues use a straighter instrument, and others, one of even greater curvature; from which facts it is proper to draw the conclusion that the middle ear may be successfully inflated by variously curved catheters. To secure the most effective inflation, however, we should give

the catheter such a curve that, when it is in position and air is forced through it, the direction of the escaping current will be the same as that of the Eustachian tube itself. The common error, so far as my observation goes, is to give the instrument a curve of too short a radius, which causes a large part of the force of the current of air to spend itself upon the upper wall of the Eustachian tube. In children from five to about twelve years of age, it will be found better to use a catheter that is even less curved than that represented in the cut; or one, at all events, in which the curve begins at a point considerably nearer the free end than is the case in this instrument.

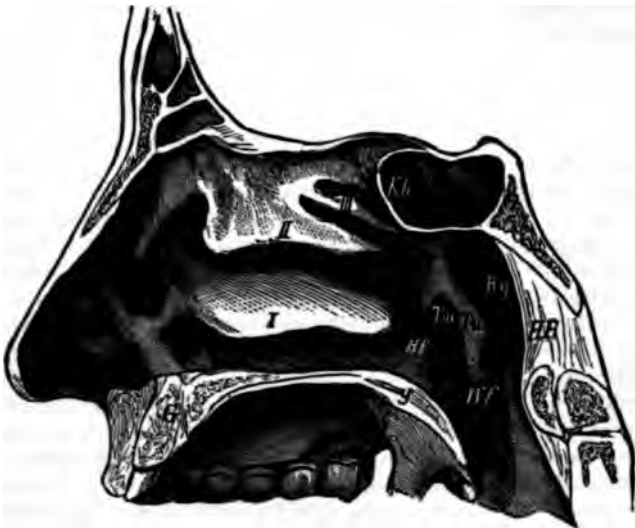

FIG. 32.—Anatomical Relations of the Nasal Passages and Pharynx to the Eustachian Tube. *i, ii, iii*, lower, middle, and upper tubinated bones; *HR*, posterior wall of pharynx; *Rp*, Rosenmüller's fossa; *T<sub>12</sub>*, prominence separating the tubal orifice from Rosenmüller's fossa; *T<sub>16</sub>*, orifice of Eustachian tube; *G*, hard palate; *g*, velum palati; *KA*, cavity of sphenoid bone. (After Hartmann.)

The rubber bag used for inflating the middle ear according to Politzer's method answers equally well for inflating this cavity through the Eustachian catheter. These bags are almost always provided with a rounded or somewhat olive-shaped end-piece, which may be screwed on or off at pleasure. When the catheter is to be used, it is a very common custom to substitute for this end-piece one that represents accurately a section of a cone, and that can therefore be made to fit air-tight into the cone-shaped orifice of the Eustachian catheter. I have tried both of these end-pieces, and give the preference unhesitatingly to the rounded or olive-shaped one. It fits the mouth of the catheter so accu-

rately that the degree of leakage may practically be left out of the account. In this respect, therefore, it is essentially on a par with the cone-shaped end-piece. In all other respects, however, it is decidedly superior to the latter instrument. It can be removed instantly from the mouth of the catheter without disturbing the latter's position in the slightest degree, without causing the patient any of the discomfort which is very apt to accompany our efforts to disengage the tightly fitting conical end-piece, and, finally, without risk of exerting suction-power upon the mouth of the Eustachian tube.

While I believe that a written or *visû voce* description of the proper course to pursue in introducing the catheter into a patient's Eustachian tube may aid a beginner in his efforts to perform this operation successfully, I am quite positive that the greater part of the lesson must be learned by actual experience. It is of comparatively little use to say: at this point, turn to the left; at that, to the right, and so to direct the beginner's manipulations from the commencement to the end of the operation. For the beginning, it is true, we can lay down a sharply defined rule, which will hold good for all cases; for the end, also, we can give directions which will secure success in certainly the great majority of cases; for the intermediate portion, however, we can simply say: follow the course taken by the instrument, even if it perform a complete revolution in its progress to the naso-pharyngeal space. These different steps of the procedure I may briefly describe as follows:

The physician should sit directly facing the patient, and on his right hand, within easy reach, should be his rubber bag, auscultation-tube, and a bowl or goblet, partially filled with water, and containing five or six catheters of different sizes and degrees of curvature. He should have his forehead-mirror in position, ready for use, as he may at the very beginning find it desirable to examine, under illumination by reflected light, the patient's anterior nares. Everything being in readiness, the operator should place the fingers of his left hand firmly upon the patient's forehead, and, with the end of his thumb, he should elevate as much as possible the end of the patient's nose,—the object of the latter procedure being to straighten the entrance to the nasal passage and in so far to facilitate the introduction of the catheter. This instrument should be held lightly by the physician, between the thumb and forefinger of his right hand, and at no time should force be used in overcoming any obstacles that may be encountered. Just within the nasal orifice, the floor of the nasal passage rises up in the form of a ridge, the inner or deeper side of which is more abrupt than the outer one. When the catheter is first introduced into the nasal orifice, its outer end should be at a

somewhat lower level, though in some cases we may begin at once with the instrument in a nearly horizontal position. To pass it beyond the ridge, and engage it in the lower nasal passage, the physician must elevate the ring end of the instrument until it occupies a nearly horizontal position. It is at this stage of the operation that the beginner is very apt to make a mistake. Instead of passing the catheter along the floor of the nasal canal, he slips it over the upper surface of the inferior turbinated bone, and, on approaching the naso-pharyngeal space, wonders why his efforts to turn the instrument into the mouth of the Eustachian tube cause the patient such great distress. A glance at the illustrations of this region, in some good treatise on anatomy, will show how easy it is to make this mistake. It is only necessary to push the beak of the instrument a short distance beyond the summit of the ridge, and we shall find it slipping only too easily along the wrong channel. When the catheter has been pushed beyond the ridge, and is actually resting upon the inferior turbinated bone, the elevation of the ring end of the instrument will not correct the error unless the catheter be withdrawn a certain distance. In the first stage of the operation, therefore, it is important to hug the floor of the nasal passage with the beak of the catheter, at least until the instrument has passed beneath the inferior turbinated bone, and is well engaged in the lower channel. As already stated, it is better, from this point onward, to let the instrument find its own way. By this I mean that if the catheter encounters some obstacles, we should abandon the attempt to push it onward in a certain fixed manner,—*i.e.*, with the beak always pointing downward and backward,—and should rotate the instrument slowly, while keeping up a gentle pressure from behind, until we find a position in which it no longer encounters opposition, but yields to the pressure which tends to drive it farther inward toward the naso-pharynx. As we wish the instrument, on first reaching the cavity, to lie with its beak turned directly downward, we should begin at once, after passing the obstacle referred to, to rotate the catheter back toward the desired position. If we fail in our efforts to overcome the obstacle encountered, we must either resort to an instrument of smaller diameter, or try to reach the Eustachian tube by way of the nasal passage of the opposite side. The latter course will usually be found the preferable one. When the catheter is in the naso-pharyngeal space, with its beak turned directly downward, we should first make sure of our bearings by pushing the instrument onward until we feel the resistance offered by the posterior pharyngeal wall. When the catheter is in this position, we know that if we rotate it far enough we shall carry the beak into what is known as Rosenmüller's fossa, a slight depression located



just behind the mouth of the Eustachian tube. Hence, if we wish to introduce the instrument into the latter cavity, we must draw it back a distance of two or three-eighths of an inch, and then rotate it through an arc of about one hundred and thirty-five degrees (or until a line drawn through the plane of the ring attached to the catheter shall pass through the outer angle of the patient's eye). If we rotate the beak of the catheter first into Rosenmüller's fossa, and then draw it back a short distance, we can often feel the end of the instrument pass over the rounded eminence (Tw in Fig. 32) which constitutes the inner lip of the

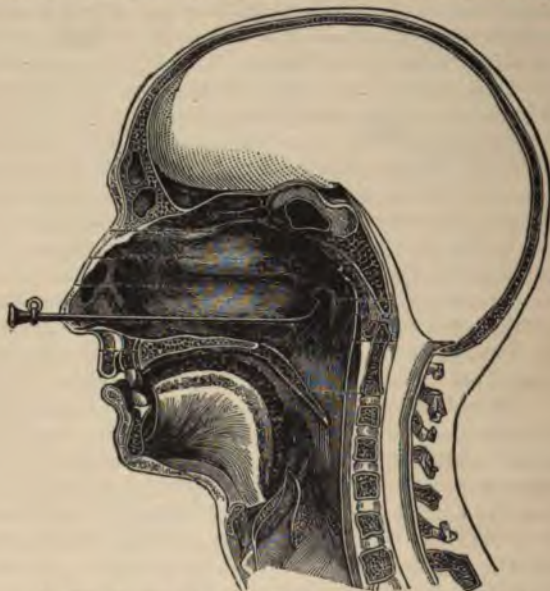


FIG. 33.—Eustachian Catheter in position. (After Politzer.)

mouth of the Eustachian tube. As the distance of the tubal orifice from the posterior pharyngeal wall varies in different individuals, the method last described, of guiding our movements by aid of the sense of touch, rather than by rough estimates of distance, is the one to which most aurists, I think, give the preference. In some individuals the landmark which I have just described is so feebly developed, or the surrounding parts are so swollen, that the operator feels doubtful whether he has reached the mouth of the tube or not. In such cases the Giampetro-Löwenberg method will be found useful. According to this method, the catheter is to be rotated toward the Eustachian tube of the opposite side, and when its beak occupies a horizontal



position, as indicated by the metal ring, the instrument is to be drawn forward until the resistance of the posterior edge of the septum is encountered. The catheter is then to be rotated in the opposite direction, through an arc of at least one hundred and eighty degrees, into the mouth of the Eustachian tube which it is desired to reach. In all three methods, but especially in the one last described, the physician would do well to grasp the body of the catheter with the thumb and forefinger of the left hand before he performs the act of rotation with his right hand. In any event he will have to grasp it in this manner after the instrument finally reaches its proper position, as the right hand will be required for other purposes. The support thus afforded to the catheter is a very firm one, as the last three fingers of the left hand find a strong resting-place on the bridge of the patient's nose, or on the lower part of his forehead. (Fig. 34.) So long as the operator's fingers press firmly against the patient's skull, he need have very little fear of the disturbing influence of a sudden motion of his head upon the position of the catheter.



FIG. 34.—Showing how the Catheter is to be held in position firmly and how the inflation bag is to be used in forcing air into the catheter. (After Politzer.)

When the physician believes that the beak of the instrument is lying in the mouth of the Eustachian tube, he should give the patient one end of the auscultation tube to place in the meatus of the corresponding ear, and should fix the other end tightly in his own auditory canal, preferably the left one.<sup>1</sup> With his right hand he should then grasp the rubber bag, and apply the hard-rubber nozzle of the instrument to the mouth of the Eustachian catheter. If the latter instrument is in the right position, and the Eustachian tube is not unnaturally contracted, he will hear the air streaming as it were into his own ear. If the catheter, however, occupies a wrong position, he will probably still hear the air streaming out of the end of the instrument, but it will no longer seem to be escaping into his own ear; the sound will appear to be more distant and less distinct.

In withdrawing the catheter from the nasal cavities, no special

<sup>1</sup> If the presence of the instrument in the naso-pharyngeal space causes the patient great discomfort, and especially if the act of swallowing is accompanied by pain, the physician may safely assume that the beak of the catheter is not lying in the mouth of the tube.

precautions are necessary. The instrument is first to be rotated back to its original position, with the beak pointing downward, and then it is to be withdrawn gently from the nose.

So far as the operation of crossing over from one nasal passage to the Eustachian tube of the opposite side is concerned, very little need be said in addition to the preceding account. On the whole, I think the operation is somewhat easier to perform than the ordinary mode of reaching the tube. It is simply necessary to use a catheter with a curve of slightly greater length, in correspondence with the greater distance of the tubal orifice from the nasal passage through which the instrument is passed. In all other respects the precautions to be taken are precisely the same as those which have been recommended for the more direct operation.

In former years I experimented with catheters having a double curve, and thought at the time that in certain cases they enabled me to accomplish that which I had failed to do with the ordinary single-curved instruments. During the past ten years, however, I have used only the latter variety of catheters, and do not remember to have felt the want of the others a single time. Those interested in the subject will find a full description of these double-curved catheters, by Dr. Henry D. Noyes, of this city, in the Transactions of the American Otological Society for 1870. In the volume for 1872 a description will also be found of the so-called "faucial catheter," an instrument devised by Dr. Oren D. Pomeroy, of this city. I have had no personal experience with the use of this instrument, and must confess that I am prejudiced, on *a priori* grounds, against its employment.

Besides the methods I have already mentioned, there are other ways of ascertaining the condition of the pharyngeal end of the Eustachian tube. Thus, for example, in a few cases it is possible, by means of a Gruber's speculum introduced as far as possible into the nasal passage, and reflected light, to obtain a fair view of the mouth of the Eustachian tube. The mirror, however, must not be used in the manner which I have recommended (p. 12) for examinations of the ear; success can only be obtained when the eye of the observer is placed at the central aperture. This direct method of observation has been still further perfected by the invention of what are known as Zaufal's specula, which may be carried in even to the very entrance itself of the tube. In many cases a good view of the tubal orifice and adjacent parts can be obtained by means of the laryngeal mirror and reflected light. Finally, a very good idea of the condition of the nasopharyngeal mucous membrane, and of the relations of the surrounding parts to the tubal orifice, may be formed from an exploration of this region with the forefinger (by way of the mouth).

## CHAPTER VI.

### DISEASES OF THE MIDDLE EAR.

*Classification.*—The great majority of diseases of this part of the ear are essentially inflammatory in character, and with scarcely an exception they originate in an inflammation of the vault of the pharynx. The so-called "cold in the head" is characterized by the very striking feature that it travels, like erysipelas, from the area first affected (the nasal or the naso-pharyngeal mucous membrane) to the neighboring mucous membranes, which are all (it must be remembered) one and the same mucous membrane in all essential anatomical respects. In many cases it seems to skip the pathway leading to the middle ear, and to direct its course downward in the direction of the larynx. In others, however, and these are perhaps the most common, it travels upward through one or both Eustachian tubes. In this simple way, very nearly all the pathological conditions of the middle ear may be developed. For convenience' sake we divide these different pathological conditions and processes into so many "diseases" and give to them such names as Eustachian catarrh, Stenosis or Narrowing of the Eustachian Tube, Catarrhal Inflammation of the Middle Ear, Purulent Inflammation of the Middle Ear, and various other names which are intended to emphasize the character of the inflammation or of its products, or the particular part of the middle ear chiefly affected, or the nature of the ultimate changes produced in the tissues by the inflammation. Syphilis and tuberculosis cause characteristic pathological alterations in the middle ear, and so does cancerous disease. These three middle-ear affections, therefore, are justly entitled to the right of being called separate and independent diseases; but such is not the case with regard to the others. I repeat, therefore, that the classification which I shall follow in discussing the pathology of the middle ear, is a purely arbitrary one, and is adopted simply for the purpose of securing something like order in the treatment of the subject.

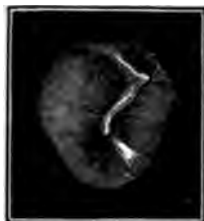

FIG. 35.—Normal Membrana Tympani (right ear). (After Politzer.)

*Eustachian Catarrh.*—I have already mentioned the fact that the mucous membrane lining the Eustachian tube and middle ear is in reality a continuation of that which lines the naso-pharyngeal space. A catarrhal inflammation of the latter region does not necessarily imply an extension of the disease to the Eustachian tube, but an inflammation of the Eustachian tube is scarcely to be thought of except in connection with a naso-pharyngeal catarrh. The ordinary "cold in the head," which is the commonest type of an acute naso-pharyngeal catarrh, rarely runs its course without involving at least a portion of the Eustachian tube. The subjective symptoms in this subacute form of Eustachian catarrh are: a sense of tightness or pressure in the ear of the side affected; a slight ringing noise; a sense of fulness in the ear after blowing one's nose; crackling noises during this act, and also during eating, swallowing, or gaping; slight diminution in the acuteness of hearing; and, finally, in some cases slight darting pains. The appearances presented by the membrana tympani vary according to the degree of obstruction which the swelling of the tubal walls offers to the ventilation of the middle ear, and also according to the duration of the state of obstruction. If the latter is slight in degree, the drum-membrane may present a perfectly normal appearance; if the walls of the tube are decidedly swollen, the air in the cavities of the middle ear soon undergoes absorption, and the tendency toward the establishment of a vacuum then produces well-marked changes in the appearance of the membrana tympani. In the first place, the membrane appears sunken or drawn inward beyond its natural position (Figs. 36 and 37). In addition to this the coloring of the membrane presents a deeper hue, which may border either on the purple or on the green, according to circumstances which I am unable to define with precision. In a general way, however, it may be said that the greenish hue is often an indication that fluid exudation has already taken place in the tympani.



FIG. 36.



FIG. 37.

FIG. 36.—Normal position of Drum Membrane. (After Hartmann.)

FIG. 37.—Drum Membrane drawn inward markedly. (After Hartmann.)

FIG. 38.—Another Instance of a Drum Membrane markedly drawn inward (After Politzer.)

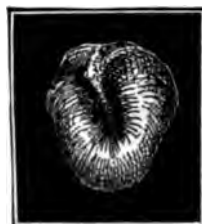 A black and white illustration showing another example of a retracted drum membrane, similar to Figure 37, with a deep, sunken appearance.


FIG. 39.—The same Membrane after Inflation. (After Politzer.)

FIG. 39.—The same Membrane after Inflation. (After Politzer.)

FIG. 39.—The same Membrane after Inflation. (After Politzer.)

nic cavity, while the purplish or red color simply furnishes evidence of a distended condition of the blood-vessels of the mucous membrane. When the changes have gone as far as this, we are no longer able to draw a dividing line between a Eustachian catarrh and a subacute catarrhal inflammation of the middle ear. In fact, the same observer would be likely to use either term indifferently, in a series of cases, without being able to give satisfactory reasons why he used one term in preference to the other.

So far as the course of the disease, its treatment, etc., are concerned, I think all these questions may be considered to greater practical advantage in the section relating to catarrhal inflammation of the middle ear (p. 152 et seq.)

*Other Pathological Conditions of the Eustachian Tube.*—We sometimes see cases in which, although other parts of the organ of hearing may be involved, the condition of the Eustachian tube constitutes the most salient feature of the pathological picture presented. For example, the tube may be found impervious to air, or it may be so widely patent that the slightest condensation or rarefaction of the air in the nasopharyngeal space causes a corresponding outward or inward movement of the drum-membrane. Again, paralysis or spasmodic contractions may take place in the muscles which cause the inner to separate from the outer lip of the pharyngeal portion of the Eustachian tube. Destructive processes may terminate in the binding together of these walls at the pharyngeal orifice. Finally, foreign bodies may find their way from the nose into the Eustachian tube. To each of these processes or conditions I will now devote a little space.

I have already alluded to the slighter degrees of *narrowing* which characterize a simple acute or subacute Eustachian catarrh. In this place I propose to consider only those cases in which the stenosis is more marked and permanent. The diagnosis of this condition is easily made by a simple inspection of the *membrana tympani* with speculum and reflected light. If the tube is completely impervious to air, and has been so for a sufficient length of time, the picture presented is a very striking one. The drum-membrane will be found lying like a thin, glistening film in close contact with the promontory, mouth of the Eustachian tube, anvil and stirrup. A deep depression posteriorly marks the vicinity of the entrance to the antrum. The lower end of the long process of the anvil and the head of the stirrup appear to project directly into the meatus. In fact, a superficial

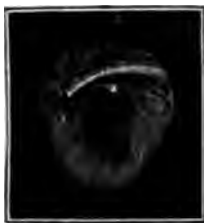

FIG. 40.—Position of the Handle of the Hammer in Complete Closure of the Eustachian Tube. (After Politzer.)

observer might easily be led to the conclusion that the *membrana tympani* had been destroyed, and that he was looking directly into the tympanic cavity. After inflation by Politzer's method the picture presented at the fundus of the meatus changes completely. The highly atrophied drum-membrane appears to be blown out in the form of a tomato; the depression caused by the immovable handle of the hammer corresponding with the hilus for the stem of the fruit. Finally, the small whitish prominence of the long process of the anvil will be found to have entirely disappeared from view.

Treatment is of very little avail in these cases of extreme atrophy of the drum-membrane. The *substantia propria* being entirely destroyed, the membrane no longer possesses the power of transmitting sonorous impulses to the handle of the hammer. In fact, the high degree of elasticity which such an atrophied membrane possesses renders it a positive obstacle to the transmission of such impulses to the labyrinth. Complete extirpation of the membrane, under these circumstances, would undoubtedly for the moment materially improve the patient's hearing: the sonorous impulses would produce a more decided effect, if they came in direct contact with the foot-plate of the stirrup than if the latter ossicle were enveloped in a soft, highly elastic membrane. However, if the drum-membrane, in these cases, has ceased to be of value for acoustic purposes, it still retains its protective power in almost undiminished degree. For this reason, and also for others which I will mention in another place, I am not in favor of interfering surgically in these cases. The question then presents itself, How much shall we gain—or rather, how much will the patient gain—if we succeed in restoring the Eustachian tube to a normal degree of patency? With a highly atrophied *membrana tympani*, the gain, I imagine, would at best be trifling. However this may be, I can only say that my efforts to restore the Eustachian tube to a normal degree of patency, in cases such as I have described above, have invariably proved unsuccessful.

I might state here that a highly atrophied *membrana tympani* possesses very little regenerative power. In one case (a fairly healthy young man, twenty-one years of age) I incised such an atrophied membrane on the twenty-seventh day of December. The edges of the wound, which was fully four millimetres in length, gaped widely apart. On the 30th I found the wound still gaping, and not a trace of inflammatory reaction could be discovered. On the 13th of January a free opening still existed in the drum-membrane. For how long a period it persisted afterward, I am unable to say.

In all, or nearly all, of these cases of prolonged closure of the Eustachian tube, we can scarcely fail to notice the condition of

the naso-pharyngeal cavity. Enormously enlarged tonsils, adenoid vegetations in the vault of the pharynx, or a more diffuse form of hypertrophy of the mucous membrane, will almost invariably be found to be present. If these conditions reach a high degree of development during the first years of life (from two to four, for example), they may produce not merely a sunken and atrophied condition of the membrana tympani, as the direct result of the prolonged closure of the Eustachian tube, but even, in a few cases, secondary lesions in the labyrinth, which may destroy the hearing-power altogether.

Although in the great majority of cases the obstruction to the entrance of air is due to a diffuse swelling of the walls of the tube, in a few cases a more localized lesion will be found. Thus, for example, I once had the opportunity, through the kindness of Dr. Goodwillie, of this city, of seeing a well-marked instance of closure of the pharyngeal orifice of the Eustachian tube by a band of connective tissue, which stretched like a bridge from one side of the orifice to the other. As I very rarely employ posterior rhinoscopy as an aid to diagnosis in diseases of the ear, I am unable to state how frequently such lesions are encountered. Dr. Goodwillie, however, assures me that he has seen several instances similar to the one which I have just described. In looking through the back numbers of the *Archiv für Ohrenheilkunde*, I find that two similar cases have been reported, one by Schwartze<sup>1</sup> and one by Lindenbaum.<sup>2</sup> Other instances are also mentioned by Schwartze in his treatise on the pathological anatomy of the ear.<sup>3</sup> In the same work will be found descriptions of other varieties of tubal lesions, with which I have had no personal experience.

*Unnatural patency of the Eustachian tube* is rarely encountered in practice. In two of the cases which have come under my observation the patient did not seem to be conscious that the ear was in any respect peculiar. Both patients consulted me for the relief of a slowly-increasing deafness, associated, in one case, with a distressing tinnitus. In the first instance I found a large, sharply-defined, oval cicatrix occupying the posterior inferior quadrant, and encroaching a little upon the superior quadrant. As I watched the drum-membrane, through the speculum, and by means of reflected light, I noticed that this cicatricial portion performed well-marked to-and-fro movements, which corresponded accurately with the patient's expiration and inspiration. When she held her breath, the cicatricial membrane remained perfectly motionless. Inflation by means of Valsalva's method

<sup>1</sup> Ed. I., S. 214.

<sup>2</sup> Ibidem, S. 296.

<sup>3</sup> Translated by J. Orne Green, M. D.; Houghton, Osgood & Co., publishers. Boston, 1878.

caused the cicatrix to protrude in the form of a well-defined hemispherical tumor, but as soon as the pressure was withdrawn, the cicatrix instantly returned to the plane of the surrounding membrane, and again performed its to-and-fro excursions, synchronously with the respiratory movements. In the second case, the entire membrana tympani presented a decidedly atrophied condition. The tip of the manubrium mallei was lacking. On questioning the patient I ascertained that in childhood she had been subject to a discharge from that ear. From these facts—viz., the absence of the end of the handle of the hammer, and the existence of otorrhea during childhood—I drew the conclusion that the unusually thin membrane was not, as I first supposed, an atrophied membrana tympani, but represented a newly formed drum-membrane. Whenever the patient performed the act of swallowing this cicatricial or newly formed membrane performed a distinct to-and-fro excursion. The respiratory movements, however, caused no visible excursion of the membrane. It is quite possible that, notwithstanding this absence of a respiratory excursion, the Eustachian tube was just as patent in this as in the first case. The much greater area of the cicatricial portion in the latter case would necessitate a correspondingly smaller excursion of any one portion of the membrane to which I might direct my attention,—an excursion probably too small for the naked eye to detect.

In seeking for a cause for the extraordinary patency of the Eustachian tubes in these two cases, we should bear in mind that both of them furnished unmistakable evidence of a pre-existing destructive inflammation of the middle ear. Instances are on record where such an inflammation caused the destruction of the lower wall of the osseous portion of the Eustachian tube, and eventually led to a fatal issue through ulceration of the walls of the carotid artery. If, however, the progress of such a destructive inflammation should be arrested before the carotid artery became involved, and if reparative action should then set in, I can see no good reason why an unnaturally patent Eustachian tube should not be the ultimate condition left when the ulcerated parts had fully healed. Again, I am not at all certain that an unnatural patency of the Eustachian tube may not result from a change in the relations of the soft parts which immediately surround this canal. Some years ago, while gaping, I suddenly discovered that I had unconsciously rendered one Eustachian tube unnaturally patent. I succeeded in keeping my jaw in this peculiar position long enough to satisfy myself that it was a possible thing to maintain the Eustachian tube in a perfectly patent condition for a shorter or longer time, according to the will of the experimenter. The rushing sound caused by the air as it passed



to and from the middle ear with each act of respiration, the easily felt to-and-fro movement of the drum-membrane, and the cool sensation caused by the moving current of air, all furnished unmistakable evidence of the existence, for the time being, of an open channel of some size between the naso-pharynx and the middle ear. I have often tried since to reproduce this condition, but have only succeeded partially. It is not an uncommon thing, however, for patients who suffer from chronic Eustachian catarrh, to learn the knack of twisting their jaws in such a way as to open, for an instant, the obstructed Eustachian tube, and in this manner to obtain relief from the sensation of pressure which many of them find so annoying.<sup>1</sup>

*In spasmodic contractions of the muscles of the Eustachian tube*, a positive diagnosis can scarcely be made without a rhinoscopic examination. At the same time, from the history of the case, and from the absence of any visible motion of the drum-membrane, we may infer that the peculiar snapping noises, which constitute the only appreciable symptom of the affection, are due to spasmodic contractions of those muscles which pull the inner wall of the mouth of the tube from the outer one. I have seen only a few instances of this affection. The history of one of these is given below. In this case, unfortunately, no contractions occurred during the short time which the patient spent at my office, and I was therefore unable to make a positive diagnosis. However, from the condition in which I found the drum-membrane, and from the account which the patient gave of his ailment, very little doubt could be entertained with regard to its nature.

The patient, an intelligent man about fifty years of age, and in apparently good health, gave the following history: About seven years previously he consulted a physician for deafness and a sense of fulness in the right ear, and the removal of a large mass of impacted cerumen gave him decided relief. During the following year or eighteen months he remained free from all aural symptoms. Then he began to experience, from time to time, peculiar crackling or rattling noises, which followed each other in quick succession like a series of taps, but never lasted longer than a few seconds at a time. He compared the sounds to the pattering of rain upon a tin roof. For a period of at least five years he had continued to experience these spasmodic noises, but had never before consulted a physician for the purpose of obtaining relief from his troublesome ailment. On examination I found both drum-membranes very nearly normal in appearance. The hearing, for the tick of the watch, was reduced to about 12 inches. There was no evidence of anything like an active naso-pharyngeal catarrh, although the diminution in the hearing power was probably to be attributed to the effects produced by this disease

<sup>1</sup> For additional information on this subject see vol. I. of the *Archiv für Ohrenheilkunde*, pp. 96 and 139 (Reports of Cases by Lucae and Schwartz).

during some earlier period of its activity. (The patient was not seen again.)

Cases have been reported in which the snapping noises were associated with synchronous, easily recognizable excursions of the drum-membrane. From this circumstance two inferences have been drawn: first, that the excursions observed were due to spasmodic contractions of the tensor tympani muscle; and second, that the noises heard were due to the sudden vibrations which these spasmodic contractions of the tensor tympani muscle produced in the drum-membrane. The latter inference is at variance with certain well-established facts. For example, in inflating the middle ear according to Politzer's method we cause just such a sudden excursion of the drum-membrane to take place as that which would follow a spasmodic contraction of the tensor tympani muscle; and yet I do not remember ever to have heard, under these circumstances, any noise that could be attributed solely to the motions of the drum-membrane. A parchment-like transformation of this membrane might possibly render its more violent excursions distinctly audible; but in the case reported above, and also in the few published cases to which I have had access, no such parchment-like condition of the membrana tympani existed. In the next place, in Schwartze's account of a case<sup>1</sup> of "spasmodic contractions of the tensor tympani muscle," it is distinctly stated that on inspection of the pharynx, during the occurrence of these spasmodic contractions, the soft palate was seen to rise and fall involuntarily, and synchronously with the noises. In this case, therefore, we cannot exclude the possibility that the noises were produced by the spasmodic separation of the pharyngeal lips of the Eustachian tube, and not by the visible excursions of the drum-membrane. In fact, it is not satisfactorily demonstrated in this or in any of the other published cases of which I have any knowledge, that the excursions observed in the drum-membrane were really due to contractions of the tensor tympani muscle. The question naturally suggests itself in this connection, Why might not these excursions of the membrana tympani have been produced by the alternate states of rarefaction and condensation of the air in the middle ear, which the spasmodic contractions of the tubal muscles caused? The answer might be made that in the published cases of spasmodic objective noises of clearly tubal origin, the membrana tympani invariably remained motionless. This evidence seems to me simply to justify the conclusion that in these cases the spasmodic contraction of the tubal muscles did not suffice—probably by reason of the swollen condition of the mucous lining of the tube

<sup>1</sup> Archiv für Ohrenheilkunde, II. Bd., S. 4.

—to cause any disturbance in the condition of atmospheric pressure within the middle ear. If we could readily and safely divide the tendon of the tensor tympani muscle in those cases of this class which are accompanied by visible excursions of the drum-membrane, we should possess the means of settling this disputed question in every doubtful case. Without this operation, however, I do not see how we can, with any degree of positiveness, pronounce a case to be one of spasmodic contractions of the tensor tympani muscle.

A very full discussion of this whole subject will be found in Burnett's Treatise on the Ear.<sup>1</sup>

A few years ago Edward Woakes, of London, published a paper<sup>2</sup> in which he expresses the opinion that a loss of power in the palato-tubal muscles (the levator and the tensor palati molliis) may play an important part in diminishing the acuteness of hearing. He describes two classes of cases, one with unilateral and the other with bilateral paresis. The lack of symmetry in the motions of the soft palate enables one easily to recognize the latter form of paresis, while the chief characteristic of the bilateral form is a marked absence of sensitiveness on the part of the soft palate and uvula. Speaking of the nature of these forms of paralysis, Dr. Woakes says that it is certainly not to be referred to a central origin. "On the contrary, these cases belong essentially to loss of vaso-motor nerve-power affecting one or more ganglia of the sympathetic system." Farther on, he says: "These vaso-motor pareses are very local in their manifestations, and depend entirely on the condition of the nervi vasorum of the nutrient arteries of the motor sensory nerves, and not at all on the condition of the sensori-motor centres. It is a question of nutrition of the muscular nerves themselves, and this depends on the blood-supply, which again is regulated by the vaso-motor nerves. These patients are often anæmic and have undergone mental worry, besides physical wear and tear. Under such circumstances, the nerve-force is readily exhausted, especially that of the sympathetic system. Some particular ganglion parts with its force more readily than the rest. It is like an exhausted galvanic cell; you must recharge it before it will act. But while thus waiting for recharge, the coats of the vessels it should control become the play of physical forces, and under the influence of the heart's impulse they stretch and are distended with blood. This interferes with the nice balance between arterial tension and tissue demand which is essential to nutrition, and hence malnutrition results as far as the nerve-tissue is concerned, and hence

<sup>1</sup> Published by Henry C. Lea, Philadelphia.

<sup>2</sup> Throat-Deafness associated with Paresis of the Palato-Tubal Muscles, *American Journal of Otology*, vol. I., No. 4, 1879.

there is defective motor function. Mechanical pressure exerted upon the motor fibrillæ is an important factor in the production of this paresis, and is due to the great accession of blood within the nerve-sheath when the nutrient vessels, being deprived of their inhibitory control, experience an enormous dilatation of their calibre." This description of the pathology of paresis of the palato-tubal muscles is followed by an account of a case illustrating the bilateral form of the disease. From this account it appears that in all but two respects this case is identical with a not uncommon type of catarrhal inflammation of the middle ear and Eustachian tube. The points of difference are these: the previous history of the case certainly justified the assumption that an element of nerve-exhaustion entered into the etiology of the apparently local disease; and in the second place, inspection of the soft palate revealed the fact that a marked loss of power had taken place in its component muscles, a loss of power so great "that a strong faradic current applied to the palate excited no muscular action, and was scarcely felt by the patient."

Until I had read Dr. Woakes's interesting paper, I was not aware of the existence of any form of aural affection in which paresis of the palato-tubal muscles—and probably also of the tensor tympani and stapedius muscles, which are supplied by the same nerves—constituted the prominent feature of the disease. For some time afterward I took pains to examine all my cases of subacute catarrhal inflammation of the middle ear, depending apparently on a similar state of the naso-pharyngeal mucous membrane, with special reference to the pathological views which Dr. Woakes has put forward in the paper referred to above. I failed, however, to discover a fairly well-marked instance of deafness of recent date which appeared to me to depend upon paresis of the palato-tubal (and intra-tympanic) muscles. In several of the cases the previous history pointed very plainly to nervous exhaustion—by which expression I mean prolonged mental worry and lack of rest—as an important factor in the causation of the deafness, but in none of these was I able to demonstrate any muscular paresis of the soft palate. In two instances I found this organ and the naso-pharyngeal space so lacking in sensitiveness that I was able to paint the entire region bordering upon the tubal orifices with a twenty-grain solution of nitrate of silver in a perfectly deliberate manner. This procedure, which ordinarily causes the muscles of this region to contract strongly the instant the parts are touched, excited no muscular reaction whatever: the soft palate remained perfectly motionless and relaxed. On the other hand, when these patients said "ah" or "ee," the soft palate rose promptly and symmetrically, showing clearly that no very decided degree of muscular paresis existed.

I have often thought that the difficulty sometimes experienced in inflating the middle ears of elderly people by Politzer's method must be largely due to a paretic condition of the muscles which open the tubes. The correctness of this view is rendered probable by the fact that often, in such a case, when air is forced into the Eustachian tube by means of the catheter, it is heard to enter the middle ear through a channel of normal size. The success of the inflation in Politzer's method is dependent in great measure upon the co-operation of the dilator muscles of the tube; on the other hand, in inflation by means of the catheter, this muscular co-operation is lacking, and the degree of success is directly proportionate to the force of the current of air driven through the catheter. The degree of force attainable by the latter method is much greater than that which can be attained by Politzer's method. It is therefore easy to understand how, in these cases of (assumed) paresis of the tubal muscles, inflation by Politzer's method fails to overcome the inertia of the more or less rigid walls of the tube, and to force air into the middle ear; while by catheterization no difficulty whatever is experienced in accomplishing this object. In further justification of this view I might mention the fact that post-mortem examinations of the tubal muscles have in certain instances revealed the existence of a high degree of fatty degeneration.<sup>1</sup>

In the matter of treatment, Dr. Woakes lays great stress on the importance of administering such remedies as steel, phosphorus, hydrobromic acid, and cod-liver oil. "Phosphorus, steel, and hydrobromic acid possess a definite relationship to the vessel area innervated by the ganglia whose defective action produced the phenomena of paresis described in the former part of this paper. Their action is to increase the inhibitory power exercised by the ganglia over the vessels from which it had been withdrawn, and when this is restored, an involution process as regards the morbid effects of its absence at once commences, which speedily ends in the removal of the symptoms. This appears to be the rationale of the action of so-called 'nervine tonics.' The therapeutic effect of the salts of ammonia is essentially of this character, and was illustrated in the case of another patient in whom palatal paresis of the left side existed to a very marked extent, without deafness, but with loud tidal noises in the left ear, and to whom I gave five-grain doses of sesquicarbonate of ammonia three times daily, with the result that all the symptoms disappeared in a fortnight." In addition to the internal treatment, Dr. Woakes recommends the employment of the induced current, in the following manner: "One pole should be applied to the veil of the palate

<sup>1</sup>See, for example, a paper on this subject by Weber, in the *Monatschrift für Ohrenheilkunde*, III., 4, 1889.

posteriorly, for which purpose the laryngeal electrode is very suitable; the other, an ordinary sponge-holder, is placed outside the neck over the superior cervical ganglion, which is reached by making deep pressure behind the angle of the jaw."

#### ACUTE AND SUBACUTE INFLAMMATION OF THE MIDDLE EAR.

An acute or subacute inflammation of the middle ear may run such a variety of courses and may produce such different lesions that, for the sake of convenience, at least, if for no other reason, it will be found easier to describe these different pathological pictures as so many distinct types of disease. Thus, for example, we can make two main subdivisions, the *catarrhal* and the *purulent* forms of *acute inflammation of the middle ear*. The *catarrhal* form, again, may be subdivided into the following subordinate yet well marked types: *simple acute* and *subacute inflammation* (otitis media catarrhalis acuta et subacuta); *serous* or *mucous exudation into the middle ear* (hydrotympanum; otitis media serosa sive mucosa); and *hæmorrhagic exudation into the middle ear* (hæmotympanum; otitis media hæmorrhagica). The second main subdivision, the purulent variety of acute inflammation of the middle ear, may also be subdivided into a syphilitic, a tubercular, and a simple form; at the same time it should be stated that it is only in exceptional cases that we can recognize anything distinctly syphilitic or tubercular in the pathological changes that take place in an acute or subacute otitis media purulenta.

The same causes may produce at one time a catarrhal, at another a purulent form of inflammation of the middle ear, according to the degree of vigor with which they act, and also partly according to the condition of the ear, and of the general nutrition of the individual at the time of the attack. Among the different causes of an acute inflammation of the middle ear, the most frequent is undoubtedly a sudden chilling of the surface of the body. Next in order come the eruptive fevers, such as scarlet fever, measles, and small-pox. Typhoid fever, and perhaps also typhus fever, may give rise, occasionally, to an acute affection of the middle ear. A blow or a fall on the side of the head may lead to the same result by causing a diastasis or even a fracture of the bony walls of the tympanum. Direct violence to the parts may be followed by acute inflammation. The introduction of fluids through the Eustachian tube into the middle ear, either accidentally—during ocean-bathing, for example, or during the use of the nasal douche or one of its substitutes—or for therapeutic purposes, is very apt to be followed by a severe type of acute inflammation of the middle ear. Several years ago I published an account of several cases of acute otitis media, all of which

were brought on by flooding the nasal cavities by means of the nasal douche, the posterior nasal syringe, or the snuffing method. I then gave the opinion, in corroboration of that previously expressed by Dr. Roosa, that all these procedures, however carefully carried out, were not free from the risk of setting up an acute inflammation of the ear. While I should like to discuss this question more fully, I must rest content at present with the mere statement that my later experience has only served to strengthen the opinion expressed at that time. Finally, in children the internal administration of quinine sometimes gives rise to an acute or subacute inflammation of the middle ear. I have seen several such cases, and in two of them (from three to five years of age) I was able to study the changes in the ear at such short intervals of time that I could no longer doubt the direct effect of the quinine upon the degree of fulness of the blood-vessels of the tympanum. As each additional dose of the drug was administered, the membrana tympani became more and more congested; and by the time six grains, in one instance, and eight in the other, had been taken, the child was in evident suffering from pain in the ear. No further doses were given, warm applications were made to the ear, and the pain soon subsided. In all of these cases there already existed before the quinine was administered, a slight tendency to naso-pharyngeal (and probably Eustachian) catarrh, as shown by the enlarged state of the tonsils and by the presence of an excessive amount of ropy mucus behind the soft palate. Hence I am not prepared to say that, in a perfectly normal state of the tympanic and tubal mucous membrane, quinine is competent to excite an acute inflammation, but simply that, in young children more particularly, this drug is capable of fanning a slight and perfectly painless tubal (and perhaps tympanic) catarrh into a fairly acute inflammation of these parts.

*General Symptomatology.*—The two main types of acute inflammation of the middle ear, the catarrhal, and the purulent, are characterized, up to a certain stage of the disease, by the same series of symptoms. It is only when the pressure of the fluid exudation within the tympanum causes the membrana tympani to rupture, that the distinguishing features of the purulent variety manifest themselves. On the other hand, in the catarrhal form, after the inflammation has reached its highest degree of activity, the subsequent course of the disease is characterized either by a gradual subsidence of all the symptoms, or by the development of certain conditions which justify the employment of the terms "hydrotympanum" and "hæmotympanum." The further symptomatology of the catarrhal and purulent forms of inflammation of the middle ear will be discussed in the following chapters.

## CHAPTER VII.

### ACUTE AND SUBACUTE CATARRHAL INFLAMMATION OF THE MIDDLE EAR.

THE symptoms which characterize a subacute catarrh of the middle ear are precisely the same as those which have already been enumerated under the head of Eustachian catarrh, viz., diminution in the acuteness of hearing, a sense of fulness in the ear, subjective ringing or singing noises, unpleasant resonance of one's own voice in the affected ear, subjective crackling noises when the nose is blown, and perhaps occasional twinges of pain. Any or all of these symptoms may be present in one and the same case.

So far as the *pathology* of the disease is concerned, in the great majority of cases the inflammation commences in the nasopharyngeal space and spreads thence to the middle ear through the Eustachian tube. A subacute Eustachian catarrh, with more or less swelling of the mucous membrane which lines the middle ear, would therefore represent the mildest type of inflammation of this region. The following case will serve as a good illustration of such a type of subacute catarrhal inflammation of the middle ear.

The patient, a young man twenty-two years of age, was seen, for the first time, at the New York Eye and Ear Infirmary, on the seventeenth day of May, 1871. He stated that about three weeks previously he began to experience difficulty in hearing, and that it steadily increased up to the time of visiting the Infirmary. It was accompanied by a slight ringing noise in the head, but there was no pain nor any other symptom sufficiently marked to attract his attention. He also stated that during childhood he had been subject to frequent earaches. At the time I saw him he was still able, under favorable circumstances, to understand ordinary conversation quite well. The hearing distance, as tested by the watch, was: R.  $7\frac{1}{2}$ ; L.  $11\frac{1}{2}$ . Both external auditory canals were perfectly normal. On the left side the membrana tympani was appreciably sunken, and through it the outlines of the long process of the anvil were distinctly visible. Essentially the same condition of the drum-membrane existed on the right side. The tonsils were moderately enlarged, and the entire pharyngeal mucous membrane presented an unnaturally red appearance. Inflation by Politzer's method caused air to enter the left middle ear, but not the right. A crackling sound characterized the entrance of the air into the left tympanum.



The hearing distance for the watch, on the left side, rose from  $f:f$  to  $f:f$ , as a result of the inflation.

The treatment consisted in mopping out the naso-pharyngeal space with a solution of nitrate of silver, of the strength of twenty grains to the ounce of water, and in inflations by Politzer's method. At first the catheter was used two or three times, on the right side, as a means of inflating the middle ear; but subsequently, as the swelling of the tube subsided, Politzer's method alone was found to be sufficient. The greater part of the time the patient visited the Infirmary only once a week, thus materially delaying his recovery. However, steady improvement took place in the condition of the parts and in the acuteness of the hearing. On the 1st of July, when treatment was discontinued, the hearing distance for the watch was: L.  $f:f$ ; R.  $f:f$ . On the 5th of August he reported that no relapse had occurred, and that he heard as well as ever before. As he had been subject to earaches during childhood, it is more than probable that his hearing, previous to the attack described above, was not normal, at least for sounds as delicate as the ticking of a watch.

The absence of pain, in the case just described, is the feature which characterizes it as a *subacute*, in contradistinction to an *acute* attack of inflammation of the middle ear. The comparatively long duration of the disease, and the incompleteness of the recovery, so far at least as the hearing is concerned, justify the assumption that the attack partook of the nature of an exacerbation of a pre-existing, but very slight naso-pharyngeal, Eustachian, and tympanic catarrh, and was not an entirely fresh attack, originating in an individual with perfectly normal ears. Had the affection been of the latter nature, the restoration of the hearing would have been perfect, and the total duration of the attack would have been much shorter. Such cases are quite common and I will therefore not stop to narrate an instance.

In a few cases of subacute catarrhal inflammation of the middle ear I have observed conditions which lead me to believe that the swelling of the mucous membrane may, in certain cases, be greatest at and near the tympanic orifice of the Eustachian tube. The most striking feature in these cases is the apparently contradictory relation which exists between the patency of the tube and the tensely bulging condition of the drum-membrane. This protrusion outward of the membrane, in the cases referred to, was clearly due to the presence of an excessively large volume of air in the cavities of the middle ear. In one of them I pricked the bulging membrane, whereupon it instantly resumed a perfectly natural position. As already intimated, no difficulty whatever was experienced in forcing air into the middle ear, and it appeared to enter it readily and without rales. A swollen condition of the tube at its pharyngeal orifice, or at any point along its course, would have interfered materially with the entrance of air into the tympanic cavity, and would have caused the drum-

membrane to occupy a depressed or sunken position rather than a bulging one. The presence of a small mass of mucus at the tympanic orifice of the tube, where it might perfectly well play the part of a valve, suggested itself as a condition that would explain the peculiar conditions observed. While I should not be justified in rejecting this hypothesis unconditionally, I am disposed to believe that a swollen condition of the mound-like tympanic orifice of the tube is the pathological condition which harmonizes best with all the symptoms and conditions observed in these cases. In the first place, in the case already referred to, the patient, for a period of nearly two weeks, experienced almost constantly a sensation of fulness or pressure in the affected ear. The prick made with the myringotome afforded instant relief, but it lasted only for a few hours. As this peculiar condition was associated with a marked naso-pharyngeal catarrh, I limited my treatment to tri-weekly paintings of this region with a solution of nitrate of silver, to counter-irritation over the mastoid process with tincture of iodine, and to inflations according to Politzer's method. During the third week the improvement was so rapid and so marked that treatment was discontinued. This experience, it seems to me, tallies with the hypothesis which I have put forward rather than with that of the accidental presence of a mass of mucus at the tympanic orifice of the tube. Had the latter been the true cause, the forcible inflations of air ought to have dislodged the mass at a much earlier period. Finally, it seems a little strange that if mucus were present I should have failed both by auscultation and by inspection to detect its presence in the tube or in the middle ear.

Closely connected with these uncomplicated cases of subacute catarrhal inflammation is another group of complicated cases in which the subjective symptoms and the pathological appearances of the membrana tympani are essentially the same as those which characterize the simpler cases. In the group referred to, a more or less permanent *obstruction of the nasal passages* constitutes a prominent and perhaps even the chief factor in the production of the deafness. So long as the nasal passages are perfectly unobstructed, the acts of breathing, gaping, swallowing, etc., all aid in properly ventilating the middle ear, that is, in restoring that equilibrium between the internal and external atmospheric pressure which is so essential to perfect hearing. When the nasal passages, however, become obstructed, the acts just mentioned produce, at frequent intervals throughout the day, a condition of rarefaction in the air of the middle ears. The effect is very nearly the same as that produced by obstruction of the Eustachian tube. In all the cases that I have seen, these conditions have been associated together in such a manner

that I have not been able to distinguish between the effects produced by the obstruction in the nasal passages, and those produced by the contemporaneous naso-pharyngeal, Eustachian, and middle-ear catarrh. I fully believe, however, that it is an important co-operating factor, and that permanent benefit can scarcely be attained in these cases so long as the nasal obstruction is allowed to remain.

In the class of cases just described the disease usually shows a tendency to pursue a chronic course. The *prognosis*—so far as the restoration of the hearing is concerned—will therefore depend on the degree of damage already done by the disease, our ability to overcome the obstructions in the nasal passages, and on various other circumstances. In the main the prognosis is not good. In the simpler cases of subacute catarrhal inflammation, on the other hand, the prognosis is unqualifiedly good.

*Acute Catarrhal Inflammation of the Middle Ear.*—An acute catarrhal inflammation of the middle ear differs from the subacute form chiefly in the fact of its being characterized by pain. Furthermore, in the higher degrees the lesions will be found to be more pronounced than in the subacute variety. Very many of the "earaches" of young children, from four to ten years of age, are due to such an inflammation of the middle ear. The pain is very apt to come on during the night or late in the afternoon, while during the earlier part of the day the child may be quite free from pain. As neither a discharge, deafness, nor any other serious result characterizes these earaches, the parents or friends are very apt to draw the conclusion that *all* earaches are equally harmless, and that they may be allowed to run on for days or even weeks without any effort being made to ascertain the real cause of the pain. I have repeatedly been called to see children who had been suffering from pain in the ear for several days, and in whom the inflammation of the middle ear and adjacent parts had already assumed serious proportions; and yet the thought of sending for a physician had apparently not entered the minds of the parents until after the inflammation had approached very near to the limit beyond which surgical interference is not competent to prevent serious damage. There is a widespread belief in the public mind that an "earache" is something which is quite harmless and entirely different from a genuine inflammation of the ear. This belief is favored by the well-recognized fact that the great majority of earaches spontaneously subside without inflicting any harm either upon the ear or upon the general health of the individual affected. In the small minority of instances, however, the earache is the warning note of a serious inflammation of the middle ear, that may damage or destroy the hearing, that may inflict a lifelong discharge from the ear upon

the sufferer, or that may even—in instances that are not so very rare—terminate in a fatal meningitis or abscess of the brain. How are the parents to tell, in the presence of a case of earache, whether it is to be one of the harmless kind or one of a more serious nature? The public should therefore be taught that there is but one safe rule to follow in all these cases, and that is, to consider every earache as worthy to be investigated and treated promptly in accordance with well-established therapeutical laws. The same line of thought leads me to remark that every general practitioner should be sufficiently skilled in the use of aural instruments to be able to find out just what is the nature and extent of the pathological process that is causing the earache.

In the milder types of acute catarrhal inflammation of the middle ear, the peripheral and manubrial portions of the drum-membrane, and especially the more fleshy parts which form the upper boundary of the membrane, will be found red and moderately swollen. If the disease has made sufficient progress, a crackling sound will probably be heard when air is forced into the middle ear. In the course of twenty-four hours, with or without treatment, all these threatening manifestations may disappear. In the more pronounced types of acute catarrhal inflammation, however, the redness and swelling do not remain confined to the peripheral and manubrial portions of the membrana tympani, but involve also the intervening portions. An exudation into the middle ear soon follows, and may even be so copious as to cause a bulging outward of the drum-membrane, more particularly the posterior half. All these changes may develop in the course of a single day, or they may not reach the stage last described until after the lapse of several days. If the disease, after reaching this stage, ceases its activity and gradually subsides, leaving behind, perhaps, an accumulation of serum or mucus in the tympanum, the diagnosis of an acute otitis media catarrhalis may still be retained on our records. But if it goes one step farther, the exuded serum or mucus will become purulent in character, and, with favoring conditions, a perforation will be established in the drum-membrane. From this time forward, until the perforation heals, the picture presented will be that of a purulent inflammation of the middle ear. Illustrative cases would scarcely add new light to the description already given of an acute otitis media catarrhalis, and I may therefore be permitted to omit them. There are certain cases, however, of which I should perhaps give a single illustration. I refer to a class of cases which, according to the definitions given of the two great classes of acute inflammation of the middle ear, belong properly to the catarrhal variety. They represent, in reality, aborted cases of acute purulent inflammation of the middle ear; that is

to say, the lesions are often as grave as they are in the worst forms of this variety, and yet, for some unknown reason, pus is apparently not formed, and recovery takes place without a perceptible discharge from the ear. The following case may serve as an illustration:

A young girl, six years of age, and in excellent general health, though subject more or less to naso-pharyngeal catarrh, was aroused out of her sleep one morning in April by a sharp pain in the right ear. Her mother, who had acquired some experience in treating the earaches of her other children, at once applied the warm douche and soon relieved the pain. In the course of the afternoon of the same day the child began to complain of pain in the left ear. An hour or two later I was sent for by the mother. On examination I found the left drum-membrane markedly congested throughout its entire extent, but not perceptibly bulging. On the right side a purplish tumor occupied the position of the membrana tympani. By aid of the slender probe I ascertained that an exudation of dark fluid blood had taken place between the substantia propria of the drum-membrane and its outer dermoid covering. As the child seemed to hear ordinary conversation perfectly well, and as the right ear was free from pain, I simply advised the mother to use the warm douche in the left ear in the same manner as she had already used it in the right ear. The pain in the left ear was relieved by the douche in a very short time. No discharge was observed at any time in the right ear, and the membrana tympani soon returned to a normal condition. A few inflations according to Politzer's method constituted the only treatment.

In a second very similar case I found a much larger blood-sac, and evacuated its contents. According to the account given by the child's mother, an oozing of blood from the outer orifice of the auditory canal continued for some time after she left the Infirmary. In this case, also, the drum-membrane returned to its normal condition without the development of an otorrhœa. The thought suggests itself, Was not the progress of the inflammation arrested by this comparatively copious, spontaneous local bleeding? I think it not unlikely that these attacks, which began so vigorously, were in each instance materially subdued in acuteness by the spontaneous hæmorrhage that followed.

With regard to the *prognosis*, it may be said that in the very great majority of instances it is good. Now and then a case proves rebellious under treatment, but as a rule perfect recovery follows in the course of two or three weeks.

So far as the *diagnosis* is concerned, an error is scarcely possible. The evidences of inflammation are too plainly marked for a careful observer to be easily misled in his interpretation of the conditions presented. The questions which suggest themselves to his mind are, first: Is this a simple catarrhal inflammation, or is it the beginning of a severe purulent inflammation? Mere inspection is not sufficient; the subjective symptoms, and especially

that of pain, must be weighed in connection with the condition of the drum-membrane. In children, the thermometer may aid us materially in arriving at a correct conclusion; in adults, it is of comparatively little value. The second question is, Is the red and swollen condition of the membrana tympani the expression of an inflammation which began originally in the middle ear, or is it due to an extension of a diffuse inflammation of the canal on to the drum-membrane? This is sometimes a difficult question to answer. If an inflammation of the middle ear has progressed so far as to involve the inner end of the external auditory canal, we may be quite sure of two things: there will be marked diminution of the hearing, and a history of rather severe pain. On the other hand, the insignificance of the pain and the slight impairment of the hearing are very striking features in those cases

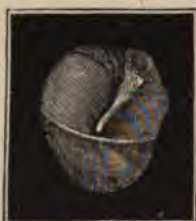

FIG. 41.—Collection of Serous Exudate in the Lower Part of Right Tympanum. The glistening curved line which crosses the picture represents the upper level of the fluid. (After Politzer.)



FIG. 42.—The Same Condition, as seen in another patient. In this case the line of the upper limit of the fluid is wavy. (After Politzer.)



FIG. 43.—Appearance of the Drum Membrane (same case as that shown in Fig. 42) when the patient's head is thrown far backward. The line of the fluid now runs nearly parallel with the handle of the hammer, instead of at right angles with it.—(After Politzer.)

where the inflammation of the auditory canal is the primary affection, and that of the drum-membrane merely a secondary affair. In exceptional cases, marked pain and decided impairment of hearing may characterize the type of disease last mentioned. Under such circumstances it may not be possible to arrive at a correct diagnosis without further observation of the course which the disease pursues.

*Mucous or Serous Exudation into the Middle Ear (Hydrotympa-  
num; Otitis Media Serosa sive Mucosa).*—The accumulation of a serous or mucous fluid in the tympanic cavity may be brought about in two or three different ways. In the first place it may be a simple *hydrops e vacuo*, due to the closure of the Eustachian tube, and to the subsequent absorption of the air that may have remained in the middle ear. The pressure being, under these circumstances, withdrawn from the walls of the blood-vessels of the middle ear, they give up their watery contents to a variable

extent, according as the tendency to a vacuum is greater or less. The fluid found in the middle ear in these cases is a thin, yellowish serum, with just enough admixture of mucus to render the fluid slightly sticky. An ordinary cold in the head, when it involves the Eustachian tube, and practically closes it for a short time, may produce this very condition of hydrotympnum, without even robbing the membrana tympani of its transparency. Again, the exuded fluid may represent a hypersecretion of the glands with which the tympanic mucous membrane is provided. Finally, in many cases probably both of the factors mentioned cooperate in producing the fluid exudation.

In the main the *symptomatology* of these cases is the same as that of the ordinary cases of subacute catarrhal inflammation. There are certain symptoms, however, which of themselves are almost sufficient to warrant a diagnosis of fluid exudation into the middle ear. One of these is, the sudden change from somewhat poor to good hearing, or the reverse. This change is not like that which so often occurs in cases of impacted cerumen, where the brief return of the hearing is accompanied by an explosive sound, due to the sudden restoration of a communication between the body of air lying between the drum-membrane and the ceruminous mass, and that which lies outside of the latter; the hearing either simply becomes clouded, or, in an equally quiet manner, the cloud seems to disappear.

These changes in the hearing are clearly due to changes in the position occupied by the fluid. In a few cases the patient is able to state definitely in what positions of the head the hearing seems to be normal. These are most commonly the position with the head thrown far backward (fluid escapes into the antrum), and that with the head bent far forward. In both of these positions the fluid, if not too viscid and if not too copious, will, in obedience to the law of gravity, flow away from the oval and round windows, thus leaving the ossicles and the membrana tympani secundaria free to perform their functions properly.



FIG. 44.—Marked partial Retraction of the Middle of the Right Membrana Tympani, in a case of chronic catarrhal otitis. The lower portion is in about normal position, and the manubrium and upper part are not greatly indrawn; while the middle portion is so abruptly retracted as to form a sharp "knee" overhanging the dark depressed area above it, and give rise to a glistening line across the membrane near its middle and closely simulating the surface line of an exudate in the cavity. In front of the manubrium is visible a whitish undefined thickening. (After Randall.)

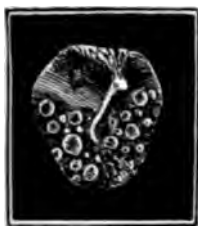

FIG. 45.—Foamy Secretion in the Tympanum after Inflation, in a case of serous accumulation. From a patient with acute naso-pharyngeal catarrh. (After Politzer.)



Another symptom which is peculiar to these cases, is the sensation of something moving in the ear. This is of course not felt when the head is quiet, but simply when the head is moved rather suddenly. Sometimes the patient gives a correct diagnosis of his condition in the very first words of his complaint: "I went in bathing, and got some water into my ear; and I am unable to get it out." He imagines, as a matter of course, that the water found its way into the ear by way of the external auditory canal; whereas the chilling of the surface of the body, or the accidental entrance of water into the middle ear by way of the Eustachian tube, has caused an exudation of fluid to take place in the tympanum in one of the ways already described. Finally, subjective crackling, squeaking, and bubbling sounds may be due to the presence of free fluid in the middle ear; they are just as likely, however, to owe their origin to an abnormally moist condition of the Eustachian tube. Of more decided value is the symptom of hearing gurgling sounds in the ear during the acts of coughing, sneezing, and swallowing.

The *course* of the disease is a very variable one, although in the majority of instances the fluid exudation is soon absorbed and the ear returns to a normal condition. Among the following cases will be found instances of probably all the types of serous exudation into the middle ear which the physician is likely to encounter in practice.

CASE I.—The patient, a man thirty-five years of age, had a few days previously caught a slight cold in the head, and had thenceforth experienced a sensation of fulness in the left ear. When he consulted me on the 13th of May, 1879, I found the left drum-membrane slightly congested at the periphery. Just below the umbo (the lower end of the handle of the hammer) a curved line was visible, which stretched from the anterior to the posterior periphery of the membrane. In whatever position the patient's head was placed, this curved line (with its concave side looking upward) maintained its horizontal position, thus showing clearly that it represented the upper boundary of a mass of free and rather thin fluid. Under treatment this pathological condition disappeared in about two weeks, and the hearing returned to its normal degree of acuteness.

CASE II.—The patient, a boy eight years of age, had been somewhat hard of hearing, as the mother believed, for about one year. At times, she said, he seemed to hear quite well, and then the deafness would return and last for a variable period. When I saw the boy at the Infirmary, on the 12th of October, 1870, his right membrana tympani presented no features worthy of special note in this connection. On the left side, the drum-membrane was noticeably sunken, but not congested nor lacking in a fair degree of transparency. In the posterior half of the membrane there was a sharply defined "fluid line," running from the umbo across the intervening space to the posterior periphery. Anteriorly, the limits of the fluid could not be defined. Moist râles were heard during inflation. "Fluid line" disappeared after in-



flation. Decided naso-pharyngeal catarrh. Hearing distance for the watch before inflation R. 2 in., L. 2 in.; after inflation, R. 24 in., L. 15 in. Whispered words were heard distinctly a much greater distance after inflation than before it.

The boy visited the Infirmary for treatment twice a week, for a period of four weeks. The fluid had by that time disappeared from the left middle ear, and the hearing, for the watch, remained steadily at twenty-four inches. On the right side, however, no perceptible improvement in the hearing had taken place.

These two cases are placed side by side because the former represents a purely fresh attack in a person whose ears had been previously healthy, while the latter furnishes a good instance of the development of hydrotympanum in an individual whose ears had been for months affected with chronic catarrhal inflammation. Furthermore, they both represent the slighter degrees of fluid exudation into the middle ear.

CASE III.—A gentleman, sixty-nine years of age, but in vigorous health, consulted me on the 9th of December, 1876, for a decided loss of hearing in his right ear. He first discovered the defect about six weeks previously, while suffering from a severe cold in the head. On examining the ear I found that the membrana tympani was decidedly sunken. Anteriorly a "fluid line" ran directly across from the umbo to the anterior periphery of the membrane. Posteriorly the uniform dark coloring of the membrane showed clearly that the fluid in this region rose to at least the height of the upper limit of the membrane. As the long process of the anvil lay almost in contact with the membrana tympani, its whitish body stood out in marked contrast with the deep slate color of the surroundings. Inflation by Politzer's method changed the entire picture. The fluid line, which before was visible only in the anterior half of the membrane, now stretched like a festoon from periphery to periphery. The long process of the anvil had also completely disappeared from view.

Under treatment this mass of fluid was dissipated—whether wholly by absorption, or partly by absorption and partly by dislodgement, I am unable to say—in less than two weeks, and the hearing returned apparently to its former standard of acuteness.

On first thought it may seem rather strange that in the posterior half of the cavity of the tympanum (in the case just narrated) the level of the fluid should rise at least to the height of the upper boundary of the drum-membrane, while in the anterior half the level should correspond with that of the umbo or central point of the membrane. This difference, however, is simply due to the effects of capillary attraction. The close proximity of the long process of the anvil to the posterior half of the membrana tympani supplies precisely the conditions which are necessary to develop the effects of capillary attraction, that is, to lift the apparent level of the fluid in this region to the highest limits of the drum-membrane.

CASE IV.—This patient, a young man twenty-eight years of age, contracted a bad cold in the head ten days previously, and shortly

few cases, mucus should predominate over serum in the exuded material, unless it be that in such cases the mucous glands of the middle ear are subjected to a higher degree of irritation than is usually the case. I have noticed, for example, that a purulent inflammation of the middle ear, with perforation of the membrana tympani, occasionally terminates in an accumulation of mucus in that cavity; the perforation apparently healing before the mucous membrane of the middle ear has had time to return to a fairly healthy state. At the same time a simple catarrhal inflammation of the middle ear, such as is commonly found to be the cause of the accumulation of serum in the tympanic cavity, is often also the cause of an accumulation of mucus. Furthermore, in its *symptomatology* this type of middle-ear disease is essentially the same as the one which we have just been considering. It is more apt, perhaps, to run a chronic course than is the serous variety of effusion. So far as the *diagnosis* is concerned, there are several features which justify the physician in suspecting that the effusion is mucous rather than serous in character. In the first place, râles are an almost necessary phenomenon in cases of serous accumulation, unless the fluid be too scanty in quantity to reach the level of the tubal orifice. In cases of an accumulation of mucus, it is perhaps the exception for râles to be heard; in fact the air, forced into the Eustachian tube by inflation, does not seem to reach the cavity of the tympanum at all. In the second place, the appearance of the drum membrane in cases of otitis media mucosa is usually quite different from that observed in well-marked cases of otitis media serosa. It often has a peculiar dead, milky, opaque appearance, which, unfortunately, is sometimes also observed in cases of the serous variety. Hence, without paracentesis of the membrane, we can scarcely do more than entertain a strong suspicion that the case is one of an accumulation of mucus in the tympanic cavity. After paracentesis has been performed, and the exuded material has been forced through the perforation into the auditory canal, it becomes, of course, an easy matter to make an absolute diagnosis.

As I shall have occasion, in the section relating to treatment, to refer to the course which these cases pursue, I may be permitted to omit all farther reference to the subject in this place.

*Hæmorrhagic Exudation into the Middle Ear.*—There are two classes of cases to which the expression just employed may be applied with equal justice, viz., those of acute catarrhal inflammation in which, during the first onset of the disease, a hæmorrhage occurs from some vessel in the middle ear, and those in which a serous fluid, deeply tinged with the coloring matter of the blood, finds its way into the tympanic cavity through other than inflammatory causes. Instances of the latter form of dis-

afterward began to experience a sense of fullness in the right ear, and diminished acuteness of hearing. When I examined his right ear at the Infirmary, on the 2d of November, 1870, I found the drum-membrane of a peculiar, dull hue, and almost directly in the centre of the posterior half the perfectly round outlines of a bubble of air, perhaps a millimetre and a half in diameter, were distinctly visible. This bubble seemed to be prevented from rising to a higher level by some unseen object—undoubtedly the end of the long process of the anvil and the head of the stirrup. The motions of the patient's head caused it to move slowly from one position to another, but only a very short distance. (No further notes of the case.)

It is perhaps more common to find several bubbles lying behind the drum-membrane. I remember, in a few instances of hydrotyimpanum, to have seen (after inflation) the cavity of the tympanum apparently filled from top to bottom with bubbles, which glided over each other like so many balls of some polished metal. (See Fig. 45.) The first time I saw this phenomenon I was persuaded that I must have overlooked a minute perforation in the membrana tympani, and that the mass of bubbles lying before me was resting against the outer and not the inner surface of the membrane. By employing a small mop of cotton, however, I was able speedily to satisfy myself that the bubbles were confined within the tympanic cavity.

CASE V.—The patient, a marketman, thirty-one years of age, came to the Infirmary on the 4th of February, 1874. He complained of deafness and occasional tinnitus, of several months' standing. Recently, he said, he had sometimes observed gurgling sounds in the left ear, and had also noticed that when he threw his head far backward, he could hear decidedly better than when he held it in the natural upright position. I examined the left ear and found the membrana tympani appreciably sunken. Instead of a delicate, hair-like "fluid line," a rather broad yellow band crossed the lower half of the membrane. At the umbo this band was caught up like a festoon. Below it the color of the drum-membrane was like that of slate. Changes in the position of the head caused corresponding changes in the position of this band. A free vertical incision was made in the posterior half of the membrane, and inflation by Politzer's method was resorted to. In this way quite a large quantity of fluid was evacuated from the tympanic cavity,—fluid which, in no respect that I could discover, differed from that found in cases which are characterized by the presence of the delicate, hair-like, "fluid line." The evacuation of the fluid contents of the middle ear increased the acuteness of the hearing very noticeably, and three days later, when he returned to the Infirmary, I found that this gain had increased rather than diminished.

In all the five cases which have just been described, the fluid found in the tympanic cavity was almost purely serous in character. So far as my experience goes, it is only in comparatively few cases that the exuded fluid is found to consist largely or entirely of tough, tenacious mucus. I do not know why, in these

few cases, mucus should predominate over serum in the exuded material, unless it be that in such cases the mucous glands of the middle ear are subjected to a higher degree of irritation than is usually the case. I have noticed, for example, that a purulent inflammation of the middle ear, with perforation of the membrana tympani, occasionally terminates in an accumulation of mucus in that cavity; the perforation apparently healing before the mucous membrane of the middle ear has had time to return to a fairly healthy state. At the same time a simple catarrhal inflammation of the middle ear, such as is commonly found to be the cause of the accumulation of serum in the tympanic cavity, is often also the cause of an accumulation of mucus. Furthermore, in its *symptomatology* this type of middle-ear disease is essentially the same as the one which we have just been considering. It is more apt, perhaps, to run a chronic course than is the serous variety of effusion. So far as the *diagnosis* is concerned, there are several features which justify the physician in suspecting that the effusion is mucous rather than serous in character. In the first place, rales are an almost necessary phenomenon in cases of serous accumulation, unless the fluid be too scanty in quantity to reach the level of the tubal orifice. In cases of an accumulation of mucus, it is perhaps the exception for rales to be heard; in fact the air, forced into the Eustachian tube by inflation, does not seem to reach the cavity of the tympanum at all. In the second place, the appearance of the drum membrane in cases of otitis media mucosa is usually quite different from that observed in well-marked cases of otitis media serosa. It often has a peculiar dead, milky, opaque appearance, which, unfortunately, is sometimes also observed in cases of the serous variety. Hence, without paracentesis of the membrane, we can scarcely do more than entertain a strong suspicion that the case is one of an accumulation of mucus in the tympanic cavity. After paracentesis has been performed, and the exuded material has been forced through the perforation into the auditory canal, it becomes, of course, an easy matter to make an absolute diagnosis.

As I shall have occasion, in the section relating to treatment, to refer to the course which these cases pursue, I may be permitted to omit all farther reference to the subject in this place.

*Hæmorrhagic Exudation into the Middle Ear.*—There are two classes of cases to which the expression just employed may be applied with equal justice, viz., those of acute catarrhal inflammation in which, during the first onset of the disease, a hæmorrhage occurs from some vessel in the middle ear, and those in which a serous fluid, deeply tinged with the coloring matter of the blood, finds its way into the tympanic cavity through other than inflammatory causes. Instances of the latter form of dis-

case are very rarely met with, and then usually in connection with a depraved state of the general nutrition (*morbis Brightii*). I once published<sup>1</sup> what I believed at the time to be a well-marked instance of this form of hæmorrhagic exudation. It occurred in a person who was affected with œdema of the lower extremities and who presented the characteristic facies of Bright's disease. When the patient was seen a second time, a few years later, an intratympanic pulsating, vascular growth occupied the position of the former hæmorrhagic exudation, and my previous error in diagnosis became at once apparent.

In the other form, that is, as an accompaniment of an acute congestion of the middle ear, hæmorrhagic exudations are by no means common. I refer, as a matter of course, to well-defined exudations, the red color of which is sufficiently pronounced for them to be readily distinguished through the *membrana tympani*. Serous exudations, slightly tinged with blood, are, on the other hand, often seen, and require no special consideration. The blood-vessels of the tympanic mucous membrane seem rarely to rupture under the strain to which they are subjected in acute congestion of these parts. It is far more common for the vessels which lie near the dermoid surface to break and afford escape to their contents. Occasionally, as a result of violence, both accidents may occur; some of the blood-vessels in the tympanic cavity as well as some of those on the outer surface of the *membrana tympani* affording escape to their contents. This happened, for instance, in the following case:

The patient, a carpenter, in robust health, drank to excess one night, got into a fight, and was probably struck on the head. At all events, he remembered waking up, on the following morning, with a loud ringing noise in the head, marked deafness, and blood oozing from both ears. Two or three days later I saw him at the Infirmary, and found both external auditory canals partially filled with clotted blood. I removed the clots and exposed the drum-membranes to view. The right one was pale and slightly œdematous on its outer surface, but no trace could be found of the spot from which the hæmorrhage came. While the outer surface of the left drum-membrane presented the same appearance as that of the right, its deeper tone of color was bluish or bluish-black, indicating the presence of dark blood in the tympanic cavity. The man unfortunately refused to have an incision made in the drum-membrane, and my notes furnish no further details with regard to the prognosis of the case. He probably sought relief at some other charitable institution.

#### TREATMENT.

In discussing the means that may be employed to advantage in the treatment of the different forms of acute and subacute

<sup>1</sup> In the *Medical Record* for October, 1871.

catarrhal inflammation of the middle ear, I propose to consider first the local and then the general measures.

*Local Measures.*—If we once adopt the belief that all catarrhal or inflammatory affections of the Eustachian tube and middle ear owe their existence to, and are promoted by, a similar irritation or inflammation of the naso-pharyngeal mucous membrane, our chief efforts will naturally be directed towards restoring the latter to a healthy condition. It is not my purpose in the present treatise to mention all the different methods and remedies which are commonly employed for the accomplishment of this purpose. I will limit myself to a description of those which I have found to be successful in attaining the desired end, and to a statement of my reasons why I do not like to employ certain others which are recommended by good authorities.

For all the different degrees of naso-pharyngeal catarrh I know of no more efficient remedy than *nitrate of silver*. My mode of using it is the following: I wrap absorbent cotton around the




FIG. 46.—Malleable Steel Cotton Carrier, armed with cotton and bent at an angle suitable for applying remedial solutions to the vault of the pharynx.

end of a malleable steel cotton-holder, and then bend the armed end of the instrument in the manner shown in the accompanying cut. In adults this shorter arm of the instrument should not exceed one inch in length; in children, it should measure from a half to three-fourths of an inch, according to the age of the child. To a distance of about three-eighths of an inch from the end the sides of the instrument should be slightly roughened, in order that the cotton-wool may cling firmly to it. Before dipping the mop into the solution of the remedy, the physician should always pass his finger over it, for the purpose of ascertaining whether the sharp end of the instrument is thoroughly well covered by the cotton. It is scarcely possible to lay down any well-defined rule with regard to the proper size of the mop. As a rough estimate, I may say that, at the point of its greatest breadth, it should measure about seven or eight millimetres in diameter for adults, and five or six millimetres for children.

The mop once ready, our next step is to saturate it to the proper degree with the remedial solution. Here again care must be exercised. If we dip the entire mop into the solution, and without

further ado introduce it into the naso-pharyngeal space, we must not be surprised if the patient objects to a repetition of the procedure. The mop filled with the remedy is precisely like a sponge saturated with water. The moment the naso-pharyngeal muscles contract, they squeeze the mop just as a person would a sponge, and cause a stream of the silver solution to run down into the larynx, or at least very near to its entrance. The symptoms thus caused are always extremely unpleasant, and, in a few instances, they may be decidedly alarming. On more than one occasion, in former years, I have completely demoralized both the patient and the patient's friends by the spasm of the glottis which had been provoked by my careless mode of applying the remedy. To avoid these unpleasant symptoms we either should saturate the entire mop, and then, by pressure, carefully remove the excess of fluid, or we should saturate only one half of the mop, leaving the other half to serve the purpose of a receiver into which the excess of fluid, pressed out of the moist half of the mop by the naso-pharyngeal muscles, may escape. This latter method is the one which I usually employ, and even then I endeavor to remove as much of the fluid as I can by pressing the saturated end of the mop against the neck of the bottle.

The steps of this operation of mopping out the naso-pharyngeal cavity are the following: The patient should sit directly facing the physician, with the source of light on one side of and a little behind him. Holding the instrument in his right hand, pressing the patient's tongue down firmly with the tongue depressor held in the left hand, and keeping his pharyngeal cavity well illuminated by means of the forehead mirror, the physician should request the patient to draw in a long breath, and then to breathe out slowly in such a manner as to cause the air to pass out through the nasal passages. This part of the procedure should be practised a few times by the patient before any attempt is made to introduce the mop. The object of this breathing out through the nose is to secure perfect relaxation of the palate muscles and thus to open widely the cavity into which it is desired to introduce the mop saturated with the remedy. Comparatively few patients succeed in actually sending air through the nasal passages, but in the great majority of instances the effort of the patient to accomplish the act results in the desired relaxation of the muscles and the consequent opening of the pharyngeal vault. The moment the physician observes this relaxation of the muscles he should at once pass the mop high up behind the soft palate, first toward one Eustachian orifice, and then across toward the other. If only one ear is affected, it will often be found sufficient to introduce the mop only on that side of the naso-pharyngeal cavity. Sometimes, when the attempt is made to carry the

mop across from one tubal orifice to the other, quite a decided obstacle is encountered in the form of a hemispherical projection of the mucous membrane at a point situated exactly in the median line of the posterior pharyngeal wall. If the instrument be pulled forward a little, no difficulty will be experienced in carrying the mop past the obstacle. In certain patients the mere act of depressing the tongue causes them to retch so persistently that all attempts to introduce the mop into the naso-pharyngeal cavity by way of the mouth have to be abandoned. It is often possible, however, in such cases, to accomplish the desired object by performing the operation with great speed. If this plan be adopted, the physician should be careful to protect his person, lest the contents of the patient's stomach be suddenly showered upon him. Finally, by wrapping a towel around the end of the patient's tongue, and instructing him how to pull that member well outside of his mouth, the physician may be able to reach the naso-pharyngeal cavity without producing the unpleasant results just mentioned.

In making remedial applications to the naso-pharynx the physician must notice particularly whether, and to what extent, the mucous membrane of that cavity is covered with mucus. On simple inspection he may very easily fail to discover the presence of any appreciable amount of mucus, and yet, on introducing his mop, be surprised to find that region well coated with a tough, tenacious, dirty-looking material which clings like a false membrane to the underlying tissues. It is not difficult to estimate the effectiveness of say a twenty- or even a forty-grain solution of nitrate of silver when introduced into the naso-pharynx under such circumstances. Very little of it, as a matter of course, ever reaches the mucous membrane, and consequently little or no benefit results from the procedure. It is therefore important to first remove this coating of mucus from the naso-pharyngeal mucous membrane, before we undertake to bring our remedies to bear upon it. For this purpose I am in the habit of employing simply dry mops of cotton. A single introduction usually suffices to bring away any free mucus that may be present; but sometimes I have experienced great difficulty in removing the tenacious material, and have even been obliged to employ forceps. I have no doubt that Weber's nasal douche, or the nasal syringe, might be used to great advantage in freeing the naso-pharyngeal cavity from such a tough coating of mucus; but, as I have already stated in an earlier section, my experience justifies me in considering this therapeutic procedure by no means a safe one, and I am therefore unwilling to recommend it for the purpose named.

The next questions of importance are, What remedy or remedies are the most effective in subduing a naso-pharyngeal catarrh?



and, How often should they be applied, and in how strong solutions? My answer to the first question is this: I rarely employ any other remedy than nitrate of silver. During the first years of my practice as an aurist I conscientiously and hopefully tried all the different solutions, powders, and sprays of which the numerous text-books and monographs speak in such favorable terms. As time went on, I found my stock of remedies gradually dwindling down until only five remained, viz., nitrate of silver, tincture of iodine, tannic acid, iron and alum. In all of these I place some confidence: in the first two I place a great deal of confidence, and more particularly in the first one. In young children, from four to eight years of age, I begin with a fifteen-grain solution of nitrate of silver and soon increase the strength to twenty or twenty-five grains to the ounce of distilled water. I first mop out the naso-pharyngeal cavity with the remedy, and then, after preparing a fresh mop, I paint the surfaces of the tonsils and the visible portion of the posterior pharyngeal wall. If some of the solution trickles down in the larynx, and causes violent coughing or a spasm of the muscles of the glottis, I give the patient quickly cold water to drink. On the next day but one I repeat the application of nitrate of silver, and continue to do so on every alternate day until the naso-pharyngeal mucous membrane has returned to a healthy state. In a few cases the mucous membrane returns to a *perfectly* healthy condition, so far at least as we can judge by simple ocular inspection; in the majority of cases, however, the catarrhal process simply subsides, under treatment, to a minimum degree of activity,—that is, the mucous membrane returns to a *comparatively* normal condition. In healthy children the naso-pharyngeal mucous membrane can usually be restored to this comparatively normal condition in the course of from two to four or five weeks.

From a comparison of the results obtained in numerous cases I am disposed to consider a twenty-grain solution of nitrate of silver as that best adapted to the average case of acute or subacute naso-pharyngeal catarrh. In deciding, in any given case, whether to increase or to diminish the strength of the solution, I am guided by the following considerations: If the employment of the twenty-grain solution is followed by a sense of discomfort, and perhaps even by pain, lasting for several hours afterward, I employ the next time a weaker solution, say one of fifteen grains to the ounce. On the other hand, if the sense of discomfort following the application passes away in the course of half an hour or an hour, we may safely assume that only a beneficial effect has been produced. Again, if the secretion of mucus continues with unabated activity, if the swelling of the parts does not diminish, and if their congested hue does not give place to a paler color

after four or five applications have been made, I then proceed without further delay to the employment of a thirty or even a forty-grain solution. In those cases which are characterized by the presence of a tough mass of mucus in the naso-pharynx, I have repeatedly failed to obtain a satisfactory degree of improvement until I had employed a nearly saturated solution of nitrate of silver. By a nearly saturated solution I mean one obtained by rubbing the wet mop over the stick of nitrate of silver several times in succession. When a strong solution like this is used, it is of course doubly important to remove the excess of fluid from the mop.

I have placed the tincture of iodine second on my list of remedies, not that I have good solid reasons for believing it to be less efficacious than nitrate of silver, but simply because patients dislike it so much more than they do the latter remedy. For this very reason I have not often employed it, and when I have, it has usually been in cases which had not responded well to the applications of nitrate of silver. The experience gained from this limited use of the remedy justifies me in speaking favorably of it. I have used both the simple and the compound tincture, and have not diluted either of them. In young children I have never attempted to introduce the remedy into the naso-pharyngeal cavity, but have found it serviceable as an application for the swollen mucous membrane of the visible pharynx.

So far as the naso-pharyngeal cavity is concerned, I have used alum, iron, and tannic acid in various forms, but never with much satisfaction. Chlorate of potassa I have used with even less satisfaction. They all seem to possess—if I may use such an expression—very little penetrating power. I can recall one case, however, in which excellent results were obtained by the systematic employment (daily), for a period of three or four weeks, of finely powdered burned alum. The patient, a strong, healthy man about fifty years of age, and apparently of temperate habits, was suffering from a most distressing tinnitus. His entire pharynx was very markedly congested, and there was a moderate degree of swelling of the parts. He visited the Infirmary twice a week, for a period of several weeks, but received little or no benefit from the treatment adopted (applications of nitrate of silver solutions to the affected mucous membrane, and inflations according to Politzer's method). Then, by way of experiment, Dr. Charles Laight, my associate in that institution, proposed to the man to come every day to his office, and have finely pulverized burned alum blown upon the affected pharyngeal mucous membrane (*not* upon that of the naso-pharyngeal cavity). The man eagerly consented, and visited the doctor faithfully for a period of about four weeks. At each visit, if I remember rightly, two or three

inflations according to Politzer's method were made. It is possible, also, that the man was induced to abstain from smoking. No other measures, however, were adopted that might have exercised a beneficial influence upon the condition of the throat, and secondarily upon that of the ear. At the end of the period mentioned I examined the patient's throat, and found it practically normal in all respects. The congested appearance had entirely disappeared, and the tinnitus was so insignificant that the man paid no attention to it whatever, and considered himself as cured. In this case the beneficial influence exerted by the remedy upon the mucous membrane of the pharynx extended to that of the naso-pharynx and middle ear. The excellent results obtained in this case led me to hope for similar results in other cases; but I must confess that in this I have been disappointed. I cannot recall a single instance in which any such brilliant result has been attained either by this drug or by nitrate of silver. I have obtained *fairly good* results, however, with powdered burned alum in quite a number of cases.

I ought perhaps to explain in this place why, if powdered burned alum is an effective remedy when applied directly to the pharyngeal mucous membrane, I should not also employ it as a direct application to the naso-pharyngeal cavity. My reasons are these: In the first place, I have tried this plan of treatment and am not at all satisfied with the results obtained by it; and in the second place, the patients themselves dislike the remedy, when used in this manner. At first I employed the alum in its full strength, and each time the application was followed by a most distressing "cold in the head," as the patients described it, which lasted for hours. I then diluted the alum with powdered sugar of milk, but thereby simply diminished the severity of the unpleasant symptoms. When a finely divided powder is blown into the naso-pharyngeal cavity, portions of it undoubtedly find their way into the communicating nasal, frontal, and maxillary cavities. To the mucous membrane lining these parts such a drug as alum, for instance, is known to be highly irritating. Hence, in the form of a powder, neither alum nor tannin can be employed as a direct means of treating the naso-pharyngeal cavity, without causing the patient unnecessary discomfort. This same objection applies in a measure to a finely divided spray. The expensiveness, however, of the apparatus required for obtaining a good spray practically places this mode of treatment out of the reach of the majority of practitioners. If used in the form of a solution, both alum and tannin are apparently much less efficient than either nitrate of silver or the tincture of iodine.

In a certain proportion of the cases, the methods which I have already described fail to accomplish the desired purpose.

or, if they apparently succeed, a relapse soon occurs, and a resumption of treatment becomes necessary. In these cases the physician would do well to explore the naso-pharyngeal cavity with his finger, for the purpose of ascertaining whether the obstinate irritation is not kept up by what are termed "adenoid vegetations," or follicular swellings, of the naso-pharyngeal mucous membrane.<sup>1</sup> If he finds this to be the case, he may safely as-

<sup>1</sup> For the information of those who may not have read Meyer's classical treatise on Adenoid Vegetations in the Naso-pharyngeal Space (Archiv für Ohrenheilkunde, 1873 and 1874), I will give here a brief abstract of the more important portions of this admirable contribution to otology.

Out of 175 cases in which adenoid vegetations were discovered in the naso-pharyngeal space, Meyer found that 130, or 74 per cent., were hard of hearing. As the mucous membrane of this region passes by direct continuity into that of the Eustachian tube and middle ear, we can readily understand why, in so large a proportion of the cases, the organ of hearing should participate in the naso-pharyngeal inflammation. The pathological condition referred to, under the title of "adenoid vegetations," consists in the presence of numerous, variously shaped tumors in the naso-pharyngeal space. (Figs. 47 and 48.) These vary in size from a mere follicular enlargement to a mass the size of a cherry-pit, or even a hazel nut. Sometimes they are pedunculate, at other times they are grouped together in a row, like the teeth of a comb. These masses are very vascular, and consequently of a bright red color; they have about the same consistency as the parenchyma of the liver, and present either a smooth surface or one that is slightly granular. They rarely occur singly; as a general rule, there are as many as from four to eight. The presence of these tumors implies a degree of inflammatory irritation in the mucous membrane of this region which can scarcely exist without an inflamed condition also of the Eustachian tubes.

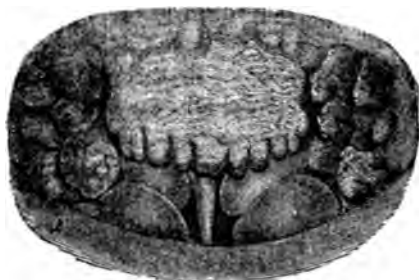

Fig. 47.—Adenoid Vegetations at the Vault of the Pharynx. The orifices of the Eustachian Tubes are completely concealed by the growths. (Copied from nature by means of the rhinoscopic mirror. (After Meyer.)

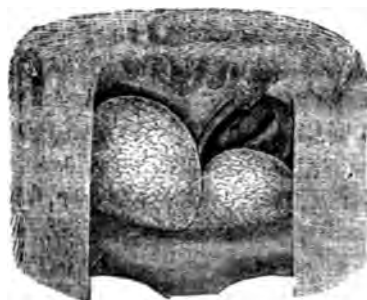

Fig. 48.—Another case of Adenoid Vegetations springing from the upper wall of the Vault. The large, smooth, rounded masses represent jelly-like hypertrophies of the mucous membrane of both lower turbinated bones. The larger swelling completely fills the posterior end of the corresponding nasal passage. (After Meyer.)

and present either a smooth surface or one that is slightly granular. They rarely occur singly; as a general rule, there are as many as from four to eight. The presence of these tumors implies a degree of inflammatory irritation in the mucous membrane of this region which can scarcely exist without an inflamed condition also of the Eustachian tubes. But these tumors may injure the organ of hearing in a purely mechanical manner. Thus, Meyer mentions cases where one or two of these tumors, growing from favorable points, attained such proportions as to completely block the entrance to the Eustachian tube.

The microscopic examination of these tumors showed them to be composed chiefly of what Meyer terms "adenoid tissue," viz., a network of connective tissue supporting countless lymph corpuscles, or lymphoid cells, as they are sometimes called. Here and there, throughout the section, the outlet ducts of acinous glands were also encountered.

The chief symptoms characterizing this affection are the peculiar expression of the face (Figs. 49, 51, 53), and the defective pronunciation of certain words; both of these phenomena being generally associated with more or less deafness. As regards the expression of the face, Meyer describes it in the following words: "In well-marked cases the mouth is constantly open, and the breathing takes place exclusively

sume that, by any or all of the therapeutic methods which I have described, he will probably fail to permanently relieve the patient of the more active evidences of his naso-pharyngeal catarrh. In these exceptional cases it has been my practice to entrust the treatment of this condition to some of my colleagues who are more skilled than I in operative procedures in the naso-pharyngeal cavity. My first experience with a case of adenoid vegetations convinced me that chemical means alone cannot be trusted, if we wish to obtain permanently successful results. As this case is an instructive one, I will give a history of it in brief outlines:

A strong, healthy boy, fourteen years old, was brought to me for treatment on the 12th of June, 1874. The boy's mother stated that when he was three years old he had had scarlet fever, and

through it. There is also a lack of tone in the play of the features, and the expression is characterized by a certain shade of sadness. After the breathing has taken place for a certain period of time exclusively through the mouth, the nose assumes a peculiar sharpness of outline; it looks pinched, and the alae appear to be sunken. If the patient happens to be suffering at the same time from a chronic nasal catarrh, this peculiar expression of the nose will, as a matter of course, not exist." The patient's pronunciation is defective in two respects: in the first place, the voice lacks the normal resonance; and in the next, the nasal tones—m, n, ng—are exchanged for others. Thus, for example, the patient does not say "Nase," but "Dase" or "Lase." Again, for the word "Zimmermann," he will say "Zibberbad," and for "Gesang," "Gesagk," and so on. These of course illustrate the modifications of pronunciation in a well-marked case. Such patients, Meyer says, have also great difficulty in singing high tones. Among other symptoms, he mentions the partial or total loss of the sense of smell, habitual headaches, the sensation of a foreign body in the back part of the nose, and the frequent escape of blood from the naso-pharyngeal region into the mouth. This last symptom he observed in a little over fifteen per cent. of all the cases that came under his observation.

While in this form of disease a positive *diagnosis* can only be made by physical means,—inspection of the naso-pharyngeal cavity by aid of the rhinoscope and reflected light, or an examination of these parts with the finger, introduced through the mouth,—we can nevertheless expect confidently to find adenoid vegetations in the naso-pharynx whenever we encounter the peculiar expression of countenance and the defective pronunciation described above. In support of this statement, Meyer mentions the fact that he examined 2,000 school children of both sexes in the public schools of Copenhagen, for the purpose of ascertaining, simply by looking at their faces and hearing them speak, how many of them were suffering from this affection. He found twenty children (1 per cent.) in whom these characteristics were well marked, and in each instance he verified the diagnosis by a digital examination. Meyer made a similar investigation in England, and found the proportion to be 13 out of 700, or nearly two per cent.

With regard to the question of *age*, Meyer found that, out of 175 cases, 134, or 76 per cent., were between the ages of five and twenty; the youngest patient was three years old, the oldest fifty-nine. In a few instances he found that there was a family tendency to this affection. Thus, in three instances, three sisters were affected with the disease, and in seven, two sisters.

As regards the *etiology* of this disease, Meyer simply states that the same causes which co-operate to produce a chronic catarrh of the naso-pharyngeal mucous membrane also play a chief part in the production of adenoid vegetations.

So far as his observations extend, Meyer believes that these vegetations usually commence to grow in childhood, but remain stationary during youth; and, if left to themselves, they will shrink away and disappear during maturity. Hence, so far as themselves are concerned, these vegetations might be allowed to remain without any interference on the part of the surgeon. But when we take into account their important relations to the organ of hearing,—not to speak of the unnatural and disagreeable tone of voice which they produce,—it becomes necessary to get rid of those already formed, and to check the further production of new ones.

The *prognosis*, as regards the results of treatment, seems to be quite good. Meyer states that among a number of cases which remained under observation for a period of from two to five years, and in which the vegetations had been thoroughly removed, not a single relapse occurred. The prognosis, as regards the hearing, is also quite good. Out of 112 cases which had undergone proper treatment, the hearing was restored to the normal standard in 48 instances; in 23 it was improved; in 3 it remained unchanged; in 3 it was rendered worse; and in 29 cases no note was made with regard

from that time onward he had been subject to frequent earaches, and had often shown a moderate degree of hardness of hearing.



FIG. 49.



FIG. 50.



FIG. 51.



FIG. 52.



FIG. 53.



FIG. 54.

FIGS. 49 TO 54.—Photographs taken from Three Individuals, showing the facial expression both before and after the removal of the Adenoid Growths. (After Meyer.)

At times the hearing had been quite poor. On examination I found both drum-membranes markedly sunken and of a pinkish hue. Both Eustachian tubes were easily inflated, and the patient observed a marked improvement in the hearing immediately following the inflation. The pharyngeal mucous membrane was congested and swollen, and on the posterior wall of the pharynx there were five or six circumscribed elevations (enlarged follicles). On alternate days, during a period of three weeks, I mopped out the naso-pharyngeal cavity with a twenty-grain solution of nitrate of silver, and applied a solution of the same strength to the pharyngeal portion of the Eustachian tube, by means of a bougie. I also employed Politzer's method regularly. At the end of this time the pharyngeal mucous membrane appeared to be comparatively free from active irritation; the drum-membranes occupied a more nearly natural position and had lost their former pinkish hue, and the boy appeared to hear conversation perfectly well. I accordingly discontinued treatment.

The following November he was again obliged to submit to a similar course of treatment. This time, however, the right middle ear was found nearly full of a thin, fluid exudation, which I evacuated through an artificial opening in the drum-membrane.

On the 25th of March, 1875, he returned for the third time, and again I found essentially the same conditions as those which I had found on previous occasions. The presence of the well-marked follicular swellings on the posterior pharyngeal wall led me to ask myself whether the patient's decided tendency to catarrhal in-

to the effect of treatment upon the hearing. This result appears in a still more favorable light when we examine the cases with regard to the length of time during which the deafness had existed. The following tables show this point very clearly:

TABLE I.				TABLE II.			
Duration of Deafness.	No. of Cases treated.	Cured.	Per cent.	The Hearing.	Simple Catarrh. No. of Cases.	Purulent Inflammation. No. of Cases.	Total.
Less than 3 months.	10	5	50	Was rendered normal in (.....)	34	14	48
From 3 to 12 months.	12	5	41.7	Was improved in.....	18	11	29
From 1 to 2 years.	17	9	52.9	Remained unchanged in (.....)	3	..	3
From 2 to 5 years.	23	11	47.8	Became worse in.....	..	3	3
From 5 to 10 years.	21	7	33.3	Was not tested in.....	23	6	29
More than 10 years.	10	10	47.6 - 40.5				
Indefinite	8	1	12.5				
Total	112	48	42.9	Total	78	34	112

In the treatment of this form of disease, the essential thing, according to Meyer, is to remove the vegetations, either by mechanical or by chemical means. In children, and also in adults when the vegetations are not too large or too firm in texture, they can be destroyed by pressure made with the finger. If this mode of destroying them fails, we must resort to the use of some caustic, preferably the nitrate of silver, either in the pure form or mitigated by the addition of nitrate of potassa. The instruments to be used for this purpose are silver rods, armed with a flattened end-piece, and differently shaped, so as to enable the surgeon to cauterize readily growths springing from any part of the naso-pharyngeal space. Where the growths are large, and especially where they are firm in texture, it becomes necessary to use other surgical contrivances, such as the galvano-cautery, a double-bladed instrument like that used for crushing vesical calculi, a ring-shaped knife, etc.

flammation of the Eustachian tubes and middle ears was not due to the existence of similar swellings in the naso-pharyngeal cavity. There were also other conditions which favored such a belief; conditions which up to that time had quite escaped my notice. I refer to the boy's peculiar expression of countenance, to his inability to breathe with the mouth closed, and to his muffled nasal tone of voice. As stated by Meyer, these symptoms point almost with certainty to naso-pharyngeal adenoid vegetations. In order to settle the question definitely, I explored this region with my finger, and to my surprise found it very much encroached upon by a number of nodular swellings of different sizes, the largest of which may have been as large as a filbert-nut. As soon as I had made this discovery, I decided to place the patient under the care of my friend, Dr. Horatio Bridge, who was then practising in this city. I cannot now recall exactly how long a time the patient remained under the doctor's care, but my impression is that it was fully six or seven weeks. In that time he removed, little by little, a mass of fleshy fragments sufficient to nearly fill a two-drachm specimen bottle. If I remember rightly, he employed for this purpose a ring-shaped scraper, with a long, slender shank, and reached the vegetations with it by way of one or both lower nasal passages. I have also an indistinct recollection that while he manipulated this instrument with one hand, he guided its cutting end by means of the forefinger of the other hand, introduced into the naso-pharyngeal cavity through the mouth. I also remember that he was careful not to attempt too much at one sitting, and always waited for all inflammatory reaction or soreness to subside before he attempted to remove other masses or portions of masses. This series of operations proved highly successful. The hearing returned to a fairly normal degree of acuteness, and has remained so up to the present time—a period of thirteen years. His facial expression brightened up and became more intellectual in its stamp; a change which was undoubtedly due largely to the fact that he was no longer obliged to breathe through his mouth.

In former years I held the view that these cases of adenoid growths were much less frequent in this country than they seemed to be abroad. More recently, however, I have searched for these enlarged glands in every case that presented the slightest evidence of obstructed nasal breathing or of unnatural tone of voice, and I have been amazed to find that the proportion of those catarrhal patients whose naso-pharyngeal adenoid tissue is sufficiently hypertrophied to call for surgical interference is really quite large. In nearly every instance I have found no difficulty in persuading the patient to submit to an operation, and with scarcely an exception the results have been most gratifying.

In this connection I cannot do better than to quote in full from an admirable article<sup>1</sup> recently published by Dr. Franklin H. Hooper, of Boston, Mass.

"The method I consider the best for a child, when there is a

<sup>1</sup>"Adenoid Vegetations in Children; their Diagnosis and Treatment." Boston Medical and Surgical Journal, March 15, 1893. •



large mass to be removed, and which I have carried out with great satisfaction in one hundred and four children of ages ranging from twenty months to fourteen years, is as follows: The child is thoroughly etherized. It is then placed in a good light, and seated upright in the lap of an assistant, the operator being seated opposite to it. The child's mouth is held open by a small-sized mouth-gag inserted between the teeth on the right side. Any accumulation of mucus in the pharynx is to be wiped out. The operator should now pass his index-finger up behind the soft palate and assure himself of the quantity and situation of the growths. Then gently pulling the soft palate forward and upward by means of a palate-hook held in the left hand, a pair of post-nasal forceps, held in the right hand, is introduced, closed, into the naso-pharyngeal cavity. One soon learns to feel the growths with the closed end of the forceps. The blades are then opened, the mass grasped and pulled off, either by direct traction or by a slight twisting movement of the forceps, but under no circumstances is force to be exerted. If the growth comes away with difficulty, release the blades of the forceps and begin over again, taking hold of a smaller portion of the growth. Force as well as hurry is to be avoided. The rapidity with which the operation is completed depends upon the amount of the hæmorrhage. If there is much bleeding after a portion of the mass has been removed, wait until it has ceased, and then proceed with the operation. This it is usually necessary to do from three to six times or more before the cavity is cleansed out. The finger is to be inserted in the cavity from time to time, until it is found that it is practically free. When it is considered that enough has been accomplished with the forceps, I hold the child's head well forward, so that the blood may flow out of the nose, and with the ball of the index-finger of the left hand, and the finger-nail, attempt to smooth down the remaining ragged edges by passing the finger first into one choana, then into the other, and then backward and downward along the posterior wall of the naso-pharynx; also, when necessary, along the lateral wall of the cavity, the Eustachian prominence, and in the fossa of Rosenmüller. This manipulation with the finger causes the blood to flow more freely than the previous evulsions with the forceps. Occasionally, also, after the larger portion of the growths has been plucked off with the forceps, a post-nasal curette may be introduced behind the soft palate and the remaining ragged masses scraped away. The steel finger-nail fixed to the finger and used as recommended by Sir William Dalby, is also serviceable for this purpose. In certain cases Meyer's ring-knife, introduced through the nostril, is of use to scrape around the Eustachian orifices, the end of the instrument being guided by the

fore-finger behind the soft palate, as practised by Mr. Butlin, of London, whose method, in fact, of dealing with these growths, with the exception of the position of the patient and the management of the soft palate, does not differ very materially from the one described. But, as a rule, the happiest results may be accomplished with the forceps and the fore-finger alone. With proper care and assistance there is no danger for the child, and in one sitting, occupying from ten to twenty minutes, it is practically cured of a complaint which may have existed for years.

"The removal of the growths, however, is not accomplished in all cases with equal satisfaction. The conditions which make the operation difficult are an excessive amount of mucus in the throat, a large thick tongue, enlarged faucial tonsils, a long distance from the lips to the posterior pharyngeal wall, a small space between the free border of the palatal curtain and the pharynx, and a deep naso-pharyngeal cavity. In no case has it been necessary to repeat the operation, though in two children, where the operation was prolonged owing to some complication, it was thought at the time that a second sitting would be needed. Yet these children did perfectly well, which leads me to think that we need not be too energetic, or imagine that every particle of the growths must necessarily be brought away. The principal object of the operation is to establish free nasal respiration. If this be effected, a small amount of adenoid growth left behind may not do harm. The vitality of the remaining tissue is probably destroyed, and it will atrophy.

"The growths do not recur after removal. In operating, as I invariably do, with the child in the upright position, it will be urged that there is danger of blood being sucked into the larynx. In speaking with practical surgeons concerning the operation, this criticism has almost always been advanced. But the objection is theoretical, and with care and prudence no accident of this nature need be feared. There are no large blood-vessels in the naso-pharyngeal cavity to be wounded, and it is characteristic of the bleeding from the growths that it ceases completely in a few moments. The blood does not come with a gush, but will be seen to be trickling slowly down the posterior wall of the pharynx. That which is not sponged out flows into the stomach, and will be vomited later. Liquids naturally flow down the oesophagus, and not down the windpipe. The danger in operations about the mouth is from a clot of blood becoming wedged in the glottis, and it is easy to guard against its formation in this operation. The bleeding varies greatly in different cases, and, as far as I am aware, there is no way of foretelling in any given case how profuse the hemorrhage may be. The vascularity of the growths does not seem to be proportionate to their size, for some

of the largest masses have bled insignificantly. In beginning the operation go slowly and watch. When a portion of the growth has been removed, wait until the bleeding has ceased, and then proceed with the operation. These children with obstructed



FIG. 55.—Forceps for the Removal of Adenoid Vegetations. Two-thirds actual size. (After Hooper.)

noses, especially if they happen to have enlarged faucial tonsils, are usually bad etherizers, and in many the accumulation of mucus in the lower pharynx is excessive, all of which is calculated to make the operator feel anxious; but no annoyance in any case has been caused by blood in the windpipe, and no surgeon who has been present at the operations, either at the Massachusetts General or the Boston City Hospital, or in my private practice, has seen cause for alarm on this score. There is more to be feared from vomited food lodging in the larynx than from a clot of blood. The ether, therefore, should be administered on an empty stomach. The degree of etherization must be sufficiently profound to abolish reflex action of the soft palate, so that it will yield to being held forward by the palate-hook without resistance. It is important to keep the palate out of the way of the forceps, and no effort should be made to grasp the growths when it is contracted. For, should its posterior surface or other healthy wall of the cavity be nipped, an obstinate and annoying hæmorrhage may take place. It will be an advantage for the operator to have a small index-

FIG. 56.—Hard-rubber Palate Hook. Two-thirds actual size. (After Hooper.)



finger; also a light hand and a delicate touch. It need hardly be said that he should possess a perfect familiarity with the situation of the different anatomical structures in the naso-pharyngeal cavity, and know the difference, when feeling with the finger or with the forceps, between the parts in a normal state and when covered by adenoid growths. In selecting a pair of post-nasal forceps for the operation, it will not do to take the first pair that comes to hand. The average instrument in the shops is unnecessarily cumbersome, and unnecessarily long. For

children, the curve of the cutting end of the forceps should be small, and the length of the handles as short as possible and perfectly firm, so that when the cutting ends are in contact there will be no 'give' at the handles. The ease and success with which these growths are removed under ether, when the sense of touch plays such an important part, depends very much upon the proper selection of instruments. The drawing on preceding page shows the exact size of forceps<sup>1</sup> (Fig. 55) which have been found to be the most serviceable for the average child up to the age of fourteen. The conventional hard-rubber palate hook is also shown, Fig. 56, as well as the mouth-gag preferred, Fig. 57, which is easy to adjust, easy to remove, easy to keep clean, and never out of order."

Operative procedures are also required in another and larger class of cases, viz. : those in which the tonsil becomes so enlarged as to encroach seriously upon the naso-pharyngeal space, and



FIG. 57.—Mouth-gag. Two-thirds actual size. (After Hooper.)

perhaps even upon the mouth of the Eustachian tube. The snail-like rate at which such a tonsil is likely to be reduced in size by superficial applications of either tincture of iodine or nitrate of silver, fully justifies the adoption, from the very beginning, of some more potent method of procedure. As I have no experience of my own to offer with regard to the best methods of excising small or large portions of the tonsil, I will refer the reader to some of the more recent text-books on the subject of throat diseases. In cases where the tonsils are so large as to interfere with the proper ventilation of the middle ears, or where they encroach upon the pharynx to such an extent as to interfere with respiration, and consequently with the development of the chest, it seems to me that there can be but one opinion with regard to the advisability of diminishing their size as rapidly as is consistent with the patient's safety. In cases where the swelling of the tonsils is not excessive, I am disposed to question the wisdom of

<sup>1</sup> Owing to the small size of the page I have thought it desirable to reduce these three illustrations to two-thirds of their full size.—A. H. B.

either excising any considerable portion of the tumor or of injecting iodine into its substance; the surface applications described above will usually be found sufficient to control the activity of the catarrhal process.

In connection with the subject of treatment of the naso-pharyngeal mucous membrane, I might add that in a certain number of cases excessive smoking, and the frequent taking of the stronger alcoholic drinks (undiluted), contribute very appreciably toward keeping the pharyngeal mucous membrane in an irritated condition. If the patient is allowed to continue these habits, the physician will find it an up-hill task to cure the aural disease.

The question which naturally suggests itself next, in connection with the treatment of acute and subacute catarrh of the middle ear, is this: Shall we endeavor to bring our remedies, either in the form of a fluid or in that of a spray, into direct contact with the mucous membrane of the Eustachian tube and middle ear, or shall we trust solely to the indirect effects which follow the application of these remedies to the naso-pharyngeal space? I have no wish to place myself in opposition to the teachings of nearly every acknowledged authority in the department of practical otology, but I must say frankly that I have no faith in the practice of injecting fluids into the Eustachian tubes or middle ears. For a period of a year or eighteen months I used them in the manner in which I had been taught to use them in Vienna. I soon became satisfied, however, that in not a few cases the injections (weak solutions [gr. j. to iij. to the ounce] of sulphate of zinc, alum, or nitrate of silver) promoted the very irritation which I was endeavoring to allay; and, in the second place, that the completeness and promptness of the cure were in no instance more marked than in those cases which I had treated without injections. Furthermore, I was always conscious that I was employing a method over which I could exercise but little control; in fact, I never knew whether the small quantity of fluid which I had injected through the catheter, had entered the cavity of the tympanum, or had merely bathed the walls of the pharyngeal portion of the tube. With the view of removing this element of uncertainty from our efforts to apply remedies to the Eustachian tube, I suggested the employment of small mops which could readily be passed through the ordinary Eustachian catheters.<sup>1</sup> I gave this plan a fair trial, but I did not secure any better results than I did by means of the simpler method of leaving the Eustachian tubes alone. Furthermore, the procedure, as I am now convinced, is not a perfectly safe one, unless we abstain from using the stronger solutions of nitrate of silver. In

<sup>1</sup> A Method of Using Medicated Eustachian Bougies. Transactions of the American Otological Society, 1875.

the case of one of my patients, a gentleman, thirty-eight years of age, and in vigorous health, I found the tubes so obstructed that the drum-membrane on both sides appeared to rest against the promontory. I carried out the simpler plan of treatment for a few days, and then, failing to accomplish the desired result, I resorted to the use of the bougie, armed with a mop of absorbent cotton, which had been dipped in a strong solution of nitrate of silver (exact strength not known). I passed the bougie, armed with this medicated mop, about a quarter of an inch into one tube, and then, after saturating the mop a second time, pushed it about the same distance into the other tubal orifice. While I was cleaning my instruments I noticed that the patient had grown very pale. I asked him if he felt ill, and he replied in the affirmative. I then took him by the arm for the purpose of assisting him to walk to the sofa, but by that time he had lost consciousness, and simply slid from his chair down upon the floor. His breathing rapidly became stertorous, and he passed into a violent convulsion which lasted fifteen or twenty seconds. The muscles then became relaxed, and perfect consciousness returned, the patient expressing great surprise that he should be lying stretched out upon the floor. His urine was examined, but it was found to be perfectly normal. The unconsciousness and convulsions were probably due in this case to a reflex spasm of the arteries of the brain, dependent upon the irritation supplied by my introduction of the bougie (saturated with a strongly irritating solution) into the Eustachian tube.

The employment of bougies is said to be attended by another danger, viz., that of lacerating the parts, and thus opening the way for the development of emphysema. This accident can only occur, I believe, when undue violence is employed in the manipulation of the bougie: for at one time (1874-5) I used this instrument very frequently in private practice, in young children as well as in adults, and yet I have never seen a case of emphysema following its employment. The free end of the whalebone bougie should be well wrapped in cotton, so that it shall present a perfectly blunt, soft mass; and if this precaution be taken, it is difficult to comprehend how laceration of the parts can result from the introduction of the bougie unless positively rough manipulations are employed.

The introduction of vapors into the middle ear is recommended by some authorities as an excellent therapeutic procedure in cases of subacute catarrhal inflammation of the middle ear. Some, for example, extol the beneficial effects of "steaming" the middle ear; others recommend highly the introduction of the vapor of iodine, or the fumes of sulphuric ether or chloroform. With regard to all these methods of treatment, I think we should put to

ourselves the question, Do they accomplish better results than the simpler methods now generally employed? If they fail to accomplish a more speedy or a more perfect cure, I am at a loss to see why we should continue to use them. The evidence which I have gathered on this subject, partly from my own experience and partly from that of my colleagues, points very decidedly to the conclusion that these methods are not more efficient than the simpler plans now very widely adopted. I may therefore omit any further detailed account of these methods, and will pass on to the consideration of those other local therapeutic measures about whose beneficial effects there is very little dispute.

If we exclude those methods of treatment which aim to bring the different remedies in direct contact with the mucous membrane of the Eustachian tube and middle ear, we virtually establish the rule that, *in cases of simple uncomplicated acute or subacute catarrhal inflammation of the middle ear, all direct therapeutic interference with this region by means of drugs is to be dispensed with.* In certain complicated cases it will be found advantageous to introduce remedies into the cavity of the tympanum, but these cases are quite exceptional.

It is in the form of disease which we are now considering, that *inflations of the middle ear*, by means of compressed air, are especially efficacious. Whatever theory we may adopt with regard to the precise manner in which these inflations exert a beneficial effect, there can be very little doubt that a large part of this good effect is to be attributed to the restoration of the membrana tympani to its normal position;—and a return of the drum membrane to its normal position almost necessarily implies a return of the entire chain of ossicles to a normal position. Inflations, however, probably do good in other ways. Thus, for example, it is not unlikely that the sudden rush of air through the Eustachian tube may dislodge portions of mucus which have helped to obstruct that channel. In the next place, the pressure exerted upon the oedematous mucous membrane of the middle ear and Eustachian tube must promote the absorption of the cellular and fluid elements to whose presence the swollen state of these parts is due. Whether these speculations with regard to the *modus operandi* of inflations be correct or not, the fact of their decidedly beneficial effects will scarcely be seriously disputed at the present time.

The first practical question that presents itself in connection with the therapeutic employment of inflations is this: Shall we use the catheter, or shall we trust to what is known as Politzer's method? As good results are obtained with both plans of procedure, it is not strange that the question should be answered differently by different men. The following considerations guide

me in my choice between these two methods. As patients have a much greater repugnance to catheterization than to the employment of Politzer's method, and as the latter procedure is generally just as effective as the former, I always endeavor to dispense with the catheter, if circumstances will permit. Furthermore, it must be remembered that the presence of the catheter in the nasal passage and in the mouth of the Eustachian tube produces a certain degree of irritation. In a few cases I have observed that this irritation was sufficient to counterbalance the good effects of the inflations; at all events, appreciable improvement in the condition of the ear and in the acuteness of the hearing did not appear in these cases until after I had abandoned the catheter, and restricted myself to the employment of Politzer's method. There are cases, however, in which, for various reasons, Politzer's method fails to drive air with adequate force into the middle ear. Under these circumstances our course is clear: we must employ the catheter.

The next practical question is this, How often should we employ either of these two methods? To this question I can only give a more or less arbitrary answer. I really do not know whether it is better to inflate the ear several times daily, or only once a day, or even only on alternate days. I do know, however, that in the class of cases which we are now considering, I obtain reasonably good results by resorting to the inflations—four or five successful ones at a sitting—only every other day. Too frequent inflations may undoubtedly do harm, especially if the practice be continued for a period of several weeks or months; but it would be a difficult matter to define the limit beyond which inflations begin to be harmful.

It is equally difficult to lay down rules with regard to the proper duration of such a course of treatment. In subacute cases of recent origin two or three repetitions of the inflations on alternate days may be found sufficient to restore the drum-membrane permanently to its normal position, to remove every trace of congestion or swelling, and to bring back the hearing to its former degree of acuteness. In other cases—and these perhaps represent the average—a course of treatment covering a period of two or three weeks will be found necessary for the accomplishment of the same results. Finally, even in the more stubborn cases I very rarely keep up systematic treatment beyond the fourth or fifth week. I prefer to give the parts an absolute rest of two, three, or four weeks, and then, if necessary, resume the inflations and the applications to the naso-pharynx.

If, in these cases of catarrhal inflammation of the middle ear, the evidences of congestion are slow to leave the membrana tympani, the local abstraction of blood by means of Bacon's artificial



leech, to be repeated once or twice on alternate days, according to the results obtained, will sometimes hasten recovery very materially. The employment of local blood-letting, for the relief of pain, will be considered under the heading of Treatment, in the chapter relating to Purulent Inflammation of the Middle Ear.

*General Measures.*—In the great majority of cases the local treatment alone will be found sufficient for the removal of the patient's symptoms. In a few cases, however, we may find it necessary to resort to other measures. Thus, for example, I have repeatedly met with patients who were affected with a naso-pharyngeal catarrh (either a recent attack or an exacerbation of a more chronic process) which resisted all my efforts to control it. At the end of the third week, having failed to materially improve the condition of the parts, I have urged the patient to get a change of air and scene for a week or ten days, or even longer, if necessary. One patient visited Savannah, another Aiken, S. C., a third Lake George, a fourth the Catskills, and so on; and, in nearly every instance, with the effect of entirely throwing off all active manifestations of the catarrh. Again, in some of these cases, there is another feature which the physician must be careful not to overlook. I refer to the important part which disturbed gastric digestion plays in keeping up a naso-pharyngeal catarrh. Thus far I have observed such a relation only in rather stout, full-blooded individuals, who took very little exercise and yet ate heartily. Local applications to the pharyngeal and naso-pharyngeal mucous membrane accomplish very little in such cases. An adequate daily amount of exercise, a diet of more easily digested articles of food, and the practice of daily sponging the entire surface of the body with cool water and then employing friction with a rough towel, are the best means that I know of for eliminating whatever influence disturbed gastric digestion may have upon a naso-pharyngeal and aural catarrh. Finally, in another class of cases, cod-liver oil may be administered with the greatest advantage. This is especially true of children, in whom the oil seems to act almost as a specific against "colds in the head". Doses of from half a teaspoonful to a teaspoonful of an emulsion with the syrup of the hypophosphites, repeated three times a day after meals, will be found sufficiently large for the accomplishment of the purpose desired.

#### TREATMENT OF SPECIAL STAGES OR CONDITIONS.

To avoid repetition, I will say nothing at present about the treatment to be pursued in the painful stage of an acute otitis media catarrhalis. In this stage of the inflammation it is impossible to decide positively whether the attack will eventually be of the catarrhal or of the purulent variety. It seems better,

therefore, in all cases to assume that the attack will be one of purulent inflammation of the middle ear; and for this reason I will refer the reader to the section relating to the treatment of that variety of ear disease.

The question which demands our attention more particularly in the present section is this: How far ought we to modify the plan of treatment just described, when we discover that a serous fluid or a mucoid material fills a large portion of the tympanic cavity? Here, again, it is scarcely possible to formulate a rule that will be found generally applicable in practice. Each case differs in some respects from the preceding one, and accordingly, our treatment must vary correspondingly. In former years I followed, for a time, the practice of always incising the drum-membrane and evacuating the fluid, as soon as I discovered a sufficient amount of it in the tympanum to apparently half fill that cavity. I very soon found, however, that relapses were exceedingly frequent. I accordingly modified the rule to this extent: I postponed making the incision and evacuating the fluid until after I had materially diminished the naso-pharyngeal catarrh, and had re-established a free passage through the Eustachian tube. Under this régime I observed now and then a case in which the fluid contents of the tympanum gradually disappeared coincidently with the improvement in the condition of the naso-pharynx; thus rendering paracentesis unnecessary. This suggested to me the idea that the treatment employed in the ordinary cases of catarrh of the middle ear, without effusion, would probably be found equally successful in those with effusion. I accordingly dismissed from my mind the idea that paracentesis was either necessary or desirable, as a means of getting rid of the effusion in the tympanic cavity, and adopted the practice of treating these cases in precisely the same manner as I do the ordinary cases, in which there is no appreciable amount of effusion. I have followed this practice now for several years, and am well satisfied with it. It is only in rare cases now that I yield to the temptation to make an incision and evacuate the fluid; and even in some of these I have afterward arrived at the conclusion that the case would have got well just as quickly if I had not had recourse to the knife.

In some of the more stubborn cases I employ counter-irritation behind and below the auricle. For this purpose I use either tincture of iodine or the cantharidal collodion. I instruct the patient to apply every night before retiring, two or three coats of the iodine to the mastoid region of the side affected. As soon as the skin becomes uncomfortably sore,—*i.e.*, generally on the third, fourth, or fifth day,—the parts are to be left undisturbed for two or three days, and then the iodine is again to be applied every

night in the same manner as at first. In several cases in which I used tincture of iodine in the manner just described, I was disposed to believe that the improvement which followed the employment of this remedy was fairly to be attributed to the property which it possesses of stimulating the absorbents to greater activity. The beneficial effects obtained with cantharidal collodion are undoubtedly to be attributed to this same property of stimulating the absorbents. I have used the latter preparation in the following manner: I apply two or three coats of cantharidal collodion to the skin of the mastoid region, cover it with Husband's plaster or the rubber plaster, or with simple collodion, and then keep up slight pressure over the spot by means of a soft linen pad held firmly in position by a bandage or handkerchief passed over the top of the head and under the chin. After a distinct sac, containing fluid, has formed, the patient should remove the bandage and pad, evacuate the fluid, and then cut away the dead cuticle. The remaining inflamed surface should then be dressed for a short time with vaseline or any other simple ointment. As soon as the skin has returned to a comparatively normal state, the same procedure may be repeated. As the tincture of iodine appears to be at least as efficacious as the cantharidal collodion, and as it can be managed much more easily than the latter, I now use it almost exclusively under the circumstances described above.

After the different measures which I have described have been tried for a reasonable length of time, say for three or four weeks, without materially diminishing the fluid exudation in the cavity of the tympanum, we may with advantage resort to paracentesis of the drum-membrane, for the purpose of providing an opening through which the fluid may be driven out into the external auditory canal, and also, in certain cases, for the purpose of confirming or modifying our diagnosis. This operation, if performed with a reasonable degree of care by a physician who knows something about the anatomy of the middle ear, may be considered as perfectly safe. There is but one real danger, and that is this: the operator may, with the point of his knife, injure the delicate attachments of the anvil, or drive the stirrup into the vestibule with such force as to rupture the annular ligament or injure some of the delicate labyrinthine structures. However, the attachments of the stirrup to the oval window are quite strong, and this ossicle can unquestionably be handled rather roughly without serious injury being caused to the organ of hearing. The attachments of the hammer are also very powerful. On the other hand, those of the anvil are very feeble. This ossicle is as it were suspended between the hammer and the posterior wall of the tympanum. The bands which attach it to the hammer are extremely delicate.

From these the anvil derives little or no stability; but from the peculiar interlocking of the articular surfaces it derives probably its chief strength. At best, however, this ossicle possesses very feeble supports, and may easily be disconnected from the hammer by the manipulations of an ignorant or careless operator. In incising the *membrana tympani*, therefore, we should so guide the end of the slender spear-pointed knife that it shall not strike the end of the long process of the anvil or the attached head of the stirrup. All these parts which are to be avoided occupy, fortunately, a comparatively small portion of the area within which the knife can be used. This dangerous region occupies about half (the upper half) of the posterior superior quadrant. Hence we may, without the slightest fear of injuring the ossicles, begin our incision a little above the dividing-line between the upper and lower posterior quadrants, and midway between the handle of the hammer and the periphery of the membrane, and carry it down nearly to the lower limit of the latter. The *membrana tympani secundaria* need give us no anxiety, as it lies safely concealed in its niche of bone, quite out of reach of any straight instrument that might be introduced through the outer meatus. Furthermore, if the point of the blade be carried too far inward, the only result will be an incision or a punctured wound of the mucous membrane covering the inner bony wall of the tympanum, a result that has no significance in the pathological conditions now under consideration. If the fluid exudation in the cavity of the tympanum be serous or only slightly mucoid in character, such a linear or slightly curved incision as I have described will afford an ample outlet for its escape. But if it be more decidedly mucoid in character, such a mere slit will not be found adequate. A second incision must then be made, at right angles to and opposite the middle point of the first one. In making this second incision we should cut in the direction from the periphery toward the centre of the membrane, and not from the existing incision backward.

It is by no means an indifferent matter what sort of a cutting instrument is used in making an opening in the *membrana tympani*. In a general way it may be said that a spear-pointed, two-edged blade is the best adapted to this purpose. (See Fig. 58.) In the construction of such a knife—or *myringotome*, as it is often called—regard must be had to the relations of the drum-membrane to the inner wall of the tympanum. Thus, for example, it is safe to assume that we shall never be called upon to incise a membrane whose posterior half occupies a position less than two millimetres distant from the inner wall of the tympanum. We may also take it for granted that we shall never find it necessary to incise a membrane so distended that it occupies a position more

than five millimetres distant from the inner wall of the tympanum. It is therefore unnecessary to have the cutting edges of the spear-pointed knife of greater length than five millimetres.

The myringotomes which I use have cutting edges only three millimetres in length, and I find them amply long. In the next place, it is desirable that the spear-headed blade should be quite broad at its base; the breadth in this case being measured from cutting edge to cutting edge. In children and sensitive people a single stab is often all that we can obtain, unless we resort to the use of an anæsthetic. Under such circumstances the broader the blade of our knife, the greater will be the length of our incision in the drum-membrane. In my instruments the greatest breadth is barely three millimetres. Possibly a breadth of three and a half millimetres would be found better adapted to all the purposes for which a myringotome is used; but we must not forget that we are often called upon to operate in a canal of very small calibre, and that even a slight increase in the size of the knife may be sufficient to greatly increase the difficulty of the task of operating successfully.

It is largely a matter of individual preference whether a straight or a slightly bent myringotome be employed. After using both kinds, I have gradually fallen into the habit of using only the straight instrument. It seems to me that I can control such a straight myringotome more perfectly than I can a bent one. Those which I use are made from a single piece of steel, 16 cms. long; the slender shank together with the blade measuring 7 cms., while the eight-sided, roughened handle measures 9 cms. in length.

I do not remember ever to have found it necessary to resort to an anæsthetic in a case requiring paracentesis of the comparatively healthy membrana tympani. The pain caused by the incision must therefore be only moderately acute. It is also of very short duration. As soon as it has subsided, we should inflate the middle ears, according to Politzer's method, taking the precaution first to make the patient incline the head well over toward the shoulder of the side on which the drum-membrane has been incised, in order that the force of gravity may mass the fluid directly over the arti-

ficial opening. In a case of simple serous exudation, one or two inflations almost always suffice to drive out all the fluid into the meatus; but if the exudation consists of ropy mucus,

FIG. 58.—Myringotome. (The dimensions of the spear-pointed end are somewhat smaller than they should be.)



the inflations alone will usually not be found equal to the task of expelling any considerable portion of the mass. Thus, for example, it is a common experience, after one or two vigorous inflations, to find lying just outside of the drum-membrane a small mass of mucus, which looks as if it might readily be removed with a mop of cotton; but when the attempt is made to do this, the fact is soon discovered that this mass is simply a rope-like extension of a greater mass that still remains behind in the middle ear. It is therefore better in these cases to combine inflation through the Eustachian tube with suction applied to the external auditory canal. With Siegle's apparatus we may perform effective suction, and at the same time observe exactly what is taking place at the perforation. We may secure the requisite inflating power by instructing the patient to perform Valsalva's experiment at the moment when the sensation of tightness caused by the suction begins to be felt in the ear. In this way, by applying a pulling and a pushing force to the mass of mucus, we may often succeed in removing quite a large portion of it. There is but one way, however, in which we can be sure of removing every trace of mucus from the tympanum, and that is by washing out this cavity with tepid water. I have employed this procedure in such a small number of cases of well-marked otitis media mucosa that I do not feel justified in expressing a decided opinion either for or against it. In a somewhat different class of cases (see farther on) I have washed out the middle ear with the very best results, and it is quite possible that, in the class of cases now under consideration, equally good results may be obtained. However, the little experience that I have had with this plan of procedure does not lead me to look upon it with favor, at least in the treatment of this class of cases.

After reasonable efforts have been made to drive out the mucus from the tympanum, my rule has been, at least during the past four or five years, to allow the perforation to heal, and then to treat the case in precisely the same manner as if it were an ordinary case of subacute otitis media catarrhalis. If we repeat our efforts to drive out the mucus, and reopen the wound in the drum-membrane too often, we shall be almost certain to set up a more or less active inflammation of the parts, and thus materially retard the patient's recovery. Individual cases, however, differ so much in their predisposition to inflammation, that it is scarcely possible to prescribe the limits beyond which it is not wise to go in our efforts to free the tympanum from mucus. In several instances I have had good grounds for believing that my therapeutic interference had, in the main, done more harm than good. I will give here, in brief outlines, the history of one of these cases.

The patient, a gentleman about forty years of age, and in a fair state of health, consulted me on the 5th of October, 1878, for an affection of the left ear. During the previous two weeks he had experienced moderate deafness and a feeling of fulness in the left ear, without pain. On examination I found the membrana tympani appreciably swollen, bulging posteriorly, and somewhat red. On auscultation during inflation, I heard crackling sounds in the left ear. I made a diagnosis of subacute catarrhal inflammation of the left middle ear, with considerable fluid exudation in the tympanum, and an unusual degree of swelling of the tympanic mucous membrane; and submitted the patient to the usual treatment (inflations and applications to the naso-pharyngeal space). In the hope of hastening his recovery, as he was desirous of leaving the city at an early date, I applied a blister to the mastoid region, and prescribed a preparation of calisaya bark, to be taken internally.

On the 9th of October, I found the posterior half of the membrana tympani still markedly bulging. I therefore made a free vertical incision through the middle of the protruding portion, and was surprised to see the edges of the wound gape widely apart, as commonly happens when a cicatricial membrane is incised. This gaping of the wound displayed to view a mass of opaque mucus, which apparently filled the cavity of the tympanum. Simple inflation by Politzer's method detached from the main mass of mucus a piece about half the size of a pea, and hurled it against the upper wall, half way out of the canal. This mucus had apparently lost in a great measure its ropy character. In various ways I finally succeeded in removing several smaller pieces of mucus, all of them together forming a mass about the size of an ordinary pea. All these different manipulations, as well as the original paracentesis, caused the patient almost no pain. In fact, the anæsthesia was more marked than I had ever before observed it. The mucous membrane of the middle ear, so far as it could be seen through the gaping perforation, presented a dull, pinkish hue, quite in harmony with the anæsthetic condition alluded to above. After I had removed as much mucus as I could from the middle ear, I touched the edges of the wound lightly with a bead of nitrate of silver.

On the following day, October 10th, I found the ear perfectly quiet. No inflammatory reaction had followed. The parts were simply moist.

October 11th.—Very scanty watery discharge, without the slightest admixture of mucus. Continued freedom from pain. With a slender glass pipette (see Fig. 61) I introduced a small quantity of a ten-grain solution of nitrate of silver into the middle ear.

October 14th.—No return of the mucus. Wound shows little or no tendency to heal. Slight watery discharge continues. Patient is obliged to leave town for a few weeks.

November 30th.—During his absence from the city, patient has had a slight but constant watery discharge from the ear. Of late the discharge has been more abundant and thicker. On one or two occasions he experienced a moderate degree of pain in the ear, but he attributed it to the rough manner in which the syringe had been used. On examination I found the membrana tympani red, swollen, and bathed with a greenish pasty pus. By aid of the probe I discovered that the anterior cul-de-sac—the space between the drum-membrane and the anterior and lower wall of the meatus—was filled with a mass of granulation-tissue. I removed it with the snare in three or four seizures, and found

that it consisted of two separate growths, one of them springing from the surface of the drum-membrane, close to the short process, the other from the edge of the perforation. The membrana tympani at all points seemed to be enormously hypertrophied, and noticeably so throughout the posterior half of the membrane, where, as seen through the large and gaping perforation, it appeared to fill the tympanic cavity solidly. The extraordinary course pursued by the disease in this case led me to suspect that perhaps it was complicated by syphilis. I accordingly investigated this point thoroughly, but failed to obtain the slightest evidence corroborative of such a view. Nevertheless I thought it best to prescribe for him the bichloride of mercury in one-thirty-second of a grain doses, three times a day.

December 9th.—Since the last date the local treatment has consisted in applications, first, of nitrate of silver in the form of a bead, and afterward of powdered burned alum, to the spots from which the granulations grew. Under this treatment the discharge diminished very perceptibly, and the outer surface of the drum-membrane again became smooth and firm, but the gaping perforation and the enormous hypertrophy of the mucous membrane of the membrana tympani still persisted apparently unchanged. As the iodide of potassium produced quite a decided coryza, and brought out a reddish eruption on the face, I abandoned the idea of a syphilitic taint, and discontinued internal treatment.

A few days later the patient was again called out of town, and I have not seen him since.

I have always felt that this case, which is certainly a most extraordinary one in many respects, would have got along better if I had treated it less vigorously. On the other hand, I can recall a very similar case, which I treated at the New York Eye and Ear Infirmary in an equally vigorous manner, but with very different results. The drum-membrane presented the same bulging appearance, and upon incising it the edges of the wound separated in precisely the same manner as in the preceding case. Instead of driving out the almost gelatinous mucus which apparently filled the tympanum, I boldly inserted a bead of nitrate of silver through the artificial opening and turned it upward and backward so as to bring it well in contact with the swollen mucous membrane of that region. Four days later, when the patient called a second time, I found the posterior half of the drum-membrane flat instead of bulging, and a dry scab occupied the site of the incision. In the course of another week or ten days, without any further treatment during the interval, the parts returned to a comparatively healthy state, all evidences of an accumulation of mucus disappearing completely.

In the following case, which presented very nearly the same physical conditions as those observed in the two preceding cases, I tried still another plan of treatment.

The patient, a gentleman about fifty years of age and in vigorous health, gave a history of slight deafness and a sensation of



fulness in the right ear dating two months back. On examination, April 20, 1879, I found the right drum-membrane dull, opaque, and noticeably bulging posteriorly and superiorly. This condition was associated with a slight naso-pharyngeal catarrh. The watch was heard only when pressed against the ear. Without going into all the details of his case I may say that on the 23d I made a free linear incision in the bulging posterior half of the drum-membrane. As the edges of the wound gaped, I could see that the membrana tympani in this locality was very much hypertrophied through swelling of its lining mucous membrane. By means of Politzer's method of inflation I drove out a limited amount of mucus. I then used combined suction and inflation in the manner already described, but failed to evacuate any additional mucus. Finally, I introduced a curved slender glass tube into the tympanic cavity, and employed suction. These efforts, however, failed to remove any perceptible amount of mucus.

On the 27th of April, no inflammatory reaction having followed my interference on the 23d, I removed the scab which covered the wound, and injected, with a middle-ear pipette, a rather strong solution of bicarbonate of soda into the tympanum. I assumed that there must be more of the thick mucus, such as I had already removed, still remaining behind in the tympanum; and I thought that the solution of bicarbonate of soda would, in the course of a few minutes, soften it to such an extent that I should be able to remove a large part of it by means of Politzer's method. The experiment proved in a measure successful; at all events, it was found, after inflation, that a fair amount of ropy mucus had been driven out through the perforation in the membrana tympani, and that the patient's hearing had become somewhat more acute (H. D. W.—one inch).

May 1st.—Patient having experienced no pain in the ear as a result of the procedures just described, I ventured to reopen the wound a second time. I found the tissues still greatly swollen, but on inflation the air escaped freely through the perforation, with little or no admixture of fluid. I therefore decided to restrict my treatment to daily inflations of the middle ear (according to Politzer's method). The patient performed the inflations himself at his home, and presented himself for examination on the 18th of May. I then found that the bulging of the drum-membrane had entirely disappeared, and with it probably the greater part of the swelling which had constituted such a prominent feature in the case. The patient no longer experienced any difficulty in hearing what was said to him, and the sensation of fullness in the ear had entirely disappeared. Notwithstanding this subjective and objective improvement, the patient could distinguish the ticking of my watch only at a distance of two inches.

If the perusal of these histories of cases of otitis media mucosa leaves the reader in a state of doubt as to what course of treatment he should adopt under similar circumstances, I must confess frankly that I am not now disposed to advocate any of the procedures described above. The milder, less meddlesome method recommended for the uncomplicated cases is still the best one known to me for the relief of the complicated ones. It is important, however, to supplement the special treatment with cod-liver oil in small doses, with the compound tincture of cinchona, and in some instances with nux vomica.



INFLAMMATION OF THE MIDDLE EAR. 193

It is not an uncommon occurrence for the patient to ask the physician whether he or she cannot carry out the requisite treatment at home. Self-inflation—if I may so designate the act of inflating one's own middle ears according to Politzer's method—is not a very difficult procedure to learn; but the effective application of a remedial solution to one's own naso-pharyngeal space is a far more difficult task and one that very few patients succeed in learning. In my experience the results obtained by self-treatment even when the patient is a physician and thoroughly conversant with the procedures to be employed, are rarely satisfactory in the class of cases which are here under consideration.



## CHAPTER VIII.

### CHRONIC CATARRHAL INFLAMMATION OF THE MIDDLE EAR.

IN this category are generally included all those cases in which the characteristic symptoms are progressive deafness, noises in the ears, and an intact drum-membrane. If we could examine the interior of the middle ear and labyrinth, we should probably find that the very large number of cases which we now, in our ignorance of the underlying pathological conditions, register under the single title of "chronic catarrh of the middle ear," would have to be divided into several distinct classes. Even at the present time we are able to recognize decided differences between these cases. Thus, for example, we may distinguish quite readily three fairly distinct groups.

In the first of these groups may be placed those cases which are characterized by evidences of congestion, and perhaps also infiltration, of the mucous membrane of the middle ear, and by a similar condition of the naso-pharyngeal mucous membrane. The term *chronic hypertrophic catarrhal inflammation of the middle ear* might perhaps be adopted as a suitable name for this group of cases. It is in this class particularly that we should be on the look-out for adenoid vegetations in the naso-pharyngeal cavity.

In a second group the characteristic features are a very transparent drum-membrane (not necessarily much sunken), an apparently unobstructed Eustachian tube, and a smooth, thin, pale pharyngeal mucous membrane. The inner wall of the tympanum, as reflected through the transparent *membrana tympani*, appears to be unnaturally white, in marked contrast with the deeper coloring observed in the cases of the first group. This unnatural whiteness is due to the fact that the extreme thinness of the mucous membrane covering the bone allows its natural white color to be reflected back to the eye of the observer. On questioning such patients, we usually learn that at a certain period of their lives they suffered considerably from naso-pharyngeal catarrh. And in the light of this fact we are justified in assuming that the morbid process, in the ear as well as in the throat, began as a

proliferative inflammation, with great increase in the connective-tissue elements, and ended in the contraction and condensation (hardening) of the newly-formed connective tissue. In this process of contraction—usually, I believe, called sclerosis—the glandular elements disappear, and we have, as the final result, an unnaturally thin, non-vascular, atrophied mucous membrane. The term *sclerosis of the tympanic mucous membrane* would seem, therefore, to be a fairly appropriate one to apply to the cases of this second group.

Finally, in a third group may be placed all the remaining cases, the prominent feature of which is the absence of all discoverable lesions of sufficient gravity to account for the marked impairment of the hearing. We can simply guess at the real nature of the pathological changes in such cases. In some of them it is possible that the auditory nerve may be the part affected; in others an anchylosis of the stapedio-vestibular joint may explain the deafness; finally, in others still, the secondary tympanic membrane may have undergone thickening or calcareous degeneration, or an exostosis<sup>1</sup> may have encroached upon it. All these lesions have been observed after death, but it is easy to understand how difficult, not to say impossible, it would be to recognize any such pathological conditions during the patient's life-time.

We may encounter cases belonging to the first group at almost any period between the tenth and the fortieth or forty-fifth year of life. Those belonging to the second group are rarely encountered before the thirtieth year; while the type of aural disease which characterizes cases of the third group may be seen in individuals of almost any age after childhood. In all the cases of these three groups the histories given are almost always the same. In those belonging to the first group we are apt to hear of ups and downs, but in those belonging to the other groups the histories all point to either a stationary course, as regards the hearing, or to one in the direction of more marked deafness. The *loss of hearing* may take place quite rapidly; as a rule, however, the progress toward absolute deafness is a very slow one, and that extreme limit is rarely reached. The loss of the hearing may be a steadily progressive one for a certain period of years or months, and then, for many years, or for the remainder of life, it may make no further progress. Taken as a class, these cases are practically incurable. If our diagnosis has been correctly made, we may say, without hesitation, that no material improvement in the acuteness of the hearing can reasonably be expected from treatment, except possibly in the first class of cases. In these we

<sup>1</sup> At the post-mortem examination of a patient who died in the Heidelberg Hospital, in 1869, I found the head of one hammer enlarged to nearly double its natural size by an exostosis which sprang by a broad base from the very top of the little bone.

must assume that a certain amount of fresh disease (or an exacerbation) has been grafted upon the original chronic malady, and to this more recent disease we may direct our therapeutic efforts with some hope of moderate success. Then, again, there is an element of hope in another direction. The physician sometimes (alas! not very often) mistakes a comparatively recent and curable affection for one of a chronic and incurable nature. A suitable course of treatment soon reveals the erroneousness of the diagnosis, by rapidly restoring the patient's hearing.

In many of the cases belonging to the first group there are etiological factors at work which it is highly important that we should detect and if possible remove. Some of these are direct exciting causes of the disease. Among these I may mention the irritating effects upon the naso-pharyngeal mucous membrane of tobacco smoke. Those who indulge only to the extent of one or two cigars per day, manifest either no effects at all or only a trifling degree of local irritation; while those who smoke their five, eight, or ten cigars daily scarcely ever fail to present to the eye of the inspecting physician a pharynx closely resembling that of a scarlet-fever patient. Such patients are surprised to learn that their throats are not perfectly normal. Woakes, I judge from the following extract,<sup>1</sup> attributes these local effects to the entrance of the tobacco poison into the system and not to the mere physical contact of the smoke with the naso-pharyngeal mucous membrane. He says: "Now, while the foregoing is the course of symptoms in a typical case of tobacco poisoning, there can be no doubt that habitual smokers who affirm they experience none of these effects, do notwithstanding manifest some evidence of the physiological action of the drug in the induction of what may be termed a very mobile state of the vaso-motor centres primarily affected by it, rendering them peculiarly susceptible to any superadded disturbing influence. In this way may be explained the peculiar liability to post-nasal catarrh, and noises in the ears to which smokers are liable, as well as the difficulty of getting rid of these troublesome ailments as long as the habit is continued. It is, moreover, probable that this peculiar mobility of the vaso-motor centres is transmitted by great smokers to their offspring, giving rise to the tendency to ear disease, croup, and extreme liability to nasal catarrh seen in the children of some families. I entertain very little doubt that there exists a tobacco cophosis just as there is a tobacco amaurosis. Where excess in alcohol obtains as well as of tobacco, all these proclivities will be intensified; the effects on the succeeding race will then be most manifest. The experience of every medical man in extensive family practice will justify these observations." It seems to me,

<sup>1</sup> On Deafness, Noises and Giddiness in the Head, London, 1879.

however, that if this view of the relationship between tobacco-smoking and post-nasal catarrh were the correct one, we should expect to find the same sort of pharyngeal catarrh in tobacco-chewers who do not smoke. In point of fact, they are, according to my experience, free from any special catarrhal tendency. Furthermore, I have frequently been obliged to allow patients who were excessive smokers the privilege of chewing *ad libitum*; for in no other way could I wean them, even for a period of two or three weeks, from the smoking habit, and in these cases I have seen the naso-pharyngeal catarrh subside as rapidly as it does in those who entirely stop the use of tobacco in any form. Tobacco smoke, therefore, I believe, may properly be classed as a direct irritant of the naso-pharyngeal mucous membrane. Dust, the pollen of certain plants, the decomposing secretions of the parts themselves or of adjacent organs, and, to a certain extent, the direct influence of heat, cold or moisture upon the mucous membrane, may all be mentioned as direct exciting causes of a naso-pharyngeal catarrh. In a case which came under my care during the past winter I was struck with the purulent character of the secretion which found its way from the posterior nares down into the pharynx. I was also struck with the fact that the patient could at any moment draw down into his mouth, by a hawking effort, an appreciable quantity of this purulent secretion. A dead tooth on one side of his upper jaw suggested the probability of chronic purulent disease of the corresponding Highmore's antrum. Dr. Goodwillie, to whom I referred the patient, corroborated the correctness of my suspicions, and in a very short time succeeded in giving him entire and apparently permanent relief. He extracted the decayed root of the tooth, drilled a channel through the bone from the bottom of the root-cavity into the antrum, evacuated about half an ounce of decomposing pus, and then washed out the cavity thoroughly with a disinfecting fluid. This latter step was repeated every day or two for several days, and was stopped only when there were no longer any evidences of a continuing discharge. This cause is doubtless of rare occurrence, and yet I imagine that it must be often overlooked. In fact, I can recall two or three cases which presented the same symptoms as those which I have just described, and yet at the time it never occurred to me to suspect the antrum of Highmore as the source of the trouble.<sup>1</sup>

An obstructed nasal passage is also a promoting factor in certain cases of naso-pharyngeal catarrh. It favors the stagnation and decomposition of the natural secretions and so supplies a direct source of irritation.

<sup>1</sup> While reading these proof sheets I have seen another case of this nature. A large quantity of pus has been evacuated from the antrum, and the patient is now undergoing treatment for this the fundamental cause of his persistent naso-pharyngeal catarrh.

We come now, finally, to a consideration of the remoter, indirect causes. Exactly how these operate, we do not know. We can no longer doubt the reality of the relationship between a lithæmic or gouty state of the system and the contemporaneous naso-pharyngeal catarrh, but we are not yet able to speak confidently of the exact way in which this relationship of cause and effect is brought about. In the same way we recognize the possibility of setting up a naso-pharyngeal catarrh through the simple act of getting the feet wet. We do not know positively, however, along what paths the influence set in motion by the wetting of the feet travels upward to the pharynx; nor do we know why, in one case, it travels straight to this latter region without turning off, so to speak, into a gastric or intestinal by-path, while, in a second case, it will go immediately to the bowels and leave the pharynx unaffected. These reflex influences, as they are called, probably follow the paths of the vaso-motor fibres of the sympathetic nerves, and their mechanism is thus described by Woakes in the work quoted on a preceding page:—

“As the result of the study of numerous morbid conditions involving the vaso-motor apparatus, I have been led to conclude that the sympathetic ganglia not only play the part of secondary centres, or sub-centres, receiving and transmitting impressions quite independently of the general centre; but that they are also *correlating organs*, by means of which afferent tissue impressions from one direction are reflexly referred to a totally different tract; the afferent impressions being manifested through their medium as efferent impulses in the area to which they are thus reflected. In other words, the sympathetic ganglia are so many stations situated on the lines traversed by vaso-motor impressions, in which the ‘points,’ so to speak, are managed, and by means of which impulses are transferred from one line to another.

“There is one other inference that appears to be borne out by the facts now under consideration, *viz.*, that the numerous ganglia distributed about the branches of the fifth and other cranial nerves do really belong to the series of the sympathetic ganglia proper, and that they subserve the same function of deflecting from their ordinary path any strong impression that may reflexly pass through them.

“Now, when a vaso-motor impression proceeds in the manner just sketched from the nerves involved in some morbid process going on in a given part, it usually declares itself by a dilatation of the vessels in the region or area to which the impulse is communicated, thus allowing the vessels of this region to become greatly distended with blood. To such an extent will this dilatation proceed that the quantity of blood pumped into the relaxed arteries may be ten or twenty times as much as would flow

through it when the vessel concerned is in equilibrium. The various tissues intervening between the seat of the exciting cause and the locality to which the dilating wave has been reflected, are in the meantime quite free from any abnormal manifestation."

In this connection, I will mention two experiences which I have had recently, and which show how these reflex causes of a naso-pharyngeal catarrh may emanate from remotely situated parts of the body.

The first case is that of a patient who had for years been more or less of a sufferer from naso-pharyngeal catarrh, with tinnitus aurium and slight impairment of the hearing, and who, more recently, had begun to suffer from feeble digestion. This patient observed that whenever he indulged in certain articles of food he would experience abdominal discomfort and at the same time a marked exacerbation of his naso-pharyngeal catarrh. While the offending substances were in the stomach he experienced only a slight sense of discomfort; but as soon as they had left the stomach, that is, in the course of from three to four hours after he had eaten, a slightly painful peristaltic movement of the bowels would set in, and simultaneously the secretion from the vault of the pharynx would become unpleasantly active and the singing in his ears would become troublesome. This state of things would last for an hour, or at the most two hours, and then the abdominal discomfort and the other symptoms named would gradually disappear; or rather, the naso-pharyngeal catarrh and the tinnitus would return to their habitual state of slight and comparatively insignificant activity. These attacks were invariably accompanied by the escape of large quantities of gas from the stomach by eructation, and sometimes by a few qualms of nausea.

The second case is that of a lady, about forty years of age, and otherwise in good health, who consulted me for the relief of a distressing tinnitus involving both ears. She had experienced the symptoms of a mild naso-pharyngeal catarrh from time to time during a period of many years. Her hearing had not been affected and there were times when she was almost entirely free from the tinnitus. Her digestion had always been good. I saw her at intervals of a few months and always succeeded in giving her prompt relief by applying a moderately strong silver nitrate solution, with a mop of absorbent cotton, to the vault of the pharynx, on alternate days. There came a time, however, when these applications failed to give the desired relief. The tinnitus became almost unbearable. I then learned from the patient that she had been a sufferer, for many years, from pain in the pelvic region and back, and that at this particular time she was suffering to a more marked degree than usual. I urged her to consult a specialist with regard to the suspected uterine disease, and she finally but very reluctantly consented to do so. In this way it was ascertained that the fundamental trouble was a retroversion of the uterus, associated with a chronic subacute parametritis which, from time to time, under the provocation of too much running up and down stairs, etc., became acute. Under proper treatment the parametritis was subdued, the uterus was restored to its proper position and kept there by means of a suitable pes-



sary, and finally, without any further local treatment of the vault of the pharynx, the tinnitus gradually disappeared altogether. From that time to the present (a period of about one year) the naso-pharyngeal catarrh and the distressing subjective noises have been so slight as to require no further use of the silver solution.

The case which I have just narrated in outline is the only one of the kind that I remember to have seen. However, it has impressed me with the belief that I shall encounter similar cases not so very infrequently hereafter, and that their apparent rarity in the past has probably been due to the fact that I had not given much thought to the probability of such a connection existing between the two diseases, and consequently did not make any effort to ascertain whether any inflammatory action was going on within the pelvic cavity, or not.

The question will be very likely to suggest itself to some, Are not the reflex influences referred to above, competent to act as the *direct* causes of a naso-pharyngeal catarrh? As will have been remarked, I have spoken of them only as indirect causes, that is, as factors which are competent to aggravate and heighten a pre-existing but perhaps more or less latent catarrhal disease. I see no fundamental reason, however, why these reflex influences may not also, in certain cases, play the part of direct exciting causes; but I think it would be almost impossible to demonstrate the correctness of this belief, and therefore I prefer to adopt the view which assigns to them a less independent *rôle*.

In discussing the *treatment* of cases of chronic catarrhal inflammation of the middle ear it will not be practicable to lay down well-defined rules of procedure. Each case will have to be judged by itself, and the treatment—if undertaken at all—must be made to fit the requirements of the particular case. So far as the second and third classes or groups of cases are concerned, it is generally useless to even attempt to carry out therapeutic measures. A certain number of cases belong partly to the first and partly to the second group. In these, and as a matter of course in all those of the first group, treatment is certainly indicated. All the different factors which may contribute to the continued activity of the catarrhal disease must be carefully searched out, and measures adopted to remove them or diminish their force. In all the younger patients palpation or rhinoscopic inspection of the vault of the pharynx, or both combined, should not be omitted. Hypertrophied glands in this region are by no means uncommon, and if they be present all other therapeutic measures are of trifling importance in comparison with their thorough removal by instrumental means. As this part of the subject is fully discussed elsewhere (p. 171 *et seq.*), I may be permitted to pass at once to the consideration of other matters. The application of remedial solu-

tions, preferably the silver solutions of different strengths, to the vault of the pharynx, constitutes the most efficient means within our reach for quieting the secreting activity of the mucous membrane of this region, and of reducing the swelling which forms a necessary part of the catarrhal process. As something supplementary to the doctor's efforts the patient may with advantage use three or four times daily a nasal spray of Listerine and water (one part of the former to three of the latter.) These measures, together with the inflations according to Politzer's method, comprise all that is necessary in the way of local treatment.

As regards the removal of the remote exciting causes, I can only speak in a very general way, as a treatise on ear diseases is not the proper place in which to discuss disturbances of nutrition and gastro-intestinal affections or to lay down the law in regard to the management of uterine diseases. A chronic naso-pharyngeal catarrh, in a person suffering from lithæmia, is an exceedingly stubborn affection to treat. Local applications alone seem to make very little impression upon the swollen mucous membrane. In former years, before I appreciated how important a part this lithæmic condition played in the causation, or at least aggravation, of these chronic catarrhs, I used to wonder at the insignificance of the results obtained by my systematic paintings of the pharynx with nitrate of silver solutions. At the present time I can see how irrational such treatment was. It dealt with a mere surface manifestation of the disease, while ignoring the chief underlying cause.

The proper way of managing these cases is to aim first at securing the complete elimination from the circulation, and from the tissues generally, of the offending materials. Inquire minutely into the patient's daily life, as regards the amount of physical exercise which he is in the habit of taking, and also as regards his diet (both food and drink). Almost invariably it will be found that the patient takes far less exercise, especially out-door exercise, than is essential to the proper elimination of the waste materials of the body. Insist upon it—in the case of a full-grown man—that he shall get, on an average, not less than four miles of walking daily, or the equivalent of this in some other form of open-air exercise. In the matter of diet, he should be urged to leave off coffee, pastry, and all alcoholic drinks—or else to add an extra mile or two of walking as an offset to these indulgences. A warm bath every night, followed by brisk rubbing with a coarse towel, will stimulate the skin to perform its emunctory functions with increased vigor. Every morning, or every other morning, on rising, and at least half an hour before breakfast-time, he should take a heaping teaspoonful of Rochelle salts dissolved in a tumblerful of water. This will serve the double purpose of

facilitating elimination by way of the kidneys, and of stimulating the bowels to greater activity. A glass or two of Vichy water, taken during the course of the day, between meals, will serve as an additional aid in facilitating the processes of elimination.

There are not a few patients, generally men of portly habit and well-to-do in the world, who seem to lack the energy necessary for the faithful carrying out of these instructions in regard to exercise, etc. They are so stereotyped in their daily business habits that they resent any advice that calls for the slightest disturbance of these habits. Such patients often find it easier to give up their business altogether for two or three months; and when this is the case I urge them to go abroad, and spend a month or six weeks at Carlsbad, Aachen, Baden-Baden, or at any other well-organized bathing establishment, where the systematized drinking of the waters, under competent medical guidance, together with a simple diet, regular hours of retiring, and quiet out-door life, exerts a markedly beneficial effect upon the lithæmic condition in general, and upon the local pharyngeal condition in particular. It seems strange that in our own country we should still lack similarly well-organized bathing establishments. There certainly is no lack of suitable medicinal springs, but, unless I am inadequately informed on the subject, there is not a single bathing institution in the country where we can send a patient with the same degree of confidence as we can to Carlsbad, Aachen, or a dozen other places that I might name.

In a few cases, as, for example, those of women with uterine affections, and of men with rheumatic or gouty affections of the lower limbs, we cannot secure the desired amount of voluntary physical exercise, and we are consequently compelled to fall back upon the less valuable methods of passive exercise—massage, the so-called parlor gymnastics, etc. While these means are not so effective as good out-door exercise (walking, riding, rowing, tennis, etc.), they can nevertheless be relied upon, if carried out faithfully and intelligently, to accomplish the same results in the course of a longer period of time.

There still remains to be considered the question, For how long a time is it desirable to continue the local applications to the vault of the pharynx? Here, again, we are dealing with a matter which cannot be brought within the jurisdiction of fixed rules. In the acute and subacute cases of comparatively recent origin, the question propounded above is generally an easy one to answer, for the return of the hearing to the normal standard and the disappearance of all other subjective aural symptoms indicate clearly enough that it is time to stop treatment. But in the chronic cases we can only hope, at best, to restore a part of the lost hearing, and it therefore becomes a difficult matter to deter-

mine the particular time when our therapeutic procedures shall have ceased to accomplish beneficial effects. Roughly speaking, I may say that local treatment will be found desirable for a continuous period of not less than two weeks nor more than six; the applications being made regularly on alternate days. The results of the treatment as shown in the condition of the naso-pharyngeal mucous membrane and in the patient's subjective condition, must determine whether the shorter or the longer of these periods will be required in any given case. After the parts have had a rest of a few weeks or months, it may be found desirable to resume local treatment for a short time, in order to subdue again some fresh lighting up of the old trouble.

The *prognosis*, in cases of chronic catarrhal inflammation of the middle ear, is in most instances not good. A person who has been noticeably deaf for a period of several years, as a result of the slow and insidious progress of catarrhal disease, may dismiss all hope of recovering any material part of the lost hearing power. This is emphatically true of those individuals who hear better in a noise, and of those who already show unmistakable evidences of the condition described as sclerosis. On the other hand, those who belong to the first of the three classes described at the beginning of this chapter, often experience a very gratifying degree of improvement under treatment. Not infrequently patients apply, not for the relief of the deafness—for they express boldly their belief that it cannot be bettered by treatment—but for the relief of a distressing tinnitus. To such individuals we can often offer some slight degree of hope, especially if we find the pharyngeal mucous membrane to be in an inflamed and swollen condition, or if we find that some disorder of the stomach, liver, intestinal canal, or uterus is promoting, reflexly, the congested state of the pharynx and ear. Furthermore, it is not a small achievement to bring the naso-pharyngeal catarrh (and the associated aural disorder) to a condition of latency or less pronounced activity; and I believe that we can justly claim, as therapeutists, to be able to accomplish this in a large proportion of cases.

## CHAPTER IX.

### ACUTE PURULENT INFLAMMATION OF THE MIDDLE EAR.

As I have already stated in another place, both forms of acute inflammation of the middle ear, the catarrhal and the purulent, rarely originate in any other way than by an extension of the irritation or inflammation from the naso-pharyngeal space along the Eustachian tube. In scarlet fever and small-pox it is quite possible that the inflammation peculiar to these diseases may develop primarily in the middle ear, as well as by extension from the naso-pharyngeal space. However this may be, the fact remains that the nasal or naso-pharyngeal symptoms usually precede the aural. Scarlet fever stands at the head of the list of diseases which are apt to be followed or complicated by a purulent inflammation of one or both middle ears. Measles should perhaps be placed next on the list; and then follow, in about the order in which I name them, small-pox, typhoid fever, cerebro-spinal meningitis. Another very common cause is an acute "cold in the head," or naso-pharyngeal catarrh. I have known heat-prostration to be followed by acute purulent inflammation of the middle ear. A blow, a fall, or a sudden concussion of the air may induce a similar inflammation. During the summer season, ocean-bathing, or, rather, bathing in salt water, figures prominently as a cause of purulent inflammation of the middle ear. The different methods of flooding the nasal passages with remedial solutions or with simple water are all liable to produce an acute inflammation of the middle ear. Dr. Cornwell, of Youngstown, Ohio, in *The Transactions* for November, 1879, refers to a case that occurred in the Brooklyn Eye and Ear Hospital, in which an acute purulent inflammation of the middle ear followed the introduction of the vapor of chloroform and ether through the catheter into the middle ear. Finally, in addition to these, I should mention the establishment of an artificial opening in the drum-membrane as a not uncommon exciting cause of the change from an otitis media catarrhalis, with a serous or mucoid exudation, to an otitis media purulenta.

It is held by some authorities that a diffuse inflammation of the external auditory canal may extend to the middle ear, and

set up there a purulent inflammation, with perforation of the membrana tympani. I do not remember ever to have seen a case in which this sequence of events, the reverse of that which we usually encounter, took place. I should feel much more disposed to believe in the development of an otitis media purulenta from an extension of an inflammation of the brain or its meninges, as is claimed to be a fact by some German authorities.

*Pathology.*—In my description of the acute catarrhal form of inflammation of the middle ear, I spoke of the changes observed in the drum-membrane when the disease had reached its highest point. These appearances are precisely the same as those observed in the purulent form of inflammation at a certain stage in the progress of the disease. While in the catarrhal form these appearances from that time forward steadily become less and less marked, until finally the drum-membrane returns to its natural state, in the purulent variety a series of other changes first takes place before the stage of retrogression and healing sets in. These changes, which I will now endeavor to describe, are probably never all observed in a single case. On the other hand, an attack of acute purulent inflammation of the middle ear can scarcely run its course without developing one or more of them.

In well-marked cases, one of the most characteristic changes often observed is the formation of a sac or bleb, containing a colorless or blood-stained serum, at the upper boundary of the drum-membrane, close to the short process of the hammer. Such a bleb may form at any point of the periphery of the drum-membrane, though it is more apt to form at the point mentioned than at any other. The main trunks of the blood-vessels of the membrana tympani congregate at this spot, and the strain upon them when inflammatory stasis takes place is probably very great. If a rupture of one of these vessels does not take place, the blebs formed will be perfectly colorless; generally, however, a rupture does take place, and we then find a dark purplish tumor occupying the region of Shrapnell's membrane, and concealing a part of the membrana tympani. With regard to the size of these cystic tumors, I may state that I have sometimes seen them of sufficient size to fill the inner end of the meatus and completely conceal the drum-membrane. In the majority of cases, however, they are much smaller, viz., from the size of a pin's head to that of a No. 2 shot. These tumors are occasionally seen in cases of acute otitis media catarrhalis, but they are far more common in the purulent form of inflammation.

The development of a bulging condition of the posterior half of the drum-membrane is another change which may be said to be almost always present in the really acute cases when they reach the proper stage. This bulging is of course due to the

pressure of the fluid exudation that is contained within the tympanum, and that is constantly increasing in quantity. In some cases it develops at a comparatively early stage of the attack; in others it may not occur until after the tissues of the drum-membrane and surrounding skin of the canal have become so much infiltrated that a distinct convexity (outward) of the posterior half of the membrane can scarcely be recognized.

Simultaneously with the development of the bulging condition, and sometimes previous to that event, or independently of it, an exudation of fluid takes place upon the outer or free surface of the drum-membrane. At first this exudation causes the dermoid layer of the membrane to become white and opaque. Then follows a period of several hours, or two or three days, during which sufficient fluid is thrown off from the inflamed drum-membrane to render the external auditory canal perceptibly moist. In this scanty secretion whitish flakes or masses of epidermis are usually found. The drum-membrane, during this period, is apt to present a whitish appearance. Ordinary syringing or mopping with the cotton-holder, armed with cotton, will often fail to remove this outer whitish layer, and thus a novice may easily be misled into believing that he is looking at a pale and uninfamed drum-membrane. With the aid of the slender middle-ear probe or the smaller curette, one can readily satisfy himself that beneath this whitish, soaked epidermis the drum-membrane presents all the appearances of being intensely inflamed. At a somewhat later stage this clinging of the soaked epidermis to the subjacent tissues ceases to be a noticeable feature.

The participation of the soft parts of the adjacent external auditory canal in the inflammation of the middle ear is an event that would be naturally expected, in view of the intimate vascular and nervous relations that exist between these two regions. In the less severe cases this participation is very slight; in the more severe ones it may lead even to the complete obliteration of the calibre of the osseous portion of the canal.

Again, the drum-membrane, partly under the effects of the pressure from within and partly through the melting away or death of a limited portion of its substance, gives way at some point, and thus affords relief from the tension of the fluid in the tympanum by furnishing it with an outlet. Such a perforation may develop at any part of the drum-membrane. One would expect that the part most likely to become the seat of such a rupture would be the central portion of the posterior half, where the tension usually seems to be greatest. While the tension may seem to be greater at this part of the membrana tympani than at any other, it is probably a fact that the tension is equally great at all points of the membrane. If this be a fact, the *apparent*

difference in tension must be due to an optical delusion, which in turn is probably favored by the circumstance that the posterior half of the drum-membrane is much nearer the observer's eye than the anterior half. From the fact that the perforation may occur at almost any part of the membrane it is fair to assume that the rupture occurs at that spot which is weakest, either through a congenital or through an acquired defect in the nutrition or structure of the part. In scarlet fever, and perhaps also in small-pox, it is probable that an actual death of a limited area of the drum-membrane—or sometimes even of the entire membrane—has more to do with the development of the perforation than has the direct force of pressure. How else can we explain the enormous losses of drum-membrane tissue observed after scarlet fever in young children? I once had the opportunity of observing this gradual melting away of a considerable portion of the membrana tympani in a boy four years old. I was called to see him soon after desquamation had ceased, and perhaps three or four days after he had begun to complain of his ear. The canal was slightly moist, and the drum-membrane was covered with a whitish pasty material. There was only a moderate degree of bulging, and the boy complained very little of pain. In the course of one or two days I recognized the existence of a small perforation in the central portion of the membrane. Little by little this perforation increased in size until, after the lapse of about two weeks, it measured perhaps a full millimetre in diameter. I then lost sight of the child for a period of nearly one year. During this interval the mother had occasionally observed a slight discharge from the ear, but she attached very little importance to it. On examining the ear, I was surprised to find that the entire central portion of the drum-membrane had been destroyed, the opening which remained measuring easily four millimetres in diameter.

Cases of acute purulent inflammation of the middle ear differ very materially one from another in respect of the degree of swelling of the mucous membrane. In some the inflammation seems to spend itself in throwing out an abundant secretion from the free surface of the mucous membrane, which in that event undergoes comparatively little swelling; while in other cases—and these are usually the more severe ones—the mucous membrane becomes enormously swollen through infiltration of its tissues. It is probably under conditions like these that the adhesions and false bands occasionally observed in the middle ear are formed.

Finally, in every case of acute purulent inflammation of the middle ear, it is important to bear in mind that the communicating system of cavities, the mastoid antrum and surrounding cells, can scarcely escape being involved to a greater or less degree



in the inflammation. At one or more points vessels pierce the bony roof of the tympanum, and along these the inflammation spreads to the dura mater and membranes of the brain. *A localized meningitis may be assumed to exist in every severe case of acute purulent inflammation of the middle ear*; though, as a matter of course, it is only in a very small minority of the cases that it spreads to the ventricles, involves the brain-substance proper, or becomes a more general meningitis.

*Symptomatology and Course of the Disease.*—The development of pain in the ear is the most striking, if not the first symptom noticed by the patient. In infants, and even sometimes in children two or three years of age, the physician is often puzzled to know what ails the child, and the first hint that he receives with regard to the real cause of the patient's fretfulness and feverish condition is that afforded by the appearance of a slight discharge at the outer orifice of the ear. Teething is very apt to be assumed as the cause of the fever, and thus many a case of severe inflammation of the middle ear is allowed to run its destructive course unrecognized and consequently unchecked. It is greatly to be regretted that physicians in general practice should not more frequently suspect an inflamed ear of being the source of these obscure attacks of illness in children. Upon the development of a perforation, the patient often experiences marked and speedy relief. "I felt something give way in the ear, a watery discharge appeared, and the pain soon subsided," is a statement which one often hears patients make. In many cases, however, the rupture of the membrane affords little or no relief. This is probably due, in the great majority of instances, to the insufficient size of the outlet. As the pus can only escape under considerable pressure, when the perforation is small the tension, which is the chief cause of the pain, continues, and the patient of course experiences little or no relief from his suffering. In a few cases the Eustachian tube affords an outlet for some of the exudation, and the patient can distinctly feel the fluid trickling down the side of his naso-pharyngeal space. These cases, however, are comparatively rare, for as a rule the parts surrounding the tympanic orifice of the tube are so much swollen that even compressed air fails to effect a passage through it. Among the symptoms of minor importance may be mentioned: a sensation of fulness and sometimes of throbbing or pulsation in the affected ear; subjective sounds of various kinds, such as roaring, singing, whistling, etc.; more or less marked impairment of hearing in the affected ear; increased pain when the jaws are opened and shut; tenderness on pressure over the orifice of the external auditory canal, etc. The two last-named symptoms indicate that the inflammation has spread from the middle ear to the outer meatus.

All these symptoms may then gradually subside, and in the course of ten days or two weeks from the onset of the disease the patient may be quite well again and free from all symptoms referable to the ear. Such an attack, in the course of which no alarming symptoms manifest themselves, may be designated as one of moderate or average severity.

The following case affords a good illustration of the course pursued by a simple, uncomplicated attack of acute otitis media purulenta:

The patient, a boy four years of age, began to complain of pain in the right ear early in the afternoon of May 30, 1877. He seemed unnaturally languid, and manifested no desire to take part in the other children's play. In the course of two or three hours the pain disappeared. During the night he awoke several times, and each time complained of his ear.

May 31st.—Frequent paroxysms of pain, of short duration. Membrana tympani red and swollen; near its posterior border, low down, the dermoid layer is raised into a well-marked bleb by an effusion of serum between it and the deeper layers of the membrane.

June 1st.—The child slept well last night, after taking two drops of Magendie's solution of morphine. A few paroxysms of pain during the day.

June 2.—Patient slept well last night without morphine. No pain in the ear. No appreciable heat of skin and no acceleration of the pulse; yet the child refuses food, and looks pale and languid. Early in the afternoon the ear became quite painful, but in the course of two or three hours the pain disappeared again.

June 3.—Patient awoke this morning with a sharp earache. Pressure both in front of and behind the ear causes pain. The posterior half of the membrana tympani is now (10 A.M.) markedly bulging and of a diffusely red color. I incised it freely, and gave exit to a blood-stained serum. In less than ten minutes the child fell asleep and slept soundly until 4 P.M. While he was asleep the discharge from the ear—a pinkish serum—was constant and very abundant. At five o'clock he took food, for the first time in several days, with apparent appetite. The ear, he says, is entirely free from pain.

June 4.—The discharge is growing thicker and more like ordinary pus. No return of pain. Appetite good. Expression of countenance has entirely changed.

June 8.—Discharge has ceased. Drum-membrane has almost resumed its natural appearance. The boy seems to be perfectly well again.

In this case the disease developed in a perfectly healthy ear. The subject of the disease, furthermore, was a healthy child. These two facts explain in a measure why the recovery was so prompt and complete. In adults, and especially in those who have passed through previous attacks of inflammation of the middle ear, recovery takes place as a rule more slowly. The following case furnishes a very marked instance of the slight healing powers possessed by some individuals:

The patient, a gentleman, forty-two years of age and in fair general health, consulted me on the 1st of February, 1880. He said that during the previous two or three weeks he had been so much annoyed by a bad cold in the head that he had repeatedly snuffed warm salt water. He had never experienced any but good effects from this procedure. A few hours before calling to see me, however, he began to be conscious of a sensation of fullness in the right ear, and, as he had passed through several attacks of acute inflammation of the ear, he felt anxious lest this might prove to be the beginning of a fresh attack. I examined the right ear and found the membrana tympani slightly congested at the periphery, especially superiorly and along the handle of the hammer. Watch heard at a distance of eight or ten inches. I advised him to send for leeches and a Clarke's douche if actual pain should come on later.

On February 2d I visited the patient at his house. He reported that soon after he returned home from my office the pain in the ear became quite severe, and continued throughout nearly the entire night. Toward morning he heard moist sounds in the ear, and at 6 A.M. he experienced simultaneously a sensation of relief from pain and a profuse outpouring of bloody serum from the ear. At 11 A.M., when I visited him, I found the pillow, night-gown, handkerchief, and numerous pieces of cotton-wool fairly soaked with the discharge. The pain had disappeared completely. The inner end of the canal was so swollen that I could only make out the existence of a central perforation. The swollen parts were gorged with blood and looked purple. The remainder of that day the discharge continued to be very profuse, and still appeared like bloody serum.

The following day (February 3d) the discharge steadily diminished and began to grow more yellowish. On examination with the speculum I found the perforation to be a little larger than the head of a pin of average size. The swollen walls of the canal had lost their purplish hue and were simply pink, and less swollen.

From this time forward, for a period of about two weeks, little or no change took place in the condition of the ear. The discharge, which was only moderate in quantity, never became thick like pus, nor did it assume any of the characteristics of mucus: it remained thin and very yellow, or at times yellowish green. Powdered iodoform, powdered burned alum, and solutions of nitrate of silver of different strengths, all failed to exert any very marked effect upon the discharge. As the patient had been treated for syphilis eighteen or twenty years previously, I thought that this poison might possibly have something to do with the remarkable sluggishness of the parts, and I accordingly prescribed the bichloride of mercury ( $\frac{1}{2}$  gr.) and iodide of potassium (gr. x.), to be taken three times a day. Finally, as a last resort, I advised the patient to visit Florida and remain there for one, two, or three weeks, according to the effects produced upon the ear. This advice was followed, and the change of climate, scene, and diet accomplished what local treatment had failed to do. When the patient returned, after an absence of a little over three weeks, I found the drum-membrane healed, and the adjacent canal only a very little swollen. The discharge had ceased already several days previously.

In the case just narrated I should have mentioned the fact that the patient had been for years affected with an aggravated naso-

pharyngeal catarrh. At the time when I examined his throat, a mass of very tough, dirty yellowish mucus occupied the naso-pharyngeal cavity. Beneath and around it the mucous membrane was very red, dry, and swollen. I made several applications of nitrate of silver to these parts, but the beneficial results produced were very slight. It was quite probable that this persistently inflamed condition of the naso-pharyngeal mucous membrane contributed materially to keep up the inflamed condition of the adjacent tympanic mucous membrane.

Some persons possess a decided predisposition to acute inflammation of the middle ear. This is particularly true of children with enlarged tonsils and marked chronic naso-pharyngeal catarrh. Every fresh "cold in the head" in such individuals usually means a fresh attack of acute inflammation of the middle ear. If we examine their ears during the interval between the attacks, we rarely fail to find the drum-membrane more or less congested and generally drawn in beyond its proper plane. This predisposition is observed much less often in adults. The most striking case of the kind that I can recall is that of a woman, a seamstress, about thirty-five years of age and in apparently vigorous health, who during a period of about six years had at least as many well-marked attacks of acute inflammation of the right middle ear,—some of them ending in a perforation and a discharge of pus, others subsiding without going as far as this. I treated her during three or four of these attacks, and each time relieved her of her intense pain by freely incising the posterior half of the membrana tympani. The employment of leeches and the hot douches simply afforded temporary relief. After each incision the discharge of pinkish serum was very abundant, and the subsequent purulent discharge generally lasted but three or four days, the membrana tympani then healing promptly.

The following case affords a good illustration of a somewhat higher grade of inflammation:

The patient, a lady about forty years of age and of decidedly nervous temperament, contracted a bad "cold in the head" during the first week of September, 1878. In the course of two or three days she began to experience pain in the left ear. Various measures were employed to relieve it, and among other things leeches were applied in close proximity to the outer orifice of the ear. The pain, however, steadily increased, and at the time I first saw her (September 18, 1878) it involved the entire left side of the head. She could hear the ticking of my watch at a distance of only half an inch ( $\frac{1}{2}$ ). On inspection I found the membrana tympani slightly bulging posteriorly. The canal was perfectly dry, but the dermoid surface of the membrane presented a soaked appearance. The parts immediately bordering upon the membrane were intensely red and moderately swollen. Ether having been administered, I made a free incision through the

posterior half of the membrane, and carried it upward through a portion of the red and swollen tissues of the posterior fold. A sero-purulent fluid oozed through the artificial opening.

September 19th.—The hot douche was used freely after the drum-membrane had been incised, and the patient remained free from pain for several hours. This morning she is again in suffering. As the douche is used very frequently, it is impossible to state how free the discharge is. On examining the right ear, of which she now complains very decidedly for the first time, I find the membrana tympani and surrounding parts in essentially the same condition as that observed on the left side yesterday. Free incision of the posterior half, to be followed by the use of the hot douche.

September 20th.—Pain in the right ear relieved; slight watery discharge this morning. Pain in the left ear was severe during the greater part of the night; toward morning it diminished, and she was able to sleep for three or four hours. On examination I find the left drum-membrane concealed by a soft, pale fleshy mass which occupies the inner end of the meatus and appears to be attached to the central portion of the membrana tympani. By pulling upon it with the forceps I ascertained that its peduncle was engaged between the lips of the artificial opening in the drum-membrane. Further traction caused the mass to break off at the perforation. The discharge from the left ear so far as I can learn, has been slight.

September 21st.—Last evening, while I was out of town, the pain in the left ear became quite severe. Dr. Sexton, who was sent for, found the posterior half of the left drum-membrane markedly bulging, and re-incised it. The incision afforded relief, but at the present time (8 P.M.) the pain is again quite severe. On inspection I found a fleshy mass occupying the inner end of the left meatus. It was of a pale pinkish hue, but at one part it presented a decidedly red color. By pulling upon it I ascertained that its peduncle was held fast between the lips of the perforation. In all outward respects, therefore, it was like the mass previously removed. By means of the forceps and Blake's snare I removed all of it that was within reach. Under the microscope a teased specimen presented the appearance of a homogeneous mass of dark granules, interspersed here and there with red blood-corpuscles whose circular outlines were barely recognizable. In some places there were indistinct evidences of fibrillation.

September 22d.—Patient passed a poor night. To-day (9 A.M.) there is tenderness over the squamous portion of the left temporal bone, over the mastoid process, and down along the left side of the neck. She complains of a dull, heavy pain in the left temple and eyeball. The left eye is bloodshot. At 8 P.M. I found the patient in so much suffering that I decided to convert the linear incision in the left drum-membrane into a T-shaped one, in the hope of affording an unobstructed escape for the exudation in the tympanic cavity. The patient having first been rendered unconscious by means of ether, I carried out this step, and also made a long and deep incision over the mastoid process.

September 23.—By aid of opium and poultices patient passed a fair night. This morning (9 A.M.) I find her almost entirely free from pain in the left ear. The pain in the right ear continues, but is not severe. The discharge from both ears is still quite watery in character and not abundant. At 6 P.M. the pain in the right ear became severe. When I saw the patient at 7.30 P.M. I

found decided tenderness over the mastoid process but no œdema nor redness of the integument. Ether having been administered, I made a free incision through the posterior half of the right drum-membrane and also through the mastoid integuments.

September 24th.—Patient slept the greater part of the night, and this morning she seems to be every way better. The discharge from both ears is now distinctly purulent in character, though not abundant.

October 1st.—Steady improvement since last note. Left drum-membrane has nearly healed, and the discharge has ceased. On the right side the discharge still continues, but it is steadily diminishing in quantity. Moderate pain at times in both ears.

October 8th.—Right drum-membrane has healed. Patient is now entirely free from pain.

About ten days later I found both drum-membranes apparently normal. So far as the patient could judge, the hearing had been entirely restored. On testing it with the watch, however, I found a slight degree of impairment.

There are two or three points of interest in the case which I have just narrated. In the first place, linear paracentesis of the left drum-membrane afforded only a temporary relief from pain, and that, too, notwithstanding the fact that the opening, although slit-shaped, was of ample length. In the second place, the development of a mass of fibrinous material in the middle ear, and its expulsion from that cavity through the perforation in the drum-membrane, are events of very rare occurrence. Shall we, with Dr. J. Orne Green, of Boston, consider the attack as one of a high grade of inflammation associated with an exudation of a fibrinous material, or shall we consider it as one of a simple acute inflammation associated, accidentally, with the formation of an ordinary clot of blood? So far as the microscopic examination throws any light upon the question, either hypothesis may be the true one. But if we compare the peculiar conditions observed in this left ear on two different days, with those observed in hundreds of other similar cases, in many of which blood-vessels must have been divided just as freely as in the present case, I think we are justified in drawing the conclusion that Dr. Green's view is the more plausible of the two, and that the fibrinous masses observed were in reality exudation-masses and not blood-clots.

To revert to our first point, viz., the failure of linear paracentesis to afford relief from pain, I have very little doubt that it should be ascribed to the obstruction interposed by this fibrinous material. Steady and marked improvement followed the establishment of an angular opening in the drum-membrane. Such an opening permitted the freest possible escape of all the products of inflammation, while the slit-shaped opening was probably soon rendered useless for drainage purposes by the accumulation of the fibrinous material which effectually closed it.

The following case presents still another type of acute purulent inflammation of the middle ear, viz., one in which the mastoid cavities participate to a certain extent in the inflammation almost from the very beginning of the attack.

The patient, a boy seven years of age and in excellent physical condition, was attacked with a severe pain in his right ear on the 22d of March, 1879. Various measures were tried, but they all failed to give more than temporary relief. On the 24th of March (9 P.M.), when I first saw the patient, I found the following conditions: body temperature, taken in the mouth, 102° F.; external auditory canal normal, except in the immediate vicinity of the drum-membrane, where it was red and somewhat swollen; the drum-membrane itself was covered with a white, pasty coating of epithelium, beneath which the parts were of a bright red color. Although there was no noticeable bulging of the posterior half of the membrane, I thought it better not to wait for this, but to perform paracentesis at once. No visible escape of fluid followed the incision.

March 25th.—Clarke's douche with warm water was used freely during the night, but yet the boy passed a poor night, obtaining very little relief from his suffering. There is now a scanty watery discharge from the ear. Pressure over the mastoid region causes him to wince. One leech to be applied to this region, and the hot douche to be used freely.

March 26th.—Another bad night. Toward morning, however, the discharge became profuse, and the pain disappeared entirely in the course of a few hours.

April 2d.—Yesterday the ear again became painful. The boy had felt so well for several days that his parents allowed him to run about as usual. To-day I find him crying with pain. Inspection shows the inner end of the meatus to be almost closed by the swelling of the soft parts, especially along the upper and posterior wall. Decided tenderness over the mastoid process. Cervical glands enlarged. Moderate fever. Free incision of swollen posterior wall of the meatus. Poultices or dry heat to be applied externally.

April 3d.—Pain has moderated.

April 4th.—Continued improvement.

(Complete recovery followed in the course of about two weeks.)

The tenderness on pressure over the mastoid process furnished, in this case, good evidence of a certain degree of periostitis of that region. The question of its mode of origin—whether by extension from the auditory canal, or by extension through the mastoid cells—is one that can be discussed perhaps to better advantage under the head of *Diagnosis*. In this particular case I am disposed to look upon the subacute mastoid periostitis and upon the more acute periostitis of the posterior wall of the meatus, in the immediate neighborhood of the membrana tympani, as both alike dependent upon an inflammation whose centre of greatest activity was probably located in the mastoid antrum. The more serious forms of mastoid inflammation (both corporeal and periosteal) will be considered in a separate chapter.

Among the most troublesome cases to manage are those in which the products of inflammation seek an outlet through the membrana flaccida, and not through the drum-membrane proper. This membrana flaccida, or Shrapnell's membrane, in certain individuals is so thin and flaccid that the least change in atmospheric pressure in the cavity of the tympanum shows itself at this point sooner than in the drum-membrane. It is a common experience to examine the ear and find a distinct hollow situated above and behind the short process, and then after inflation to find this same region converted into a rounded prominence; while at the same time the drum-membrane proper shows at most only a slight change in its position as a whole. In such cases it is easy to understand how, under the pressure incident to the accumulation of an inflammatory exudation in the tympanum, this particular region should, by reason of its being the place of least resistance, be the spot where a perforation takes place. Before an actual outlet is established,—that is, probably, before the last layer of the tissues, the dermoid, gives way beneath the pressure,—the soft parts immediately surrounding this spot display very marked evidences of a special irritation. They become red and swollen, and if our examination of the ear is made for the first time at this particular stage of the disease, we are not at all likely to diagnose accurately what is the true state of the case. I have incised such swellings in the full belief that I was dividing the posterior half of the drum-membrane, and have only discovered my error after the inflammatory swelling had subsided sufficiently to reveal to me the true relations of the parts. The following case affords a good illustration of the peculiar lesions described above:

The patient, a physician, about thirty-five years of age, contracted a bad cold during the first week of March, 1874. Soon afterward he began to experience pain in the left ear, with a moderate degree of deafness. In the course of two or three days a discharge made its appearance, and the pain at the same time became less severe. On the 17th of March, when I first examined the patient's ear, I found it in the following condition: the external auditory canal, in its outer half, was perfectly normal; in the neighborhood of the drum-membrane it was red and somewhat swollen. After all the pus had been carefully removed, the picture presented at the bottom of the canal was that of a red and swollen drum-membrane (posterior half). Posteriorly and superiorly the swelling merged imperceptibly into the wall of the canal; anteriorly and inferiorly quite a deep recess separated it from the wall of the canal. At the most prominent part of the swelling a slight depression, from which fluid escaped, marked the location of the perforation. As there was comparatively little pain in the ear, so long as the patient remained quiet, I decided to watch the further progress of the case before adopting any more active treatment than simple cleansing of the canal, together with occasional inflations (Poltzer's method).

On the 20th of March, finding that the swollen condition of the



parts persisted, and assuming that the small perforation could scarcely afford an adequate outlet for the discharge, I made a free incision through the swollen tissues.

March 23d.—Persistent pain. Discharge at times bloody. No diminution in the swelling of the membrana tympani. Mastoid integuments, including the periosteum, freely incised.

March 27th.—Decided improvement in all respects. The swelling has now so far diminished that I am able to distinguish quite accurately the relations of the parts. The drum-membrane proper is intact. Just above it, and overhanging its posterior half, is a teat-like swelling which represents the pouting orifice of the perforation or (more correctly) sinus. In the hope of diminishing the degree of resistance which the discharge must encounter in escaping through such a long sinus, I removed a large portion of this teat-like projection with Blake's snare.

On the following day patient took passage on one of the Savannah steamers, in the hope of hastening his recovery by a change of air and scene. About three weeks later (April 17th) he returned to New York. The discharge from the ear, he reported, had ceased entirely on the 13th, and his general condition had greatly improved. On examination, I found that all evidences of active inflammation had disappeared. There was still, however, a small conical projection of the tissues just above the posterior half of the membrana tympani, and at its tip (and forming part of it) was a collection of whitish material—probably cheesy pus. There was no recognizable impairment of the hearing for voice sounds and conversation, but the ticking of a watch was heard at a distance of only two inches.

In March, 1875, every trace of the attack had disappeared, and the ticking of the watch was readily distinguished at a distance of nearly three feet.

The pouting character of the external orifice of the sinus or perforation is not peculiar to perforations in Shrapnell's membrane. I have occasionally observed precisely the same condition, though on a somewhat smaller scale, at or near the centre of the drum-membrane. The prolonged resistance of the dermoid layer to the pressure exerted by the pus is probably as much the cause of the pouting condition here as it is in the region of Shrapnell's membrane.

A few words more with regard to perforations in general. In my own practice I have never known more than one perforation to form in the membrana tympani as a result of an acute inflammation of the middle ear. That two perforations may occur, however, in the same membrane, is clearly shown by the fact that occasionally, and particularly in dispensary practice, we find drum-membranes perforated in two places, or presenting two well-defined cicatrices—evidences of the former existence of perforations. Instances are on record in which three and even four perforations have been observed. However, the presence of more than one perforation in a drum-membrane affords strong ground for the belief that the disease which produced them must have been tubercular in its nature. Finally, I have seen one case

in which the fluid exudation found an outlet for itself, not through the drum-membrane proper, nor through the soft parts above the membrane, but at some point below it. It is hard to conceive how this could have taken place, and yet the evidence in this case pointed very clearly to the existence of a channel of communication between the tympanic cavity and a collection of pus in the lower wall of the external auditory canal.

*Sequelæ and Complications.*—The more important sequelæ of an acute purulent inflammation of the middle ear are: inflammation of the mastoid process (corporeal and periosteal), meningitis, and chronic purulent inflammation of the middle ear with its very numerous lesions. These sequelæ possess the importance of independent diseases, and I will therefore consider them in another chapter. The only affection of any importance that can be considered as a complication of an acute otitis media purulenta is abscess of the meatus. I have before me the incomplete notes of five such cases. In three of these the abscess was located near the outer orifice, and was circumscribed or furuncular in its nature. In the other two a collection of pus formed between the skin (*i.e.*, periosteum) and the bone at the inner and upper portion of the meatus, close to the drum-membrane. In these two cases it seems to me more than likely that a partial perforation took place in Shrapnell's membrane, and that the pus, instead of forcing its way directly through the tissues which form the outer limit of this region, burrowed a way for itself between the soft parts and the bony wall of the meatus. As I did not see these cases, however, until after the collection of pus had formed (toward the end of the second week of the disease), I cannot speak very positively with regard to this point. In the three cases of circumscribed abscess of the canal, the first symptoms of this complication did not show themselves until after all the acute manifestations of the middle-ear inflammation had subsided. In all three cases I felt confident that the abscess was not a legitimate outgrowth of the original disease. In the first case, for example, the abscess was induced, as I believe, by the use of the solution of the acetate of lead, and in the second by the employment of burned alum; while in the third case it owed its origin to a local eczema confined to the outer half of the meatus, and which needed only the irritation supplied by the discharge from the middle ear to fan it into an acute circumscribed inflammation. This sequence of events is by no means uncommon.

The participation of the cervical and post-auricular glands in the inflammatory process is a noticeable feature in quite a large proportion of the cases of acute purulent inflammation of the middle ear. I have never known this sympathetic inflammation, however, to go beyond the point of producing a moderate degree

of swelling and tenderness of the affected glands. In cases in which the mastoid cells are involved to a decided degree suppuration of the glands sometimes occurs.

*Diagnosis.*—If called to see a person who is suffering with an acute inflammation of the middle ear of recent origin, we shall probably at first be obliged to limit our diagnosis to the simple establishment of the fact that the disease is inflammatory in its nature, and to the determination of the locality in which the inflammation is taking place. The disease, we can say, is an acute inflammation of the middle ear, but whether it will go on to the formation of pus, or whether it will recede after reaching some point short of this stage, are questions which cannot surely be answered at such an early stage. As our treatment is not based upon the character of the exudation which is thrown out into the middle ear, we may safely wait for circumstances to reveal the facts with regard to the point in question. If the disease has not progressed so far as to involve the external auditory canal to a marked extent, it is scarcely possible to err in our diagnosis. Even without actual inspection, the patient's account of the attack—in the case of an adult—generally gives us some idea of what particular part of the ear is the seat of the inflammation. Actual inspection of the parts, however, can scarcely fail to remove the last element of doubt. I can think of but two possibilities of error: first, an inflammation of the soft parts lining the osseous portion of the external auditory canal and the outer aspect of the drum-membrane may easily be mistaken for an acute inflammation of the middle ear that has involved (secondarily) the inner half of the meatus; and, secondly, the whitish appearance of the dermoid surface of the drum-membrane, concealing perfectly—as it often does—the underlying inflamed tissues, may mislead an inexperienced observer into the belief that he is looking at an opaque, thickened, and uninflamed membrana tympani. The first error can only be avoided by a careful sifting of all the evidence. An acute inflammation of the middle ear causes more decided deafness and far more pain than does an inflammation of the osseous portion of the canal. Again, the order in which the different symptoms have followed each other furnishes us with valuable aid in deciding which of the two diseases is the one that is under observation in any given case. To avoid the second error, it is simply necessary to demonstrate, by actual manipulation of the parts,—that is, by the use of the slender probe, the curette, or the cotton-holder, armed with a small mop of cotton,—that the surface under observation is a part of the living tissues, and not a pasty, dead exfoliation.

In infants and young children we must rely almost entirely upon what we can ascertain by actual inspection. The mother's ac-

count of the symptoms observed is usually very vague, at best. On the other hand, primary acute affections of the meatus are very rare at this early age.

If we limit our diagnosis, in the class of cases under consideration, to the mere determination of the locality in which the inflammation is going on, our task—judged from the stand-point of practical utility—is but half completed. In order to treat the case intelligently and successfully, we should push our researches much farther. We should have before our minds, for example, a reasonably clear picture of the limits of the inflamed area and of the amount of damage already done by the disease. The color of the drum-membrane, the extent to which it is disfigured, the flatness or rotundity of its movable portions, especially its posterior half, and the degree of inflammatory disturbance in the adjacent cutaneous walls of the canal, all furnish valuable means of estimating the degree of vigor displayed by the inflammation, and the degree of tension or pressure to which the soft parts lining the middle ear are being subjected. Having ascertained these facts with more or less accuracy by direct inspection, our next step should be to try to learn to what extent the inflammation has spread from the tympanic cavity to adjacent parts. Has it spread in the direction of the cranial cavity? The severity of the pain in the head, on the same side as that of the affected ear, affords a rough means of measuring the degree to which the congestion of the adjacent meningeal vessels has progressed. Without insisting too much on the value to be attached to the following statement, I may say that I have been disposed to consider the change from a simple unilateral headache to one more distinctly localized in the occipital or frontal region as an evidence that the meningeal congestion has materially increased in degree and extent. I have observed this phenomenon so often in the more serious cases of inflammation of the middle ear that I think some diagnostic value should be attached to it. Has the inflammation spread to the mastoid region? Pain referred to this region, redness, and perhaps swelling of the skin covering the mastoid process, and tenderness on pressure with the finger,—these are the symptoms which indicate that the mastoid process is participating in the inflammatory process. In this same group of symptoms may be placed another, viz., redness and swelling of the posterior and upper wall of the meatus, in the immediate vicinity of the drum-membrane. Finally, the determination of the patient's body temperature may serve to confirm the opinion that we have formed from the other methods of examination employed. In children we may confidently expect to find an appreciable elevation of the body temperature in all cases of acute inflammation of the middle ear; in adults we also usually find some elevation

of the body temperature, but, as I know from personal observation, this elevation may be markedly disproportionate to the serious character of the damage that is being wrought in and around the ear, and particularly in the cranial cavity. It is therefore unsafe in adults to infer, from the insignificance of the rise in temperature, that the case is progressing well and that no harm need be feared.

The existence of a perforation may be learned by direct observation or by auscultation while air is being forced into the middle ear. If the perforation is small, or if the membrane has not been thoroughly dried with the mop of cotton-wool, it may be impossible to distinguish the situation of the perforation by simple inspection. As a rule, we can readily discover the point of rupture in such cases by asking the patient to perform Valsalva's experiment while we watch the behavior of the drum-membrane. Even then the perforation may be so small that we can simply distinguish the oozing of a little fluid from a certain portion of the drum-membrane. With the slender probe, however, we can always demonstrate the precise spot occupied by the opening. The presence of fluid exudation in the external auditory canal is not to be taken as satisfactory evidence of the existence of a perforation. It may be, and very often is, simply an exudation from the outer surface of the drum-membrane and adjacent inflamed walls of the canal.

*Prognosis.*—An acute purulent inflammation of the middle ear, if allowed to run its course unchecked, will undoubtedly, in the majority of cases, do so without serious detriment to the patient. In the minority of cases, however—and it is by no means a small minority—the disease produces more or less serious damage. An impairment of hearing of variable degree, a chronic and generally offensive discharge from the ear, and even disease of the adjacent organs which may prove fatal, are the prominent items in the catalogue of damages that may result from an unchecked acute inflammation of the middle ear. These facts are now so well known to the profession that I certainly may be excused from the necessity of furnishing satisfactory evidence of the truth of what I say. There was a time, however, and that too within the memory of some of the younger men in the profession, when an acute inflammation of the middle ear was looked upon in a very different light; it was generally considered as one of the diseases of minor importance, and it was accordingly allowed to run its course practically unchecked. As a result of that régime of professional ignorance and indifference with regard to diseases of the ear, there were, and are still in this city alone, thousands of individuals affected with chronic discharge from the ear. In those days, therefore, the prognosis of an acute purulent inflammation of the middle

ear—if based upon the facts of actual observation—must necessarily have been unfavorable, or at least very guarded in its nature, especially where the disease originated in one of the exanthemata. During the past few years, however, a very noticeable change has taken place in two particulars. In the first place, the majority of the better class of practitioners now recognize the danger of allowing an acute inflammation of the middle ear to run its course unchecked. If they do not feel competent to manage this class of diseases themselves, they call to their assistance some professional brother who is familiar with their treatment. In the next place, the number of physicians who are competent to treat a case of acute otitis media has very greatly increased. While these remarks apply more particularly to the city of New York, it is, I have reason to believe, true also of other cities and towns. There is, therefore, no lack of men who know how to prevent the disastrous results which sometimes flow from an acute inflammation of the middle ear. These important changes, both in the state of professional opinion and in that of professional skill, have already led to a marked change in the prevalence of the bad types of chronic purulent inflammation of the middle ear. I speak now entirely from my own personal observation; and in accordance with that I may say that, if we compare the clinical material observed between 1870 and 1875 with that observed in recent years, a very noticeable diminution will be found to have taken place during the latter period in the proportion of cases affected with really serious chronic disease of the middle ear. There is but one plausible interpretation that we can put upon this fact, viz., that the treatment of this disease in its acute stage has been better conducted during the latter than during the former period. In fact, it is not an exaggeration to say that under proper treatment, *if begun soon, i. e., within a few days after the onset of the attack, an acute inflammation of the middle ear rarely results in the patient's death, or seriously impairs the hearing of the affected ear, or passes into a really chronic purulent inflammation.* At the present time, therefore, the aurist, or the general practitioner who has acquired the special knowledge and skill which the treatment of these cases demands, may give a very good prognosis in cases of acute inflammation of the middle ear, provided he be not sent for after serious damage has actually been inflicted by the disease. There is scarcely another department of practical surgery in which the physician can boast of greater triumphs than those attained at the present day in the treatment of acute diseases of the middle ear.

The physician is often asked to state the probable duration of an attack of acute inflammation of the middle ear. The answer must of course depend upon the severity of the attack, upon the

age and condition of health of the patient, upon the degree of inflammation and hypertrophy of the naso-pharyngeal mucous membrane, upon the exciting cause of the disease, upon the surroundings and mode of life of the patient, and various other circumstances too numerous to mention. Assuming that all these circumstances are favorable, we may estimate the probable duration at from ten days to three weeks in the cases of average severity, and at from four to six weeks in those of a more virulent type. In young and healthy children recovery takes place more quickly than in adults. In persons who have passed the middle period of life, the return to a healthy condition of the parts is apt to be slow. In individuals of a consumptive type our prognosis, especially with regard to the duration of the subsequent discharge from the ear, must be very guarded. In these individuals the mucous membrane of the middle ear seems to possess little or no recuperative power, and the discharge may continue for weeks or months, in spite of our best efforts to arrest it. In cases of acute inflammation of the middle ear following scarlet fever or measles we must expect a less prompt recovery, as a rule, than is generally observed in cases which owe their origin to a "cold."

#### TREATMENT.

The different therapeutic measures employed in the management of an acute inflammation of the middle ear may be discussed under three heads, viz., those measures which tend to arrest or diminish the direct force of the inflammation, those which tend to prevent its indirect effects, and those which possess the power of arresting the purulent discharge which follows the acute stage of the disease.

1. *Therapeutic Measures which tend to Arrest or Diminish the Direct Force of an Acute Inflammation of the Middle Ear.*—It does not often happen that we are called to see a case of acute inflammation of the middle ear at such an early stage of its development that we can prevent it from going through all the different stages of an ordinary attack of otitis media purulenta acuta. If a young child, four or five years of age, complains of pain in the ear, the mother is apt to send for a physician without very much delay; and this explains why a majority of the individuals in whom we have the satisfaction of seeing the inflammation subside, under the employment of suitable remedial measures, without going on beyond the first stage, are children of about this age. The practical question which naturally suggests itself in this connection is this: by what evidences or symptoms are we to know whether we should employ the milder abortive methods of treatment, or whether we should, without further loss of time, proceed to more heroic measures?

Or, to put the question somewhat differently, Up to what time, judging from the evidences obtained by direct inspection and from the patient's own sensations, can we safely and properly postpone the operation of establishing a vent in the membrana tympani? As paracentesis is performed almost solely for the purpose of relieving the great pressure exerted upon the membrana tympani and the mucous membrane of the middle ear by the fluid exudation that is being poured into that cavity, we may answer the question by stating that so long as the drum-membrane, and particularly its posterior half, does not display what is termed a "bulging" condition, we may safely persist in our efforts to arrest the inflammation by means of the various anti-phlogistic measures which I am about to describe. The only limitation that I would place upon this rule is this: if, by reason of the swelling of the adjacent parts, we are unable to decide positively whether bulging of the membrane exists or not, we should establish the opening and thus give the patient the benefit of the doubt.

In the early stage of the inflammation, while there is simply redness and swelling (infiltration) of the tissues, I know of nothing more potent to quiet the pain and check the further progress of the inflammation than *hot water*, if kept in contact with the drum-membrane for a certain length of time. In children over four years of age a fountain or gravity douche armed with the pronged nozzle, described on p. 24, can be used very readily. By keeping the reservoir only slightly raised above the level of the patient's ear, and by renewing its contents from time to time, we can keep a steady but gentle current of hot water flowing over the outer surface of the drum-membrane. As a rule this continuous poulticing of the deeper parts of the ear affords the patient marked and prompt relief. In a few cases, however, some form of dry heat—*e.g.*, flannel pillows or bags containing hot bran, hot salt, or hot sand—seems to afford greater relief than does the douche. In this connection I should state that much of the ill-success experienced by physicians in the employment of the hot douche is due to the imperfect manner in which the operation is performed. It is almost useless to give the patient's mother or friend an order on some apothecary or instrument-maker for the requisite apparatus, and then to accompany this order with a verbal explanation of the way in which the instrument should be used. Under such circumstances there are very few chances that the apparatus will be managed in such a way that the current of water will ever go beyond the cartilaginous portion of the meatus. The physician should personally superintend the carrying out of this procedure when it is done for the first time, and he should satisfy himself that the person to whom it is entrusted is competent to perform the task efficiently. In favorable cases re-



lief from pain may be obtained in the course of fifteen or twenty minutes, or even sooner. As soon as relief has been obtained, the douche should be withdrawn, and warm applications (dry or moist, according to the patient's preferences) should be made to the outside of the ear. If the pain returns, the use of the douche should be resumed. If, after a fair trial—say for a period of fifteen or twenty minutes—no appreciable relief is obtained by the employment of the douche, it is better to abandon it altogether. There is one precaution which it is necessary to observe in employing a gravity douche or a bulb-syringe like the "Davidson's syringe." I refer to the necessity of warning the patient or the attendants to abandon the procedure if it be found that it induces dizziness, faintness or nausea. The existence of an acute inflammation of the middle ear seems ordinarily to confer upon the patient an immunity from these unpleasant symptoms, which, in a person with healthy or only slightly inflamed middle ears, are sure to follow more or less promptly the continued flow of a stream of hot water over the drum-membrane. Apparently, young children possess this immunity to a greater degree than do adults. Among the latter, however, it will be found that not a few individuals are soon rendered faint and nauseated by the hot douching, and in these cases it is better to employ the procedure next to be described.

Another, fully as effective, but far simpler plan of poulticing the drum-membrane, is to pour water of a temperature of about 100° F. into the external auditory canal. For this purpose an ordinary teaspoon, or better yet, a glass dropper, may be employed. The water must be poured into the ear, as a matter of course, while the patient is lying upon the opposite side, with the affected ear turned upward. A large vessel containing hot water should be near at hand, so that hot wet cloths (a flaxseed meal poultice will answer even better) may be quickly laid over the ear before the water in the meatus shall have had time to cool. As an additional means of retaining the heat as long as possible, dry flannel cloths (heated, if possible) may be laid upon the moist ones. In the course of a few minutes, the cloths are to be removed, the water is to be allowed to escape from the ear, and a fresh supply is to be introduced in the same manner as at first. As already stated, I have found this very simple procedure fully as effective as the more complicated plan of keeping the drum-membrane constantly bathed by a running stream of hot water.

*Local Bloodletting*, by means of leeches applied near the orifice of the external auditory canal, or in the angle just behind the auricle, stands perhaps next in order as a means of alleviating the pain and checking the inflammation. In children it is better to

abstain wholly from the use of leeches in combating an acute attack of inflammation of the middle ear. Even in adults I am much less disposed than formerly to place faith in their power to prevent such an inflammation, that is still in its first stage, from going on through all its stages. In a later stage of the disease, after a purulent discharge has set in, leeches will often produce effects which every other therapeutic measure has failed to accomplish. Farther on, we will refer to this matter again. So far as the number of leeches to be employed is concerned, I may say that in a fairly strong and healthy adult it is of very little use to apply less than four; in youthful or not very strong individuals, two will probably suffice. If there are no conditions which contraindicate such a course, it is a good plan to allow the after-bleeding to continue for at least half an hour. In the place of leeches we may employ, with equally good effect and with greater safety and comfort, the Heurteloup artificial leech, or the recently contrived apparatus of Dr. Gorham Bacon, of this city (see Figs. 59 and 60). This very simple contrivance answers the desired purpose admirably, and the good results obtained from its use by my associate, Dr. Huntington Richards, justify

me in recommending it unreservedly. The advantages of the procedure over the plan of abstracting blood by natural leeches, are these: the necessary instruments are already at hand, while leeches are not always easily obtainable; there is nothing repelling about the operation, whereas many patients have a decided objection to the employment of living leeches upon themselves; there is no after-bleeding when the artificial leech is used, while the bleeding from leech bites is sometimes very difficult to control; and, finally, much less time is consumed in the management of the whole business than is the case when natural leeches are used. As the apparatus for making the incisions is somewhat expensive and easily liable to become rusted, a few pricks from a sharp-pointed scalpel will be found to answer



FIG. 60.—Wet Cup, for use in ear cases.

15

FIG. 59.—Scarificator, for use in applying Wet Cup to region of the Ear.  
(After Bacon.)



the desired purpose,—I cannot say equally well, so far as pain is concerned, but with equal efficiency, so far as the abstraction of blood is concerned. The withdrawal of from two to four drachms of blood, preferably from the area of skin lying immediately in front of (and close to) the tragus, will exert a decided controlling effect upon the majority of cases of acute purulent inflammation of the middle ear. Some authorities recommend the employment of ice, in the form of an ice-bag, which is to be applied to the outside of the ear. As I have had no personal experience with this method of controlling an inflammation of the middle ear, I may be permitted to pass on at once to the consideration of other matters.

An acute inflammation of the middle ear is almost invariably aggravated by physical exercise on the part of the patient. *Rest*, or the avoidance of physical exercise, is therefore a very important agent in diminishing the virulence of this disease. A man in active business does not like to remain quietly at home because his ear is somewhat painful, and the physician often finds difficulty in convincing him that by pursuing such a course he will in the end economize time. Again, at a later period, after the acute symptoms of the disease have apparently subsided, patients are apt to resume business too soon, and in this way they may bring on a relapse which may prove even more serious than the original attack. Young children, during the onset of the disease, show very little disposition to play or to take any form of exercise. At a later stage, however, the precautions referred to above are very necessary. The moment the child is relieved from pain and has had the requisite amount of sleep, the desire to resume play manifests itself in an unmistakable manner. Restraint should be exercised under these circumstances, and the child should be allowed to regain its full measure of freedom in this respect only gradually. I am disposed to attach a great deal of importance to this matter of rest in the treatment of acute affections of the middle ear. I do not mean by this that I consider it necessary for the patient to go to bed and remain there until every trace of the inflammation has subsided, although in certain cases this will be found to be the better course to pursue; but simply that he should not walk about to any extent, that he should not go up and down stairs, that he should not ride in a carriage or omnibus over our rough city pavements, that he should not transact any business that is calculated to engross his attention very seriously, and so on. All these things excite the heart's action or cause a jarring of the inflamed and sensitive mucous membrane of the middle ear, and, if they are persisted in, renewed inflammation is likely to be the result. Some of the worst cases of inflammation of the ear that I have seen, clearly owed their protracted and vio-

lent course to the patient's disregard of this well-established principle in the treatment of inflammatory affections.

Stress has been laid by some authorities on the value of *position* as a means of diminishing the severity of an acute inflammation of the ear. I have never made a serious effort to ascertain whether or not some one position of the body favored the subsidence of the inflammation sufficiently for us to utilize this knowledge in our treatment of this class of cases. Patients very soon discover for themselves what is the position of body in which they experience the least pain, and they naturally select that position by preference.

The diet during the acute stage should of course be of a non-stimulating character. This is a matter, however, which generally regulates itself, as the patient is not apt to have sufficient appetite for any but the lightest kind of food.

*Therapeutic Measures which tend to Prevent the Indirect Effects of an Acute Inflammation of the Middle Ear.*—In the preceding section I have enumerated the various measures that may be employed to arrest or diminish the direct force of an acute inflammation of the middle ear. These are the measures which we shall probably find it advisable to use when we are first called to see the patient, unless we find that the disease has already gone beyond what might properly be called the first stage. If we bear in mind what is the direct purpose of these different measures,—I refer more particularly to the employment of the hot douche and local bloodletting, and to the abstinence from physical exercise,—we shall appreciate at once the fact that they may come into requisition, not simply during the first stage of the disease, but at other times during its course. During the first stage, however, our entire reliance is placed upon these measures, and if they fail to arrest the progress of the inflammation, there will come a time when other measures will be found necessary—measures which have for their chief object the relief of the pressure and tension caused by the fluid exudation that is being poured out into the cavities of the middle ear, and also to a less extent into adjacent soft parts. We will suppose, then, that in a given case we have tried one or more of the methods of treatment recommended in the preceding section, and have failed to relieve the pain or to arrest the disease. What is to be done next? The proper course to pursue is generally indicated in a very clear manner. The inflammation in its further progress has by this time either caused the drum-membrane (the only part of the middle ear that we can see) to swell greatly, through infiltration of its tissues, or to bulge outward through the pressure of the free inflammatory exudation contained in the tympanic cavity. In either case an incision through the drum-membrane is what is

most urgently needed. The longer the pressure is allowed to continue, the greater is the likelihood that the patient will experience some of the sequels which may be described roughly under the titles of mastoid disease, inflammation of the brain, and chronic discharge from the ear. The incision should be made in the posterior half of the membrane, and its character should depend upon the condition of the parts. For instance, if the membrane is simply bulging and there is not much infiltration of the tissues, a linear incision will suffice. In unruly young children, we are often compelled, unless an anæsthetic has first been administered, to be satisfied with a mere stab of the membrane. Such a stab, however, if made with a properly constructed paracentesis-needle (see Fig. 58), usually suffices. In adults, a longer incision (say four millimetres in length) is desirable. It should be made deliberately, and an anæsthetic should be administered or not, according to the patient's ability to bear the pain without flinching. If both the drum-membrane and the adjacent soft parts in the meatus are, so to speak, fused into an unrecognizable swollen mass, or if good evidence exists that the inflammation has already spread to the adjacent parts, a single linear incision can scarcely be trusted to afford adequate relief. It is better to convert the linear into a crucial or T-shaped incision. My plan is to introduce the point of the needle as high up as I dare in the swollen tissues of what I deem to be the posterior half of the drum-membrane, to cut downward a distance (roughly estimated) of about four millimetres, then to turn the blade of the needle and carry the incision directly backward until I meet with bony resistance.

In speaking of paracentesis of the drum-membrane, under the head of mucous or serous accumulations in the tympanic cavity, I said that I rarely found it necessary to employ an anæsthetic, the pain of the operation being quite bearable. In the case of an acute inflammation of the middle ear the parts are much more sensitive, and paracentesis under these circumstances is decidedly painful. I am therefore often obliged to employ an anæsthetic; certainly not in the majority of cases, but yet in a very respectable minority of them. When the severity of the inflammation seems to demand a crucial rather than a linear incision, I urge the patient to take an anæsthetic. As it is important to use the knife deliberately and cautiously, when we are compelled to operate without the aid of the usual landmarks (short process and handle of hammer, and outlines of the periphery of the membrane), it is far better to wait until the patient is perfectly unconscious, so that we may have simply the unavoidable difficulties of the operation to contend with. The dangers that beset the operation have already been referred to in part. One point of importance, however, still remains to be mentioned. I refer to

those instances in which the paracentesis affords only a brief respite from pain, and is then soon followed by pain even greater than that which existed just before the membrane was incised. If such a case be kept under close observation it will soon (within forty-eight hours from the time of the operation) be discovered that a considerable mass of tough fibrinous material is working its way through the opening in the membrane. Sometimes a little pulling with the forceps will hasten the delivery of the obstructing mass. The explanation of this phenomenon is probably this: Hæmorrhage from blood-vessels (probably on the promontory) divided by the paracentesis needle doubtless results in the formation of a clot which is sufficiently large to block more or less completely the artificial outlet for pus. Such clots soon break down and are discharged, but in the meantime the patient's sufferings are rather aggravated than relieved by the operation. I am therefore disposed at the present time to lay stress on the importance of incising the drum-membrane in such a manner that the engorged vessels of the promontory shall not be incised at the same time.

Immediately after the operation I am in the habit of filling the auditory canal with as hot water as the patient can readily bear, and then of applying externally a large sponge or several thicknesses of flannel cloth wrung out of hot water. The heat and moisture relieve the pain caused by the incision and favor the establishment of a discharge from the inflamed tissues. At intervals of five or ten minutes these hot applications should be renewed, as they retain their heat for only a short time. As soon as the pain has been relieved, all active therapeutic interference should cease until a free discharge has set in. Then the ear should be douched or syringed gently two or three times a day, for the purpose of removing the pus from the auditory canal before it has time to become foul. In cases that run a favorable course, if the discharge is steadily diminishing in quantity, the ear need not be douched or syringed so frequently. It is particularly during this stage of recovery from an acute attack of otitis media purulenta that intelligent and faithfully carried out douching or syringing contributes so largely toward a speedy healing of the perforated drum-membrane. In young children this simple operation of keeping the ear clean will, in the great majority of cases, be found sufficient, treatment with drugs being required in only a few instances.

*Therapeutic Measures which possess the Power of arresting the Discharge which follows the Acute Stage of a Purulent Inflammation of the Middle Ear.*—In a large proportion of the cases the discharge from the ear, which sets in after the acute stage of the inflammation has subsided, disappears so rapidly that the

methods referred to under this third heading are not called into requisition. In a certain proportion of the cases the discharge continues for a longer period than is perhaps generally observed under similar circumstances. If I were asked to state what should be considered as the normal duration of the discharge in these cases of acute otitis media purulenta, I should say one week for the milder cases, and two or three weeks for the more severe ones. By this I mean that the physician is perfectly justified in not adopting direct measures for the arrest of the discharge until it has run on unchecked for a week in the milder cases, and for two or three weeks in the more severe ones. While the selection of the time when it is proper to interfere actively in the treatment of this stage of the disease is a more or less arbitrary affair, there are nevertheless a few points which serve as aids to us in reaching a decision. In the first place, the patient, or the patient's parents, may express the desire to have the discharge arrested as soon as possible. Our course, under these circumstances, is very clear. We should proceed at once to adopt such measures as will accomplish the result desired. There is one rule, however, that comes into play in this connection, and it is a rule that cannot safely be disregarded: *never make any attempt to arrest or diminish the discharge so long as pain persists*. I usually employ nothing but the warm douche or syringing with warm water until a full week has elapsed from the time when the patient last experienced pain in the ear. If at that time the discharge is steadily diminishing in quantity, I prefer—unless urged by the patient to adopt more active measures—to trust a little longer to the simple plan of cleansing the ear. If nature is working out a cure in a reasonably rapid manner, why should the physician interfere? After a second week has elapsed, however, and the discharge is still more or less active, I feel no hesitation in advising the adoption of measures calculated to arrest the discharge.

If we wish to treat successfully a case of otorrhœa or discharge from the ear, we must picture to ourselves clearly the precise locality from which the discharge comes. In the disease which we are now considering, the discharge is supplied chiefly by the mucous membrane lining the tympanic cavity, and to a less extent by that lining the mastoid antrum and adjacent air-containing cells. This mucous membrane is diseased, and to restore it to a healthy condition we must bring our remedies in direct contact with it. This is the problem which we, as physicians, are called upon to solve. If a large perforation has formed in the drum-membrane, the problem is comparatively easy of solution. As a rule, however, the perforation is quite small, sometimes even invisible. How, then, are we, under these circumstances, to bring our remedies in contact with the tympanic mucous membrane?

As there are but two routes by which the tympanic cavity can be reached, we must select one or the other of these. That by way of the Eustachian tube is encompassed with various difficulties;—that is, if we attempt to use it for the purpose of bringing fluids in contact with the tympanic mucous membrane. That by way of the perforation in the drum-membrane is therefore practically the only route that we can follow. Having chosen our route, let us next consider the practical details of the operation of bringing our remedial solutions in contact with the diseased tympanic mucous membrane. In the first place, we may assume that the cavity of the tympanum is filled with fluid exudation. Our first step should therefore be to remove this secretion as thoroughly as we can. If the perforation is sufficiently large we can wipe out some of the fluid by means of the cotton-holder<sup>1</sup> armed with absorbent cotton. Inflations by means of Politzer's method will also aid materially in freeing the tympanic cavity from any secretion that it may contain. In the natural order of things, however, the inflations should precede the use of the cotton-holder. In the majority of cases the cleansing that is effected by one or both of these methods will be found sufficiently thorough for our purposes. A more perfect method will be described farther on. If the perforation be very small, we may find it desirable or even necessary to enlarge it with the paracentesis-needle. This enlarging of the perforation is specially indicated in cases in which the discharge is mucoid in character; for in these cases the secretion cannot be forced through a small perforation, unless a greater degree of force be used than is proper. After we have removed as much fluid as we can from the middle ear, our next step should be to introduce our remedial solution as thoroughly as possible into this same cavity. A simple and fairly effective way of accomplishing this is the following: the patient should hold his head in such a position that the affected ear will be turned upward. The remedial solution should then be dropped into the auditory canal until it covers the drum-membrane to a depth of at least five or six millimetres. In order to force a part of this solution through the perforation, pressure must be exerted from without upon the mass of fluid as a whole. This can be done in two ways. With one hand the physician should pull the auricle outward (*i. e.*, away from the head), with the forefinger of the other hand he should press the tragus backward in the same manner as he would shut the lid of a box, and then, relaxing his hold on the auricle, he should press the tragus firmly inward toward the drum-membrane. In this way quite a strong pressure can be brought to bear upon the fluid that lies upon the outer side of the drum-membrane. It is well, however,

---

<sup>1</sup> The smallest size of instrument should be used for this purpose.



not to trust to this pressure alone, but to take advantage of the aid which the patient (if an adult) is able to afford by performing the act of swallowing (with or without simultaneous closure of the nasal orifices). When I resort to this method of forcing fluid into the middle ear, I make it a rule to lessen the pressure the

moment the patient experiences either pain or dizziness.

I also cease to make pressure as soon as the patient notices that some of the solution has reached the naso-pharyngeal space. A Politzer's rubber bag, armed with a nozzle that will fit the orifice of the external auditory canal in an air-tight manner, affords another means of condensing the air in the meatus, and of forcing the remedial solution into the middle ear. After I have succeeded, by one of these two methods, in introducing the remedy into the tympanum, I usually allow it to remain there undisturbed for two or three minutes, and then I have recourse to Politzer's method of inflating the middle ear for the purpose of dislodging the solution from that cavity. I am now disposed to believe that when quite weak solutions are used, it would be better not to attempt to dislodge the remedy, but to leave it undisturbed in the tympanum.

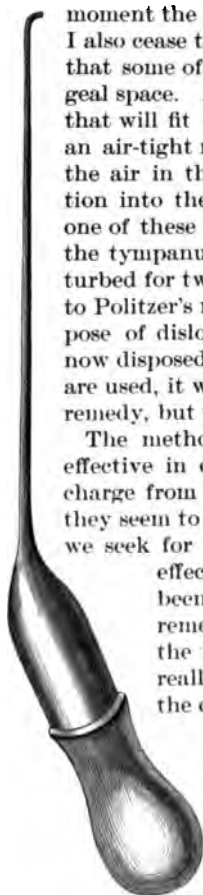
The methods which I have just described are fairly effective in diminishing and eventually arresting a discharge from the middle ear. In not a few cases, however, they seem to exert but very slight curative effects; and if we seek for the reasons why they fail to produce these effects, we find either that the middle ear has not been adequately cleansed, thus preventing the remedial solution from coming in contact with the mucous membrane, or that the solution has really never passed through the perforation into the cavity of the tympanum.

A much more satisfactory plan of treating these cases is that by means of the middle-ear pipette (see Fig. 61). This method, which in skilled hands is simply invaluable, often arresting the discharge as it were by a single stroke, is unfortunately beyond the reach of the average practitioner. It is only after a man has acquired delicacy and precision in his manipulations, skill in the

FIG. 61.—Middle Ear Pipette. Actual size.

management of the forehead-mirror, and thorough familiarity with the region of the middle ear, that he may safely undertake to treat a case by aid of the middle-ear pipette (no matter of what material, platinum or glass, the instrument be constructed).

These pipettes are made from glass tubing, five-sixteenths of an



inch in diameter, and with rather thick walls. As these pipettes are not so very difficult to make, I will describe briefly the steps of the procedure. Take a piece of glass tubing, about eight inches in length, hold the ends lightly with the fingers of both hands, and rotate it slowly around its long axis over the blue flame of a Bunsen burner. As soon as the central portion of this bit of tubing has become sufficiently soft,—not at one small spot merely, but over a section of the tube say from half to three-fourths of an inch in length,—draw it out into a slender tube about ten inches long. As the pipette when completed should measure not less than three inches in length in its slender portion, the next step should be to file a shallow circular notch around the tube, at a point about three inches distant from the shoulder—if I may so designate the spot where the broad part of the tube begins to grow narrower—and then break the tube at this spot. As it is desirable to have the tip of the pipette slightly bent, we should next heat it very cautiously until it bends over, from its own weight, in the direction that we desire it to follow. If the tip beyond the final bend is too long, or if the heat has caused the orifice of the narrow canal to become closed, a circular notch should be filed in the tip, at a distance of not more than two millimetres from the bend. To render this fractured end sufficiently smooth, it may either be brought near enough to the Bunsen flame to fuse the sharp edges, or these may be ground smooth by a suitable file or stone. The broad portion of the tube, if too long, should be filed and broken off at a distance of from an inch and a half to two inches from the point where it begins to grow narrower. Before doing this, however, the physician should heat the tube at this shoulder and bend it at an angle of about 120 degrees. The rubber caps attached to the glass droppers usually sold by the apothecaries may be fitted in a similar manner to these pipettes, and will be found to answer well the purposes for which they are intended.

In practice it will be found necessary to have right and left pipettes, as one adapted for the introduction of fluids into the right mastoid antrum cannot be used for this purpose in the left ear. A third pipette, with the tip bent directly downward (when the instrument is held with its rubber cap pointing downward), will also be found useful in those cases in which the perforation occupies the anterior inferior quadrant of the drum-membrane.<sup>1</sup>

It is scarcely necessary to discuss here at length the question whether the curved or the straight tips are the better adapted for general use. My own preference is for the former. With the straight tip one is apt either to push it in too far, or to unintention-

<sup>1</sup> To obviate the necessity of going into these details a second time, I can scarcely avoid alluding here to forms of ear disease which do not belong in this section.

tionally draw it out of the tympanic cavity altogether, in both of which cases no fluid from the pipette will reach the middle ear. On the other hand, with the curved tip, it is possible to push it firmly against the mucous membrane of the promontory without thereby closing the aperture; and if we draw the tip too far outward, the resistance offered by the membrana tympani gives us timely warning of what we are doing. Furthermore, the curved tip enables us to direct the current of the escaping fluid toward or into the mastoid antrum. For all these reasons I consider the curved tip decidedly preferable to the straight one.

As glass pipettes may easily be broken, it is urged by some that these instruments should be constructed of platinum. Those who are unable to make their own pipettes, or who are not within easy reach of an instrument-maker, cannot probably do better than to follow this recommendation. In the course of several years I have broken perhaps half a dozen pipettes, at a total cost of only a few cents. A good set of platinum pipettes, similar in all respects to the glass ones which I have described, can scarcely be purchased for less than ten or fifteen dollars. To very many men this expensiveness of the platinum instruments would prove a serious objection to their use. I am therefore disposed to plead strongly in favor of the glass instruments. One writer has said that: "In order to be available, such an instrument [referring to the glass pipette] must be so very delicately constructed that even in skilled hands it would not be entirely free from danger; for having been passed through the perforation in the membrana tympani, the patient, in an unguarded moment, might suddenly draw his head away from the operator, and the delicate hook-shaped extremity break off, fall into the middle ear, and its removal would certainly not be unattended with difficulty."<sup>1</sup> The objection raised by Dr. Andrews may be applied with almost equal force to any instrumental manipulations about the drum-membrane or adjacent parts. The fact is, only those who are provided with "skilled hands" have any right to operate upon a drum-membrane or middle ear that is not acutely inflamed.<sup>2</sup> In the hands of such persons I consider the glass pipette as a reasonably safe instrument. I have used it a great many times, in young children as well as in adults, and yet I have never met with the accident to which Dr. Andrews refers. Whenever I have broken a pipette it has been through carelessness in transporting it from one place to another, but never during any manipulations about the ear.

With regard to the mode of using this instrument in the class

<sup>1</sup> J. A. Andrews, M. D., Archives of Medicine, April, 1890, New York.

<sup>2</sup> In cases of acute inflammation of the middle ear, the circumstances may be such that operative interference on the part of a person whose hands are not skilled may be perfectly proper.

of cases now under consideration, very little need be said. If the discharge is not mucoid in character, the preliminary cleansing described above will usually be found sufficient. The curved end of the pipette is then to be introduced into the perforation, and the remedial solution is to be injected into the tympanic cavity. These injections should be repeated on alternate days, or three times a week; and if, after the third or fourth injection, little or no improvement is perceptible, we may safely assume that our treatment is defective in respect to the preliminary cleansing. The proper course is then to wash out the middle ear in one of the two ways presently to be described. If our object is to only partially wash out the middle ear, the simplest plan is to draw the pipette full of water at a temperature of from 100° to 105° F., and then, after introducing the curved tip through the perforation, to throw the entire contents steadily but not too slowly into the tympanum, and preferably in the direction of the antrum. I usually repeat the operation a second or perhaps even a third time, always taking the precaution each time to mop up the fluid that has been driven out into the meatus. If a more thorough cleansing of the middle ear is thought desirable, the best plan is to attach the pipette to the rubber tubing of a Clark's or fountain douche, filled with water at a temperature of from 105° to 110° F. As the water cools rapidly in its passage from the reservoir to the pipette, it is important not to introduce the instrument into the middle ear until the water has been allowed to run for a few moments from the curved tip. Then, compressing the rubber tube with the thumb and forefinger, close to the point where it is attached to the pipette, we should introduce the tip into the middle ear, and then, when everything is ready, allow the water to flow through the pipette by relaxing our pressure upon the rubber tube. A sponge held beneath the ear will catch all the fluid that escapes from the meatus. As soon as the water begins to flow out through the perforation, the exact position of the pipette can no longer be judged by actual inspection. It is therefore a matter of great importance that we should hold the instrument very steadily during the flow of water into the middle ear; for if we fail to take this precaution, we shall run a great risk of injuring the structures of the middle ear, or shall fail utterly to wash out that cavity. Just before the water is allowed to flow through the pipette we may gain some assistance in holding the instrument steadily in its proper position by grasping the slender portion with the thumb and forefinger of the left hand, the remaining fingers of which find a firm resting-place against the patient's cheek or mastoid process. With regard to the quantity of water that should be allowed to flow through the middle ear, I can only assign an arbitrary limit, say from half an ounce to an ounce.

At the same time I should not hesitate to use three or four times that quantity if I had any reason for believing that the smaller amount had failed to dislodge the mucus.

When it seems desirable to wash out the middle ear in a more thorough manner than can be done with the pipette when simply armed with the rubber cap, I believe that Blake's middle-ear syringe (see Fig. 62) will be found to answer this purpose fairly well.

The great objection to the employment of a syringe for delicate work of this kind is the difficulty which one experiences in holding the nozzle steadily at one small spot while simultaneously pushing in the piston with the thumb of the same hand. On the other hand, this syringe possesses, at least for cleansing purposes, the following decided advantages over the douche and pipette: it is much less cumbersome, and it can deliver a stream of greater strength.

After the middle ear has been washed out sufficiently, it is desirable to get rid of as much of the water that remains behind as we can. If we allow the water to remain, it will dilute to an unknown degree the remedial solution employed, and thus perhaps prevent the effect desired. The better way is to resort to inflations immediately after the cleansing process, and thus remove at least the greater part of whatever fluid may be in the tympanum.

Of the different local remedies that may be used in the treatment of a non-chronic purulent discharge from the middle ear, I employ only nitrate of silver, in the form of solutions of different strengths. In the great majority of cases it is not necessary to employ a stronger solution than one containing two grains to the ounce of water. If the perforation is comparatively large, say about two millimetres in diameter, we may—if the weaker solutions fail to produce the desired effect—employ a solution of almost any strength. It has been my



FIG. 62.—Blake's Middle-ear Syringe.

experience, however, that it is rarely advantageous to employ a stronger solution than one of five grains to the ounce, and in the great majority of instances I find that a two-grain solution accomplishes all that can be desired.<sup>1</sup> I scarcely ever introduce the remedial solution into the tympanum in any other way than by means of the slender glass pipette, and it is to this more perfect method of bringing the remedy in contact with the diseased tympanic mucous membrane that I attribute the successful results which I have obtained with this weak solution.

It may seem strange to some who read this section that I should recommend solutions of only one drug, viz., nitrate of silver. I do it, however, advisedly, for I have wasted a great deal of time in trying various remedies,—all of them highly recommended; but I have found them one and all so far inferior to nitrate of silver that I feel no hesitation in passing them all over in silence.

I have never been in the habit of warming the solution before introducing it into the middle ear. If the perforation is of ample size, I fill the pipette as full as I can and discharge its entire contents; if the perforation is quite small, I suck up into the instrument only enough to fill the slender portion of the tube, say one or two minims. If we use only the smaller quantity of fluid, it will not be necessary to pay attention to the position in which we hold the pipette; but if we have drawn up into it all the fluid that its limited suction-power can raise, we must keep the slender arm of the pipette pointing somewhat downward during the act of introducing it, or the fluid will soon run back into the rubber cap, and we shall simply drive out air into the middle ear, and thus fail in the accomplishment of our purpose. After the remedial solution has once been introduced into the middle ear, I usually allow it to remain there undisturbed, and I pay no further attention to it. Applications of this character can be made to the middle ear as often as three times a week.

Unless the perforation is quite large, it is practically useless to recommend the patient to employ some remedial solution at home. If for any reason, however, it seems desirable to do so, a three-grain solution of sulphate of zinc or a two-grain solution of acetate of lead, may be prescribed. The solutions of nitrate of silver can scarcely be employed by the patient himself,—or by the mother in the case of a child,—for without a certain degree of familiarity with the handling of these solutions, almost anybody would be quite certain to stain either his person or his garments.

The more rebellious cases of otitis media purulenta acuta merit the title of otitis media purulenta chronica, and it is to that chapter that I would refer the reader who desires to learn further details with regard to the management of this class of cases.

<sup>1</sup> On two or three occasions I have injected a saturated solution (490 grains to the ounce of water) of the drug, without any unpleasant after-effects.

If the perforation is large enough to admit of such a procedure, powdered remedies (alum, iodoform, boracic acid) may sometimes be used to advantage in checking the discharge from the middle ear. My mode of using them is the following: the tympanic cavity having been freed as far as possible from the secretions which it may contain, I moisten the tip of the slender middle-ear probe, dip it into the powder, and then cautiously introduce it, with the mass of powder clinging to it, into the opening in the drum-membrane. In the case of a small opening I generally find it necessary afterward to push in, one after another, the portions of powder that remain sticking to the edges of the perforation. Sometimes a single such charge of iodoform or of burned alum suffices to arrest the discharge permanently; at other times, repeated applications will be found necessary. So far as the quantity is concerned, I am not aware that it is important to employ any particular amount of either of the three remedies mentioned above. In the case of powdered burned alum, a mass equal in size to a No. 12 shot (or a sphere about one millimetre in diameter) will often suffice for a single charge. I frequently, however, use three or four times this amount, especially if the perforation be one of good size. I have never experienced any unpleasant effects from using powdered burned alum in this manner. In former years I was in the habit (in chronic cases, with extensive destruction of the drum-membrane) of blowing comparatively large quantities of powdered alum indiscriminately into the exposed cavity of the middle ear, and I occasionally experienced unpleasant effects. This mode of procedure, however, is very different from the one recommended above. In the scale of efficiency I should place powdered iodoform very nearly if not quite on a par with powdered burned alum; in the scale of safeness I should place both it and boracic acid ahead of the alum. The penetrating odor of the iodoform is sometimes so disagreeable to the patient, or to the patient's friends, that the physician is obliged to abstain from its further use. Apart from this it is a most valuable remedy. It is claimed that powdered iodol, which has very little odor, and that not unpleasant, possesses the same virtues as iodoform. I have used it occasionally for several months past, but I have not yet been able to satisfy myself how efficient it is in comparison with iodoform. It is apparently non-irritating in character, but I have a suspicion that it is less inimical to micro-organisms than is iodoform, and consequently must be less efficient than the latter.

Boric or boracic acid, which is now obtainable in the shops in the form of a finely divided powder, seems to exert a soothing effect upon the inflamed mucous membrane of the middle ear when dusted over it. This effect, however, is apparently short-

lived, and I have accordingly long since abandoned its use. In chronic cases, with extensive destruction of the membrana tympani, boric acid may perhaps still be used with advantage. This question, however, will be discussed briefly in its proper place, in the next chapter.

*Acute Inflammation of the Posterior Fold of the Drum-membrane.*—The etiology of this form of ear disease has already been discussed in the chapter on General Etiology. It is of rare occurrence—I have seen in all not over half a dozen cases—and is characterized, in the majority of instances, by the great severity of the accompanying pain. I will give here brief accounts of the two first cases seen by me:—

The patient, a policeman, consulted me on the 10th of March, 1874, for a very distressing tinnitus in both ears. He had experienced no pain in them, and his hearing, so far as he was aware, was perfect. The tinnitus had made its appearance about two months previously. I tested his hearing with my watch and found it to be: R.  $\frac{1}{4}$ ; L.  $\frac{1}{4}$ . Both drum-membranes presented a dull and opaque appearance, and were slightly sunken. On the left side there was moderate congestion of the posterior fold (the parts above and behind the short process of the hammer). My diagnosis was, catarrhal inflammation of both middle ears, and I began treating the patient in accordance with that diagnosis.

On the 14th of March, finding that the redness of the posterior fold still persisted, I painted the parts with a strong solution of nitrate of silver (gr. 120 to the ounce). I interpreted this redness as an evidence of a still more active congestion of the neighboring mucous membrane, and employed the solution of silver simply for the purpose of producing a derivative effect.

On the 16th the patient reported that the tinnitus in the left ear had materially increased: there was, as he described it, a constant ringing of bells in his ear. His face presented the aspect of one who was in suffering, but yet he described the pain in his ear as being only trifling. H.D.W.—L.  $\frac{1}{4}$ . On inspection I found that the skin immediately above the posterior half of the drum-membrane was red, tense, and glistening. Through the upper and posterior portion of the membrana tympani, which was still translucent, a yellowish area was visible. It conveyed to my eye the appearance as if a yellowish body projected downward from the inner side of the axis-band of the hammer. Suspecting the existence of an accumulation of pus, I incised the inflamed and swollen posterior fold, and afforded escape to a drop of thick, creamy pus. A second incision into the anterior fold, which was also quite red, gave escape only to blood. (The patient bore both of these cuts without flinching.) Inflation by Politzer's method failed to exert the slightest appreciable influence upon the contents of the abscess. After the immediate pain of the incisions had subsided, the patient expressed himself as feeling greatly relieved in the condition of his head.

On the 18th of March the patient reported that he was feeling better, and that no discharge had yet made its appearance; and on inspection I found that no evidence existed of there having been any discharge since the day of the operation.

On the 23d of March only a slight singing noise remained in



the left ear. (The subsequent history of the case is of no further interest in its bearings upon the subject of the present section.)

The second case was seen about two years later. The history, in brief, is as follows:

The patient, a lady, about thirty years of age and in good health, began to suffer from pain in her right ear on April 18, 1876. Her physician examined the ear, and finding it filled with a plug of cerumen, he removed it by syringing. During the following three days she continued to suffer from pain in the ear, the pain not being constant, but coming on in paroxysms, with intervals—which sometimes lasted for several hours—of complete freedom from pain. The pain, however, when it came, was of very great severity, especially on the 21st of April, the day on which I saw her. At this time I found the external meatus in a normal condition; the drum-membrane was beginning to be slightly oedematous (like polished steel when breathed upon), but not appreciably reddened; the posterior fold was red and somewhat swollen, especially posteriorly, but without any appreciable pouting, such as might be expected if pus were working its way toward the surface. Hearing distance for watch  $\frac{1}{4}$ . A free incision (about four millimetres in length) made in the posterior fold caused quite a large drop of pure, thick pus to almost gush out through the opening. (The patient was under the influence of an anæsthetic.)

I did not see the case again, but the physician reported that the operation gave complete relief, and that very little, if any, discharge made its appearance afterward.

In the report which I published of these two cases, in the *Transactions of the American Otological Society* for 1877, I made the following remarks: "Every aurist sees a number of cases of otorrhœa in which the only demonstrable lesion of any importance is an ulcerated opening in the posterior half of Shrapnell's membrane, from which a fistulous track leads inward a variable distance, and at the bottom of which the probe usually encounters denuded bone. Sometimes this opening is so extensive that the neck and head of the hammer lie exposed to view. The peculiarity of these cases, however, lies in the fact that the membrana tympani is still entire, and, in many cases, not adherent to the inner wall of the tympanum. Inflation, too, either by Politzer's method or by means of the catheter, reveals the fact that the cavity of the tympanum contains no fluid, and has no communication with the fistulous cavity. In other words, the trouble is a chronic caries of a limited region of bone in the immediate vicinity of the middle ear; but it differs from all the most common forms of caries encountered in this region in the fact that the pus and detritus thrown off from the diseased part do not escape by way of the tympanum, but through a sinus which, though appearing to lead directly into the middle ear, has no communication whatever with this cavity. If I am not mistaken, it has been customary to explain these cases on the supposition that originally there was an inflammation of the entire middle ear, with a

perforation in Shrapnell's membrane, but that gradually the inflammatory process became restricted to the tissues occupying the upper and posterior portion of the cavity, the wall of separation formed by the healing process being so perfect as to entirely prevent any of the inflammatory products from entering the middle ear. In a word, these cases have been looked upon as cases of an imperfectly healed purulent inflammation of the middle ear. The two cases I have just reported suggest the idea that the pathology of this class of cases may be a different one; that is, that at the outset the inflammation may have been restricted to the soft parts constituting, and lying near to, the posterior half of Shrapnell's membrane. As the descriptions of these two cases show, such a circumscribed inflammation of Shrapnell's membrane does sometimes occur, and, such being the fact, is it not more natural to explain these cases of fistulous opening in Shrapnell's membrane as *ab initio* cases of circumscribed inflammation? Further observations of such cases will undoubtedly furnish us, in due time, with a satisfactory explanation of their pathology." More than ten years have elapsed since the publication of the words just quoted, and I am now convinced that the view here put forward can scarcely be true of the majority of these cases of chronic fistula of the posterior fold. In part they are to be referred to the destructive effects of tubercular disease of the region involved, and in part they are to be considered simply as perforations which have originated in precisely the same manner as perforations in the drum-membrane proper ordinarily originate—that is, through the effects of pressure. This is the view—as I have stated above—generally accepted, and it seems to me to be, on the whole, the most plausible one.

So far as the *diagnosis* of an abscess in the posterior fold is concerned, the following may be mentioned as the points which will enable us to suspect strongly that pus is developing in this particular locality:

1. The well-marked redness of the parts which lie immediately above the posterior half of the drum-membrane.
2. The absence of any evidence of active inflammation of the middle ear proper.
3. The unusual severity of the pain in the ear.
4. The slight degree of impairment of the hearing.
5. The absence of pain, tenderness, or swelling in the mastoid region, one or all of which symptoms would be present if the redness of the posterior fold were simply an evidence of the more acute inflammation going on in the mastoid antrum.
6. The previous history of the case can alone enable us to differentiate the condition under consideration from that produced by a fracture of the squamous portion of the temporal bone.

The *treatment* has already been sufficiently indicated above.

## CHAPTER X.

### CHRONIC PURULENT INFLAMMATION OF THE MIDDLE EAR.

A CHRONIC purulent inflammation of the middle ear begins almost invariably as an acute inflammation. In tuberculous and syphilitic individuals we may observe an insidious and painless development of the disease in the middle ear, but these cases are comparatively rare. The etiology of chronic purulent inflammation of the middle ear, so far at least as it can be said to have an etiology separate from that of the acute variety, may be summarized in a single sentence: the lack of proper treatment during the acute stage of the inflammation is the cause of the chronic form of the disease in ninety-nine out of a hundred cases. This may seem somewhat exaggerated. Nevertheless, I believe it to be true. There are many cases, I admit, which yield very slowly to even the most skilful treatment, and which perhaps would be described as having merited the title of "chronic;" but the total duration of the affection is even then not likely to exceed a few weeks, whereas a genuine case of chronic otitis media purulenta is one in which the morbid process in the middle ear has been going on for months, if not for years. It is to cases of this kind that I refer when I say that they owe their origin, as a rule, to the lack of proper treatment during the earlier stages of the attack.

*The Course of the Disease.*—A chronic purulent inflammation of the middle ear may run a variety of courses. For years the mucous membrane of the middle ear may secrete a scanty purulent or muco-purulent fluid, and if the patient is careful to cleanse the ear at stated intervals, this persistent but slight otorrhœa may represent the only symptom of which he has any complaint to make. Furthermore, the most careful examination may fail to detect any evidence of the existence of any other pathological condition than that of a slightly swollen and relaxed<sup>1</sup> tympanic mucous membrane; I except, as a matter of course, the loss of drum-membrane substance that took place undoubtedly in the earlier stages of the disease. If this perforation in the membrana tympani is of ample dimensions, it is not likely that the patho-

<sup>1</sup> Not possessing the firm and healthy appearance of the normal mucous membrane.

logical picture which I have described will undergo any material change for the worse.

In another group of cases this placid course of the disease is disturbed by a complication which may lead to a whole train of more or less serious disorders. I refer to the development of granulation-tissue. Two elements co-operate in certain cases to bring into activity this proliferative tendency: first, the acrid and irritating nature of the secretions; and second, the uncleanly habits of the patient, who permits these acrid secretions to lie undisturbed, in a decomposing condition, in contact with the mucous membrane of the middle ear. Sometimes the irritating properties of these secretions are so great that even the skin lining the external auditory canal undergoes ulceration from contact with them. In this second group the discharge is almost always abundant.

Finally, if the conditions just described are not properly treated, or, as is more likely to be the case, if they are allowed to remain wholly untreated, the inflammation of the middle ear begins to encroach upon the neighboring organs, and we then encounter, as results of this extension of the disease, the following catalogue of lesions, which are often fatal: caries or necrosis of the bony walls of the middle ear or of the mastoid cells—the result, very commonly, of retained pus; ulceration of the carotid artery, with fatal hemorrhage; ulceration of the lateral sinus or of the communicating mastoid vein, with phlebitis, pyæmia, and perhaps metastatic abscesses; meningitis, or abscess of the brain; consumption, due to an infection of the system produced by a collection of cheesy pus and debris retained in the middle ear or mastoid antrum; and perhaps still other lesions which do not now occur to my mind.

For purposes of convenience, then, I will treat the subject of the present chapter under three headings, corresponding to the three groups into which I have divided all cases of chronic purulent inflammation of the middle ear. Before considering these groups in detail, however, I will make a few

#### GENERAL REMARKS ON DIAGNOSIS AND PROGNOSIS.

The term "chronic purulent inflammation of the middle ear," as already intimated, covers such a multitude of different conditions and combinations of conditions that, as diagnosticians, we must consider our task as only begun when we ascertain the fact that the case is one of *otitis media purulenta chronica*. It is not sufficient even to determine in a general way that it belongs to one of the three larger classes mentioned above. If we wish to treat the case successfully we must take cognizance of the exact condition of every square millimetre of the surface of the auditory

canal, drum-membrane, tympanic mucous membrane, etc.—so far, at least, as it is possible to reach some of these remoter portions of the ear. As a matter of course there are parts which we cannot see, nor even reach with an instrument. When once, however, the art of exploring the nooks and crannies of the middle ear has been learned, it is surprising how often we are rewarded by discoveries which enable us to arrest the troublesome discharge, and perhaps also to relieve the patient of other distressing symptoms. The art of properly cleaning the ear is the art which I would urge the beginner in otology to cultivate. I am strongly tempted to add that when he has mastered this very difficult art, he will find himself a master both in the diagnosis and in the treatment of diseases of the ear. This is not far from the truth. As an instructor I have repeatedly made the observation that, after the ear had been properly cleansed, even a beginner would often be able to make a correct diagnosis of rather complicated conditions. But very rarely indeed have I known a pupil to be able to clean an ear even fairly well, until he had served a somewhat long apprenticeship. This cleansing process must be done by means of the cotton-holder, the curette, the slender middle-ear probe, and the delicate angular forceps. If the external auditory canal is filled with a very foul pus, it may be pleasanter for the physician to remove as much of it as he can by syringing. If the discharge, however, is not particularly offensive, and if there is no decided accumulation of cheesy material and epithelium, time will be saved by employing, from the very beginning, the cotton-holder armed with absorbent cotton. By varying the amount of cotton used, the physician can make a mop suitable either for the removal of large quantities of pus in the broad external auditory canal, or for the thorough cleansing of a small sinus leading through Shrapnell's membrane into the recesses of the middle ear. If syringing alone is employed, the picture afterward presented to the eye of the observer will almost invariably be a deceptive one. All the depressions and interstices will continue to hold a certain amount of water, and under these circumstances the most experienced observer can scarcely fail to interpret incorrectly what he sees. But oftentimes even the cotton-holder fails to accomplish all that is desired. Masses of cheesy pus or of epithelium remain embedded in the recesses or cling firmly to the tissues, and we are obliged to use the curette, the slender probe, or the forceps. In all these recommendations I assume that I am dealing with physicians who possess a fair degree of steadiness of hand and delicacy of touch. I assume, furthermore, that they have mastered the art of illuminating the deeper parts of the ear with a forehead mirror. To men who are not accustomed to the delicate manipulation of instruments,

this whole chapter must necessarily, in a large measure, prove unprofitable. If cases belonging to the first group come into their hands for treatment, they may, by employing the syringe and by instilling suitable remedial solutions into the ear, occasionally effect a cure; but a large number of perfectly curable cases will experience comparatively little benefit from this—if I may be allowed the expression—"hit or miss" treatment of the disease. It is far better, however, for such men to recognize early their lack of manual dexterity, and to abstain religiously from using instruments of any kind in the ear. They will then be at least sure of doing their patients no harm, and they will, as already stated, occasionally effect a cure by those methods of treatment which necessitate the employment of no other instrument but the syringe.

It is unnecessary to enter here into a minute description of the conditions which call for the use of this or that particular instrument, or to attempt a description of the proper modes of using them. I will simply formulate two general rules, which will be found, I believe, useful. In the first place, when granulation-tissue presents itself to view, it is never safe to assume that the relations are what they seem to be. Thus, for example, I have more than once thought, after thoroughly cleansing an ear, that the picture presented to my eye was one of a granulating and very much hypertrophied mucous membrane of the inner wall of the tympanum, with total destruction of the membrana tympani. By the aid of simple inspection this was as far as I was able to go in my interpretation of the appearances observed. By gently manipulating the parts with the probe or the curette, however, the incorrectness of my interpretation became at once apparent. The "granulating and hypertrophied mucous membrane of the inner wall of the tympanum" was in reality a flattened polypoid growth, lying upon the outer surface of the drum-membrane. Its peduncle, which passed through a large perforation in the posterior superior quadrant of the drum-membrane, sprang from the upper and posterior portion of the tympanic cavity. Long experience and the most careful scrutiny will never enable the physician to dispense with these instrumental manipulations. And it must be remembered that an error in diagnosis, under circumstances such as I have just described, means also an erroneous plan of treatment.

The second rule to which I alluded above, is this: it is a good plan to assume that, in the great majority of cases of long-standing otorrhœa, the discharge is kept up either by a carious process in some portion of the temporal bone, or by the stagnation of pus and epithelial debris in some recess or pocket, or by a mass of granulation-tissue, situated in one of the following three

places: the external auditory canal, the middle ear proper, or the mastoid antrum. If the physician, therefore, expects to relieve his patient of his otorrhœa, he must ascertain, as accurately as possible, where the caries or the granulation-tissue is situated, or at what particular part of the middle ear the stagnation probably exists. It is not sufficient for him to ascertain, in a general way, that the caries or the granulation-tissue is situated in the external auditory canal or in some part of the middle ear; he must ascertain the precise limits of the disease, just as the general surgeon does in a case of caries of the tibia or in one of uterine polypoid growths. He must introduce his slender probe into every recess; he must touch with it every spot of suspicious redness; in a word, he must render to himself a strict account of every portion of the ear within his reach. If the external canal is free from granulation-tissue or from caries, and the pus clearly escapes from the middle ear through a perforation in the membrana tympani, he must pass his cotton-holder (armed with absorbent cotton) through the perforation and soak up the pus or mucus that fills the middle ear and prevents him from seeing the opposite promontory. In this way one can often bring to light a polypoid growth which otherwise would escape observation. But in many cases such a cleansing of the middle ear is not sufficient. The polypus may be so situated that no portion of it can be seen through the perforation. For instance, it may spring from the upper or outer wall, and may hang down on one side or the other of the opening. In addition, therefore, to the cleansing, it is advisable to bend the end of the probe slightly, and then, passing it in through the perforation, to rotate it in such a manner that it will be likely to bring into the field of vision any polypoid growth that may be located in the immediate vicinity. If these manipulations are executed with delicacy,—the surgeon's eye being directed all the time upon the perforation, and account being taken of the exact situation of the (concealed) end of the probe,—the patient will probably not complain of even a sense of discomfort, much less of pain. If, after making a critical search, the physician fails to find either a caries or a region of granulation-tissue, he is still not warranted in drawing the inference that these lesions are absent, that is, that the case belongs to the first of the three groups into which I have divided all cases of otitis media purulenta chronica. He should proceed, however, to treat it as if it really did belong to this group, and upon the success or lack of success of his treatment he should finally base his diagnosis. I do not mean by this that his conclusion will always be in harmony with the facts; but simply that there is a strong probability that such will be the case. In the absence of these lesions, a suitable medication of the middle

ear will soon arrest the discharge; if these lesions, however, are present, the same medication will almost certainly fail to accomplish this result.

So far as the question of *prognosis* is concerned, only a few rules of general applicability can be laid down. In the first place, when a case of chronic purulent inflammation of the middle ear is brought to us for an opinion as to what is likely to be the future course of the disease, we must, in a large proportion of the cases, be guarded in our statements. This is true, in a special degree, with regard to the effects of treatment. Let us consider, first, the question of the *arrest of the discharge*, which is generally the one that most interests the patient. Taking a large number of cases together, we may promise very good results from treatment, but in individual cases we cannot safely predict what will be the results. Oftentimes the cases which seem as if they would be the easiest to manage, and with regard to which we feel disposed to give a very favorable prognosis, prove in the end to be the most stubborn. On the other hand, if the discharge is profuse and offensive, and if there is an abundant development of granulation-tissue, we may safely make the prediction that treatment will effect a very marked improvement in the condition of the ear,—that the discharge will be greatly diminished in quantity, and at the same time be rendered inoffensive. In fact, in quite a large number of cases, the discharge will be arrested permanently, but it is not safe to predict such a result. The prognosis is perhaps better in cases in which the perforation in the drum-membrane is large than in those in which it is small. In the next place, the prognosis is far better in cases in which the perforation involves the membrana tympani proper than in those in which the discharge escapes through an opening in Shrapnell's membrane or in the soft parts in that immediate vicinity.

The next question in prognosis to which we must frequently give an answer, relates to the *recovery of the hearing power* in the ear affected. If masses of granulation-tissue surround, and perhaps even press upon, the stirrup, and if we find that we can remove these masses, we may safely say that a certain degree of improvement in the hearing will be likely to result from treatment. The effects produced by the presence of a purulent or muco-purulent fluid in the middle ear upon the acuteness of the hearing are very nearly the same as those due to a mass of granulation-tissue, when the latter occupies the position just mentioned. It would appear, therefore, as if, in those cases in which there are no obstructive granulations, our prognosis should be the same with regard to the improvement of the hearing as with regard to the arrest of the discharge. This is true in perhaps the majority of cases. In a certain proportion of the cases, how-



ever, the hearing seems to be affected by other changes, directly dependent upon the arrest of the discharge. Thus, for example, after we have succeeded in arresting the discharge, the patient will be conscious for a short time that his hearing is better than it was during the continuance of the discharge. Then gradually the hearing will become less acute and the patient will complain that he does not hear as well as when the discharge existed. If some slight exposure causes the otorrhœa to return, we may observe the apparently perplexing phenomenon of an increased acuteness in the hearing power due to the re-establishment of a purulent otitis media. The explanation of these conflicting phenomena, which are encountered by no means rarely, is undoubtedly the following: So long as the soft parts surrounding the stirrup, and especially its foot-plate, are moist, this ossicle possesses its highest degree of mobility. For a short time after the discharge has been arrested these soft parts remain simply moist, and, in the absence of any considerable quantity of free fluid, which would of course act as a damper, the stirrup can vibrate with the maximum degree of freedom—that is, the patient's hearing will be at its maximum degree of acuteness. With the increasing dryness of these parts, however, they lose their flexibility, and the stirrup, or rather the stapedio-vestibular articulation, then becomes partially ankylosed, and the patient's hearing will then be at its minimum degree of acuteness,—a lower degree even than that which existed when the middle ear was filled with fluid.

Finally, we are sometimes called upon to state how far a chronic purulent inflammation of the middle ear is likely to endanger the patient's life. If we are asked the question in a general way, as for instance by the officers of a life insurance company, we can only say that a small proportion of all the individuals who are affected with a chronic discharge from the ear die from some form of disease directly induced by the ear affection.<sup>1</sup> If we are

<sup>1</sup>The practical question which presents itself to the life insurance authorities is this: Should a sweeping rule be laid down to the effect that all applicants who may be affected with a chronic discharge from the ear are to be rejected? Or should these cases be investigated, and the decision made to depend upon the result of the investigation? The sweeping rule affords undoubtedly the safest and simplest way out of the difficulty. At the same time such a course would lead to the rejection of many good risks, which rival companies would be quick to accept. On the other hand, if the attempt were made to discriminate carefully between the comparatively safe and the more dangerous cases of otorrhœa, the services of an expert would have to be secured, and to this additional expense the great majority of life insurance offices would object very seriously. In the next place, such expert examinations could only be obtained in the cities. This alone, therefore, would render the adoption of such a rule impracticable. I think, however, that if favorable answers can be obtained to questions bearing upon a few of the more important points, these cases of otorrhœa may be accepted as fair average risks. The points to which I have reference are these: duration of the discharge—whether constant or intermittent; its characteristics—whether thick or watery in its nature, whether odorless or offensive, and whether tinged with blood at times or simply purulent; the frequent occurrence of pain in the ear, or in any part of the head; and, finally, the existence of tenderness on pressure behind, above, or in front of the ear. On the other hand, if the

asked, on the other hand, to state the probabilities in individual cases, we must base our predictions upon a variety of data, viz., the past history of the case, the nature of the existing lesions, the care which is likely to be bestowed upon the diseased ear, etc. Frequent intercurrent acute attacks of inflammation in the past afford some indication of what may be expected in the future. If a large perforation exists in the drum-membrane, and the external auditory canal is of normal size, we may estimate lightly the danger of either mastoid or cerebral disease. A small perforation in the drum-membrane proper involves far less risk of serious intercurrent disease than does one in the region of Shrapnell's membrane. When the existence of a carious process can be demonstrated in or near the tympanic cavity, the patient should be warned of the serious nature of his disease, and he should be urged to keep the ear scrupulously clean, and to obtain skilled assistance with the least possible delay when pain develops in or near the ear. Farther on, I may recur to this subject of prognosis again.

#### DIFFERENT TYPES OF CHRONIC PURULENT INFLAMMATION OF THE MIDDLE EAR.

##### *I. Simple Uncomplicated Cases.*

Strange as it may seem, the number of cases that belong strictly to this first group is by no means so large as one might suppose. It is quite possible that the absolute number of such cases is large; but, as the symptoms are not of a troublesome nature, many patients probably think it unnecessary to consult a physician, and so it happens that the aurist sees only a few of them. The only difference that exists between these cases and those of subacute catarrhal inflammation of the middle ear is, I suspect, the following: in the former group the absence of the whole or a part of the membrana tympani leads to the establishment of a more active secretion from the mucous membrane of the middle ear than is apt to be the case when the drum-membrane is entire. The exciting cause is probably the same in both sets of cases; it is only in the outward manifestations of these diseases, but not in their intrinsic nature, that a difference exists between the two. The term employed by many English and German writers to designate the purulent form of the disease,—viz., "purulent catarrh of the middle ear,"—is one which seems to be peculiarly appropriate to this class of cases. At the same time there

---

applicant states that the discharge is abundant, that it is offensive, that it is occasionally bloody, and that he is subject to pain in the region of the affected ear or throughout that side of the head, the risk should certainly be considered as extra hazardous.

are decided objections to the employment of the term "catarrhal" in this connection. The chief distinguishing feature of these simpler uncomplicated cases of chronic purulent inflammation of the middle ear is the total absence—so far, at least, as can be ascertained from the character of the discharge and from the visible and tangible lesions—of any evidences of active inflammation, or of the development of granulation-tissue.

The following case may be taken as a type of the form of disease now under consideration:

The patient, a lady, forty years of age, stated that she had passed through a rather severe attack of purulent inflammation of both ears when she was quite a young girl. She believed that the attack had begun while she was convalescing from scarlet fever. From that time forward she had been subject to an intermittent discharge from both ears, never copious nor offensive, and, so far as she had observed, never materially affecting her hearing. On examination (April 6, 1871), I found both drum-membranes perforated, the opening in each being of large size. A very slight quantity of thin secretion moistened the lower wall of the external auditory canal. The mucous membrane of the promontory was pale, moist, and moderately thickened. At no point was there any evidence of active irritation. No treatment was advised beyond the occasional cleansing of both ears with a little lukewarm water. Four years later (June 8, 1875) I again saw the patient. She reported that no change had taken place in the course of the disease; and, on examination, I found almost precisely the same picture as that which I had observed in 1871. On the left side it seemed to me that the perforation had materially increased in size.

In cases like the one which I have just narrated it would undoubtedly be easy to control the slight discharge for a limited period by instilling into the middle ear a feebly astringent solution, say one of nitrate of silver (gr. ij. ad ℥ j.); but in these typically chronic cases we cannot look for permanently beneficial results, and it is therefore better not to urge the patient to submit to treatment. In cases of more recent origin, and especially in those which are characterized by a small perforation in the drum-membrane, treatment is more likely to produce results which will be permanent and which the patient cannot fail to appreciate. The following case may serve as an illustration:

The patient, a merchant, forty years of age and in good health, first noticed a discharge from the left ear during the second week of August, 1878. It came on without pain, and continued unchecked up to the 13th of September. On examination made at that time, the external auditory canal was found to be filled with a moderately thick, purulent fluid. A perforation about the size of a pin's head, and with sharply defined limits, occupied the central portion of the drum-membrane, which otherwise appeared to be natural, or at least free from any evidences of inflammation. After the middle ear had been inflated (Politzer's method), for the purpose of driving out as much of the secretion

as possible, a few drops of a ten-grain solution of nitrate of silver were dropped into the left ear, firm pressure was then made upon the tragus, and at the same time the patient was told to perform the act of swallowing, three or four times in succession. In this way the remedial solution was brought in contact with probably a large part of the tympanic mucous membrane. No appreciable pain followed this procedure.

On the 16th of September the patient reported that the discharge ceased on the 14th, and that the ear since then had felt quite natural. On examination, both the external auditory canal and the tympanic cavity were found to be perfectly dry; the perforation still existed.

There can be very little doubt that the perforation in this case was the result of some former attack of inflammation of the middle ear, and not of the painless attack which I have just described. In the next place, the prompt manner in which the tympanic mucous membrane returned to a healthy condition and remained so for many months afterward (I have met the patient frequently since 1878), shows conclusively that the case belongs strictly in this first class of uncomplicated cases. Finally there is still another point of practical importance which is suggested by this case. The method which I employed of introducing the remedial solution into the middle ear is a rather crude but useful method of accomplishing the desired purpose, provided the perforation in the drum-membrane is sufficiently large (*i. e.*, not much smaller than the head of an ordinary pin). If the perforation, however, is quite small, the middle-ear pipette will be found to afford the only sure means of introducing fluids into the tympanic cavity. As this subject of medication of the middle ear is one of great practical importance, I make no apology for giving below, in brief outlines, the histories of three cases in which the successful results obtained were largely due, I believe, to the employment of this more direct method of introducing remedies into the tympanic cavity.

CASE I.—The patient, a clerk, about thirty-five years of age and in good general health, was brought to me by his physician on the twentieth day of October, 1879. The story which he gave of his ear trouble was this: About the first of October he was struck on the left side of the head, and for nearly a week afterward he experienced severe pain in the left ear. On or about the fourth day he discovered that pus was escaping from the left auditory canal, and from that time forward the discharge had been constant. On examination, I found the left external meatus filled with a thick, purulent fluid. A perfectly circular perforation occupied the posterior inferior quadrant. It presented no resemblance whatever to a perforation of traumatic origin, *i. e.*, due to the violent concussion of the air in the meatus. In all other parts the membrana tympani presented a very whitish and tough appearance. The impression made upon my mind was that at some earlier period of his life the patient had been subject for a long time to a purulent inflammation of the left

middle ear, and that both the perforation and the marked hypertrophy were the results of that earlier inflammation; while the blow which he had recently received had merely brought on a somewhat severe otitis media purulenta acuta. From the patient, however, I was unable to obtain any evidence corroborative of this view. He was positive that the ear had always been perfectly healthy before he had received the blow.

I advised the attending physician to instil (three times a week) a five-grain solution of nitrate of silver into the external meatus, after he had thoroughly removed all the pus, and then to force it through the perforation into the middle ear in the manner described above. I then performed the operation once in his presence, in order that he might see exactly how the treatment was to be carried out.

On the 9th of November the physician brought his patient to see me a second time. He reported that the discharge had increased rather than diminished. On questioning the patient I ascertained that he had not once tasted the silver solution since the day on which I first saw him; in other words, it is fair to assume that the remedial solution had only on that occasion been successfully brought in contact with the tympanic mucous membrane. This plan of treatment having failed I resorted to the use of the pipette, and introduced two or three drops of a ten-grain solution of nitrate of silver into the tympanic cavity. The patient felt it in his naso-pharyngeal space almost instantly. He also experienced quite a sharp earache, which was relieved in about one minute by pouring rather hot water into the upturned meatus.

On the 11th and 13th of November the remedy was again introduced into the middle ear in the same manner, and on the 15th the patient reported that there had been no discharge during the previous forty-eight hours. Inspection of the parts also showed that the discharge had entirely ceased, and that even the tympanic cavity was free from unnatural secretion.

On the 9th of January, 1880, the patient consulted me again. He stated that about five days after I last saw him, the discharge had reappeared, and had been constant since that time. He had been too much occupied with his business affairs, however, to place himself again under medical care. The same plan of treatment (with the pipette) was resumed.

January 11th.—Discharge still active. Silver solution introduced a second time.

January 14th.—No improvement perceptible. The thought then occurred to me that my lack of success was probably due to the fact that the remedial solution did not come in contact with more than a comparatively small portion of the tympanic mucous membrane, owing partly to the imperfect manner in which I cleansed the cavity of the middle ear, and partly to the small quantity of the remedial solution injected. I accordingly syringed out the tympanum with Blake's middle-ear syringe, using the entire contents of a full syringe (a little over one drachm) for that purpose. So far as I could discover, this procedure brought away only a littleropy mucus. I then injected into the middle ear two or three drops of a ten-grain solution of nitrate of silver, and, after the lapse of a few minutes, no pain having developed in the meantime, I repeated the operation, each time causing the solution to pass through the Eustachian tube into the naso-pharynx.

The patient returned on the 17th of January and reported that the discharge had entirely ceased. Inspection also confirmed this statement. Before dismissing the patient, however, I introduced into the left tympanic cavity, by means of the slender middle-ear probe, two or three pellets of powdered iodoform and burned alum, in about equal parts. About six weeks later he reported that up to that time no relapse had occurred.

CASE II.—The patient, a man forty years of age and in good general health, stated that in boyhood he had passed through an attack of scarlet fever, which left him with both ears damaged. At long intervals he had had a discharge from the right ear, and recently he had also noticed a sense of fulness in the left ear, and at times a slight watery discharge from it. On examination (December 27, 1879), I found the left meatus moistened with a thin, watery discharge, and the membrana tympani somewhat bulging and decidedly soaked in appearance. No perforation was visible, but probably a small, valve-like opening existed in the posterior half of the membrane. When Valsalva's experiment was performed by the patient, the membrana tympani yielded as a whole to the pressure from within, but there was no escape of fluid to indicate the location of the perforation. I might state here that sometimes, in acute cases, the transudation of fluid through the unbroken membrana tympani is so active as to produce not merely a moist condition of the auditory canal, but even a discharge from the external orifice. It is quite possible that such a state of things existed in the present case. At the same time it is not safe to infer that no perforation exists simply because we are unable to discover one. A small mass of mucus may effectually plug the opening for a short time, or its edges may become glued together temporarily. The existence or non-existence of a perforation, however, was not in this instance a matter of any importance, as it was very evident that the perforation—if it really existed—was too small to be of much service as an outlet. I therefore made a free incision through the bulging posterior half of the membrane, and afforded escape to some pinkish serum. Although the pressure had been withdrawn the posterior half of the membrane retained its convex condition, showing clearly that the pressure from within must have been of comparatively long standing. Without any preliminary washing-out procedures, I introduced, with the pipette, two or three drops of a two-grain solution of nitrate of silver into the middle ear. No unpleasant symptoms followed.

On the 28th of December, the discharge still continuing, and the opening in the membrane still being of ample size, I introduced a five-grain solution into the tympanic cavity. None of it appeared to reach the naso-pharynx in the ordinary manner, but yet, almost instantly after the injection had been made, tears began to flow freely from the patient's left eye, and for perhaps two or three minutes he experienced quite a sharp pain in the ear.

On the 30th of December patient reported that the discharge had diminished in quantity and that the ear felt lighter (*i.e.*, less full). On examination I found that the lower wall of the meatus was barely moist, and that the posterior half of the drum-membrane had almost entirely lost its unnatural convexity. The perforation had nearly healed. After clearing out the middle ear by means of Politzer's method of inflation, I injected into the tympanum, by means of the pipette, a much larger quantity of the

silver solution (five grains to the ounce) than I had ever injected before. It amounted to at least ten drops, and, as the perforation was then quite small, no regurgitation took place, as on the previous occasion. Tears at once came into the left eye, and for some minutes the patient was unable to utter a word, so much of the solution had escaped into his throat. A watery fluid ran for a short time in an almost continuous stream from the left nasal orifice. The pain in the ear was quite sharp, but it yielded very quickly to instillations of hot water.

On the 2d of January, I found that the discharge from the ear had almost ceased. As there seemed to be no free fluid in the middle ear, I forced through the perforation, into the tympanic cavity, a few small pellets of powdered iodoform and burned alum.

January 4th.—Same condition. Iodoform and alum introduced a second time.

On the 8th of January the patient reported that the discharge had not reappeared since the 4th inst. On inspection I found the membrana tympani pale, dry, and of perfectly natural curvature. A small scab covered the site of the perforation. The hearing distance for the watch had increased from two inches up to nine inches. So far as conversation was concerned, the patient experienced no difficulty whatever in hearing all that was said to him. (On the right side, I should have stated before, the drum-membrane was amalgamated with the tissues of the promontory.)

CASE III.—The patient, a college student, seventeen years of age and of good physique, consulted me on the 16th of September, 1878, on account of a discharge from both ears, associated at times with pain. So far as he could remember, the discharge began during his childhood, and had continued without intermission up to that time. On one or two occasions he had found the secretion slightly stained with blood. Furthermore, the discharge varied in activity, at times being barely perceptible. During the period immediately preceding his visit, however, it had been more profuse than usual. On examination I found both auditory canals filled with thick muco-pus. Both drum-membranes presented the same lesions, viz., a small, round perforation in the posterior inferior quadrant, marked bulging of the posterior half, a generally tough and soaked appearance of the whole membrane, and, finally, entire absence of any evidence of active irritation. The most urgent indication on both sides, therefore, was to establish a free outlet, and thus to relieve the constant condition of pressure upon the mucous membrane of the middle ear and the constant partial stagnation of the purulent secretion. I therefore made a long, crescent-shaped incision in the posterior half of each drum-membrane, and, after removing as much of the fluid contents of the middle ear as I could, I injected several drops of a ten-grain solution of nitrate of silver.

On the following day, the 17th, the patient reported that the discharge had diminished noticeably in quantity, especially on the left side. He had also experienced no pain since the operation. (And here I might state that, if the precaution be taken to establish an opening of ample size in the membrana tympani, before we inject our remedial solution into the middle ear, we need entertain no fear that a prolonged painful reaction will follow this procedure. If the perforation, however, is quite small, my rule is, not to inject a solution of nitrate of silver of greater strength than two grains to the ounce of water.) On inspection

I found that the edges of the wound, in both drum-membranes, were somewhat red and swollen. No injections made.

On the 18th I repeated the injections, using on both sides a forty-five grain solution of nitrate of silver. Very little pain followed.

On the 19th I found that the discharge was very trifling. I therefore pushed a few pellets of powdered iodoform (‡) and burned alum (§) through the perforation into the tympanic cavity.

On the 20th I repeated this procedure.

On the 23d the patient reported that he had been entirely free from discharge since the 20th, and on examination I found the parts almost perfectly dry. As the patient was anxious to return on that day to his home in Michigan, I was unable to keep the case any longer under observation. I have very little doubt, however, that what was then an apparent cure proved to be a permanent one.

To these three histories I might add a fourth, which illustrates a somewhat different method of treatment.

The patient, a child, six years of age, had been subject since infancy to a slight watery discharge from the left ear, the result of an attack of measles. On examination (Oct. 11, 1876) I found a moderate amount of thin, purulent secretion in the left meatus. The membrana tympani showed no evidences of active inflammation, but a small circular perforation occupied the anterior inferior quadrant. After drying the parts as thoroughly as I could, I introduced the end of the middle-ear probe, on which a bead of nitrate of silver had been fused, into the middle ear through the perforation. I pressed it for an instant against the mucous membrane near the orifice of the Eustachian tube, and then quickly withdrew it. The child made no complaint of pain afterward.

On the 14th of October the mother reported that no discharge had been seen since the 11th, and that the child's hearing had appreciably improved. Inspection showed the parts to be perfectly dry.

The objection to this latter plan of treatment, in the simple uncomplicated cases of otitis media purulenta chronica, is this: if we allow the bead to remain in contact with the tympanic mucous membrane for too long a time, we may subject the patient to unnecessary pain. Taking all things into consideration, I have no hesitation in asserting that nitrate of silver in the form of a weak solution (from two to five grains to the ounce of water), if brought thoroughly in contact with the mucous membrane of the middle ear, constitutes the most efficient and most easily managed remedy that we possess for the treatment of these uncomplicated cases of chronic purulent inflammation of the middle ear.

## II. Proliferative Cases.

As the cases belonging to this second group are almost invariably characterized by either an abundant or an offensive discharge,—two symptoms which are annoying to the patient and



which therefore lead him to seek relief,—they will be found to constitute, I think, the larger part of all the cases of otitis media purulenta chronica which come under the aurist's observation. The feature which distinguishes them from the cases that belong to the preceding class, consists in the proliferative tendency displayed by the inflamed mucous membrane. This proliferative process affords unmistakable evidence that the mucous membrane is being subjected to some unusual irritating influence. There are two ways in which we can account for the existence of such an irritating influence. In the first place, decomposition may take place in the secretion and impart to it properties which are in the highest degree irritating. Under the influence of this irritation the mucous membrane begins to proliferate at one or more points, and so granulation-tissue, or a distinct polypoid growth representing an enormous hypertrophy of all the normal structures of the tympanic mucous membrane, may be developed. In other cases, however, the irritating influence may emanate from an entirely different source. Thus, for example, prolonged pressure, during the original acute attack, may have deprived the superficial portion of the bony wall of the tympanum, over a limited area, of its nourishing supply of blood, and thus have produced death both of the bone and of the mucous membrane immediately covering it. Such a caries of the bony wall of the tympanum supplies a secretion of a very irritating character, and, under the constant stimulus of this irritant, masses of granulation-tissue are formed in precisely the same manner as they are formed at the orifice of a sinus leading from the surface of the body to a spot of carious bone. When, therefore, we find granulation-tissue or polypoid growths in the middle ear or external auditory canal, we may feel perfectly sure that a discharge of an irritating nature bathes these parts. Here, then, is furnished the first and most important indication of what is required in the way of treatment, viz., that in all cases belonging to this second class we should adopt every means at our command to keep each nook and corner of the middle ear and external auditory canal clean. If the irritating secretion owes its peculiar properties simply to the decomposition which always takes place in a stagnating animal secretion, systematic and thorough cleansing will often of itself, without other measures, produce the desired cure. If the irritating secretion, however, comes from a superficial bone-caries, we can scarcely expect simple cleansing measures to produce as prompt and satisfactory results as in the proliferative cases which are not dependent on bone-caries.

Granulation-tissue may develop at any point in the cavities of the middle ear. Growths of this kind are found more rarely in the vicinity of the orifice of the Eustachian tube than in any

other part of the tympanic cavity. Speaking again simply from memory, I should say that they develop more often at the posterior and upper portion of the tympanic cavity than at any other point. So far as their texture and size are concerned, they differ widely. Some are extremely vascular, while others are but poorly supplied with blood-vessels; some have almost the soft consistency of a myxoma, while others are as hard as the hardest fibroid growths; some are as small as the head of a pin, while aural polypi very commonly reach the size of a bean. For a long time I had one in my collection which measured an inch and three-fourths in length, and fully half an inch in diameter at its broadest point. It is not an uncommon experience to find the larger growths lobulated or branching.

So far as my experience goes, the great majority of polypoid growths encountered in the external auditory canal are of middle-ear origin. Furthermore, even the largest of these large polypoid growths will be found, as a rule, to possess remarkably small peduncles.

It would almost require a separate treatise to describe thoroughly the different pathological pictures that are presented by these proliferative cases of chronic purulent inflammation of the middle ear. Furthermore, the value of such an exhaustive description would be small in comparison with the labor that it would entail. I will describe, therefore, only a few instances of this proliferative variety.

CASE I.—The patient, a strong, healthy boy, seven years of age, was brought to me by his mother on the 3d of October, 1872. She stated that he had had a constant discharge from the right ear since early infancy. On examination, I found the meatus partially filled with pus. The membrana tympani had been totally destroyed. All that remained of the handle of the hammer was a mere stump, which projected into the cavity of the tympanum. The mucous membrane covering the promontory was much hypertrophied, and at two or three points it presented small knobs of granulation-tissue. From the posterior and upper portion of the tympanic cavity a polypoid growth sprang. It was of moderate size, and its peduncle was comparatively small. By means of Blake's snare I removed this growth without any difficulty. To the stump and to the remaining smaller knobs on the promontory I applied powdered burned alum. My instructions to the mother were, that she was not to syringe the ear with lukewarm water until the discharge reappeared,—my object being to keep the alum in contact with the granulating surfaces as long as possible.

Failing to arrest the discharge entirely by means of these applications of powdered burned alum, on the 15th of October I applied the liquor ferri subsulphatis, on a small pledget of cotton, to the base of the polypoid growth, and touched the granulating spots on the promontory in the same manner with a forty-five grain solution of nitrate of silver.

On the 21st of October I applied powdered burned alum again, the discharge having in the meantime almost ceased.

On the 24th of October I found the parts perfectly dry and quite natural in appearance.

On the 19th of January, 1880, more than seven years later, I had an opportunity of examining the ear again. To my great surprise the drum-membrane had been almost entirely reproduced. Posteriorly and superiorly a small gap still remained, but everywhere else a very thin and very much depressed membrane separated the cavity of the tympanum from that of the external meatus. (See remarks on p. 284, with reference to the reproduction of the membrana tympani.)

CASE II.—The patient, a girl eight years of age, had been affected with a discharge from the left ear since early infancy, the discharge at times being stained with blood. On examination, October 29, 1873, I found the canal ulcerated, very much narrowed, especially in its deeper portion near the drum-membrane, and bathed with a rusty-colored secretion. The condition of the membrana tympani and middle ear could, at that time at least, only be inferred from the history of the case, and from the fact that during inflation air escaped freely from the external auditory canal. The slightest touch with the mop of cotton caused the ulcerated walls of the meatus to bleed. The treatment adopted was the following: at the Infirmary I cleansed and dried the canal as thoroughly as possible, and then applied nitrate of silver to the entire surface—the first time, a forty-five grain solution; on the 5th of November, the pure salt, in the form of a bead fused on the end of the cotton-holder; and at her home the patient's ear was syringed regularly three or four times a day with lukewarm water. Under this plan of treatment the discharge—which undoubtedly came in large measure from the ulcerated walls of the meatus—diminished greatly in quantity and assumed the character of a moderately thick purulent secretion, free from any admixture of blood. The swelling of the canal so far diminished that on the 8th of November I was able to make out the exact condition of the middle ear. The drum-membrane had been entirely destroyed. Two polypoid growths, having rather large peduncles, sprang from the posterior end of the tympanic cavity. Both of these were removed with the snare.

On the 19th and 26th of November I applied nitrate of silver to the bases of the growths recently removed, as they showed a strong disposition to grow again.

On the 29th I used the snare for the purpose of cutting down the knobs of granulation-tissue—the bases of the former polypoid growths—as nearly as possible to the level of the surrounding mucous membrane. I then touched the remaining raw surfaces lightly with chromic acid.

On the 3d of December I found the region which I had recently burned with chromic acid almost on a level with the surrounding mucous membrane. The discharge, too, had almost ceased. I accordingly applied powdered iodoform to the parts, and gave instructions that the syringing was to be discontinued.

On the 6th of December, the discharge having ceased and the parts appearing to be perfectly free from irritation, I dismissed the case as no longer requiring treatment.

In the preceding case I would call especial attention to the

swollen and ulcerated condition of the cutaneous walls of the external auditory canal. In infirmity practice this is not an uncommon lesion in cases of chronic purulent inflammation of the middle ear. It shows clearly that no attempts whatever have been made to keep the ear clean, or else that these efforts have not been skilfully conducted. In such cases our first attention should be directed to the restoration of the meatus to a healthy condition. Frequent and thorough douching or syringing of the ear at home, and the occasional application of nitrate of silver (pure, in the form of a bead) to the greater part of the swollen and ulcerated surface by the physician, are the two things that will most rapidly restore the parts to a healthy state. When this has been accomplished the treatment of the diseased middle ear can be undertaken intelligently, and with good prospect of a successful issue.

I might mention here that in cases of chronic otorrhœa living maggots, the larvæ of the ordinary house-fly, are occasionally found in the meatus or even in the tympanic cavity. I have only once or twice encountered them in the ear, but they have been seen more frequently by Gruber,<sup>1</sup> Blake,<sup>2</sup> and others. The explanation usually given is this: the fly, attracted by the offensive odor of the discharge, deposits her eggs in the meatus near the external orifice; and in this decomposing fluid the eggs find a soil suitable for their development into living larvæ.

In certain cases the proliferative process in the tympanic mucous membrane takes place in an ear which still possesses an almost entire membrana tympani. These cases are comparatively rare, and they are usually very difficult to manage. I should like very much to discuss here in detail this rare but very attractive combination of lesions, but I can only give the history of a single case, as the scope of the present treatise will not admit of the detailed discussion of a topic of such narrow limits.

The patient, a girl six years of age, was brought to me by her mother on the 17th of July, 1879. About five months previously, as I was told, she had passed through quite a severe attack of scarlet fever, which left her with a double otorrhœa. On examination I found the left drum-membrane destroyed, and the mucous membrane of the middle ear in a granulating condition. The hearing-power of this ear was still quite good. On the right side I found the inner end of the meatus filled with a soft polypoid growth, which concealed the deeper parts of the ear. By aid of the snare I removed the greater part of this polypus. I found that it sprang from some portion of the mucous membrane of the middle ear, and that its peduncle emerged through a circular perforation (about two millimetres in diameter) in the membrana tympani, just below the tip of the handle of the hammer, and

<sup>1</sup> Monatschrift für Ohrenheilkunde, III. 3, March, 1869; III. 4, April, 1869.

<sup>2</sup> Archives of Ophthalmology and Otology, II. 2, p. 37.

then branched out into two distinct lobes, which together formed a mass about as large as a large pea. Assuming that the growth sprang from the upper portion of the tympanic cavity posteriorly, I gave the wire loop such an inclination to the silver cannula that I was able to remove all visible portions of the polypoid growth. In other words, so far as I could see through the perforation into the cavity of the tympanum, every trace of the polypoid growth had been excised.

On the 4th of August, the patient having returned from the country, I examined the ear again, and found that a dry, cicatricial membrane had grown over the former opening in the drum-membrane. On touching this cicatricial portion, however, with the probe, I was surprised to find that it offered the same degree of resistance that one would expect to find in a moderately tough polypoid growth. No appreciable improvement had taken place in the hearing.

On the 6th of August, that is about forty-eight hours later, I was astonished to find in the place of the cicatricial membrane a moist, succulent, but not granulating surface. My interpretation of this apparently sudden change was this: the slow growth of the intra-tympanic polypoid mass, and the unusually slight quantity of pus formed during the growing process, had allowed the perforation an opportunity to heal by the formation of a cicatricial membrane. Then the increasing pressure from within, exerted by the growing tumor upon the thin cicatricial membrane, had caused the two to unite into one continuous mass of tissue, and as a result of this union the outer cicatricial portion had assumed some of the characteristics of granulation-tissue. Already on the 4th, when I examined the ear, the polypoid growth had reached the plane of the cicatricial membrane, and communicated to it that semi-solid condition which puzzled me not a little at the time; but it was not until the 6th that the union had become sufficiently intimate for the latter membrane to assume some of the characteristics of the deeper growth.

The child returned with her parents on the 6th to their home in Nebraska, and I did not see her again until the 5th of December, 1879. The discharge had reappeared in the right ear during this interval, and had become quite abundant. On examination I found that the appearances presented by the right membrana tympani had changed very materially. In the first place, the membrane as a whole had been drawn inward beyond the position which it had previously occupied. Quite low down anteriorly there was a very small perforation. Touching different parts of the membrane gently with the probe, I found that it offered solid resistance throughout the central portion; in other words, it had become amalgamated with the mucous membrane of the inner wall of the cavity. While at all other points the drum-membrane presented a pale and tough appearance, that portion which corresponded to the former cicatrix was of a pale purplish hue, and perhaps a trifle more concave than the surrounding portions. So far as I could ascertain, the Eustachian tube was impervious to air. For the purpose of arresting the discharge, I injected into the middle ear daily, for four or five days, a five-grain solution of nitrate of silver, by means of the middle-ear pipette. Under this plan of treatment the discharge ceased on the fourth or fifth day.

On the 15th of January, 1880, I found the right drum-membrane perfectly dry and free from any evidence of active irritation. A

very minute perforation still remained in the anterior inferior quadrant. In front of the perforation, and also posteriorly near the periphery, the membrane seemed, when I pressed upon it with the end of the probe, to be free. All the intervening central portion, however, appeared to be solidly amalgamated with the mucous membrane of the opposite wall. As no discharge had made its appearance for several weeks, I allowed the patient to return home.

Sometimes the proliferative tendency will restrict itself to the membrana tympani. In one case, for example, I made the diagnosis of a simple uncomplicated otitis media purulenta chronica, and treated the patient for weeks without success. Finally, I one day noticed something of a pinkish hue just beyond (*i.e.*, on the inner side of) the edge of the small perforation, and, on closer investigation, found it to be a small polypoid growth which sprang from the inner aspect of the edge of the perforation. With some trouble I managed to get a fine wire loop around the growth and succeeded in cutting it off close to the drum-membrane. The discharge, which had previously resisted every effort to arrest it, then stopped as if by magic. In this particular case, previous to the discovery of the polypoid growth, I did—in a moment of desperation—what I would not advise others to do: I instilled a very strong solution of nitrate of silver (120 grains to the ounce) into the external auditory canal, and then forced it through the perforation and through the Eustachian tube. The operation was followed by severe pain in the ear and by nose-bleed. Both symptoms, however, lasted but a short time, and the discharge was reduced to a minimum for several days.

In a second case, in which the discharge was very slight, I found a sharply defined, pedunculate polypus growing from the edge of the rather small perforation and resting against the outer surface of the membrana tympani. The removal of the growth with the snare, which was of course effected very easily, caused the discharge to cease and a scab to form over the perforation. Fifteen days later I had an opportunity of examining the ear again, and found the scab still occupying the same position.

I might mention briefly in this connection certain peculiar lesions which I have encountered thus far only twice. I refer to the development of a granulating condition in an old cicatrix of the drum-membrane, without the re-establishment of a perforation. In the first case the patient, a laborer, twenty-six years of age, had been subject for a short time, about a year previously, to a discharge from the right ear. The discharge gradually diminished and finally ceased; but at the time when I saw him (November 22, 1873) it had reappeared. On examination I found the right membrana tympani red, swollen, and smooth everywhere except over the greater portion of the posterior superior

quadrant. Here the membrane presented a bright red and granulating surface, which bled upon the slightest touch. To this region I applied a forty-five-grain solution of nitrate of silver, by means of a cotton mop.

On the 29th of November I found that the granulating portion of the membrane had apparently become scabbed over. When I inflated the middle ear, the posterior superior quadrant of the membrane remained for a few moments in a markedly bulging condition, showing almost conclusively that no perforation existed at this point, and also that the membrane in this region had lost its substantia propria.

In the second case the ulcerated or granulating spot was circular in shape and occupied the central portion of the lower half of the membrane. In this case I resorted to inflation before the part had become scabbed over. The result was that the ulcerated

portion alone responded visibly to the increased aërial pressure within the tympanum. It would seem, therefore, as if cicatrices of the drum membrane were in a measure predisposed to ulcerative action.

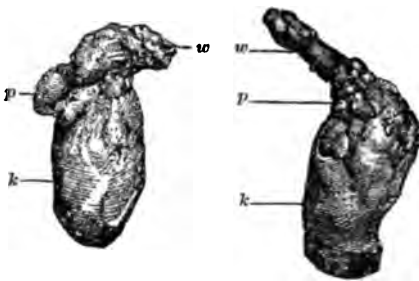


FIG. 63.—Aural Polyp. *w*, root; *k*, body of polypus; *p*, round excrescences growing on polypus. Actual size. (After Politzer.)

very little need be said. Their size varies from that of a pin's head to that of a large bean. In exceptional cases growths as large as those shown in Fig. 63 are encountered, but the great majority are not larger than an ordinary-sized pea. In shape they are usually either round or bean-shaped, but not infrequently papillary or lobulated growths are met with. Anatomically, aural polypi are almost always found to be simple granulation growths, or simple mucous polypi. A section of one of these growths is shown in the accompanying cut (Fig. 64), kindly placed at my disposal by Dr. Bacon. Fibromatous polypi are occasionally met with in the ear, but on the whole they are comparatively rare. Myxomata, sarcomata and angiomata (Fig. 65) are very seldom seen in the ear,—perhaps more seldom even than epithelial tumors (carcinomata).

We come now, finally, to the consideration of the measures that may be employed to advantage in removing polypi or masses of granulation-tissue from the middle ear. Very few surgeons at the present day advocate the removal of aural polypi (*i.e.*, growths

of an appreciable size) by any other than mechanical means. The slow, unsatisfactory, and sometimes painful plan of destroying them by caustics or astringents has been very generally abandoned. If a large polypus fills the external auditory canal and presents itself within easy reach at the outer orifice, an ordinary dressing-forceps, or, better yet, Hinton's polypus-forceps, will serve the desired purpose as well as any other instrument with which I am acquainted. The mass is firmly grasped between the blades of the forceps, and is then separated from its deeper attachments by a combined rotary and pulling motion, or simply by direct

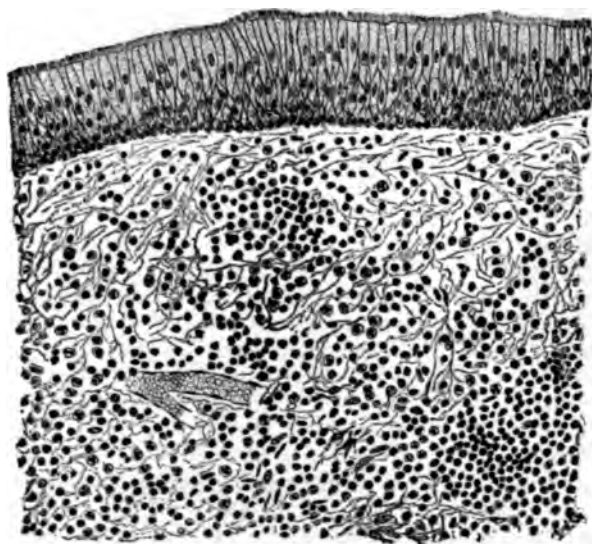


FIG. 64.—Cross Section of a Mucous Polypus, covered with ciliated cylindrical epithelium. (Drawn by Dr. Ira Van Gleason, from a specimen belonging to Dr. Gorham Bacon, of New York.)

traction. Farther on, I will state under what circumstances traction is not to be employed. If the polypus, however, is situated more deeply in the canal, and reflected light is required to render the mass visible, such an instrument as Hinton's forceps—unless the canal happens to be unusually large—will be found awkward to manage and productive of pain to the patient. Blake's snare<sup>1</sup>

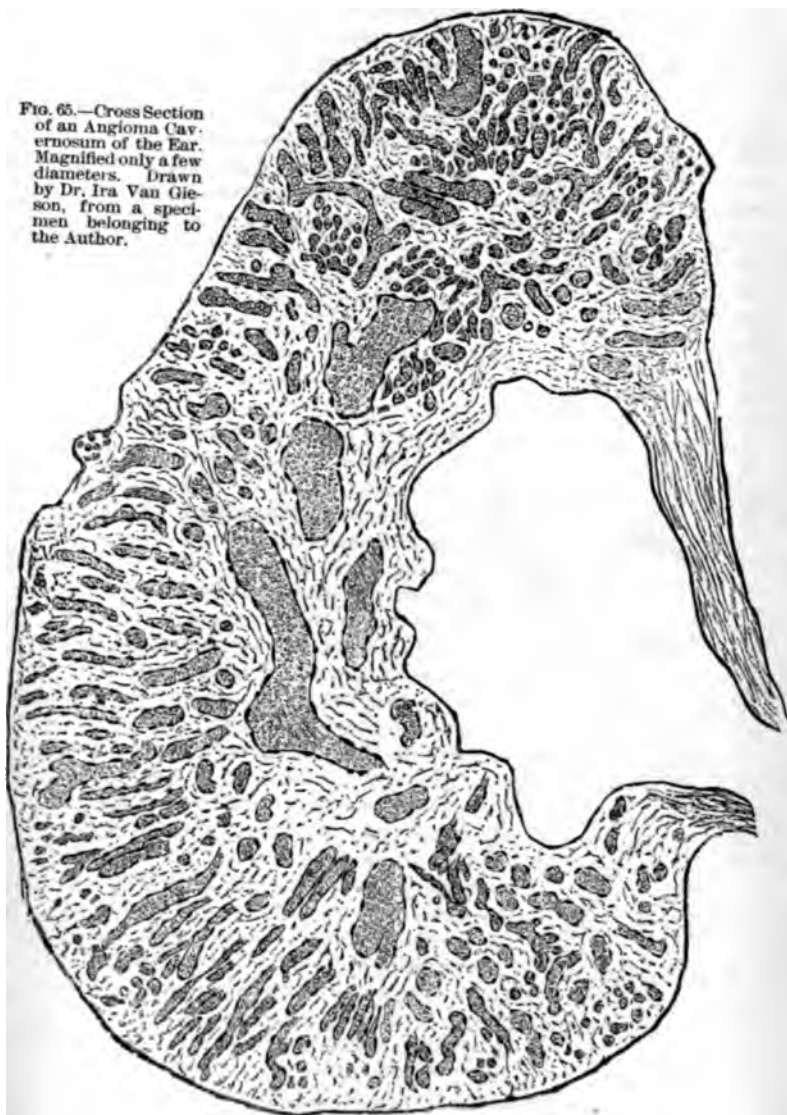<sup>1</sup> This instrument, which was introduced by Dr. Clarence Blake, of Boston, in 1869 or 1870, is sometimes spoken of as "Blake's modification of Wilde's snare." Those, however, who have compared the two instruments, and know from practical experience how different they are from each other, will agree with me that the more recent instrument is justly entitled to the name of "Blake's snare." In 1872 or 1873 the instrument was still further improved by the substitution of a simple cannula of soft (pure) silver for the double-mouthed steel or German-silver tube usually sold with the instrument. The pure silver cannula measures three inches (8 cm.) in length



is the proper instrument to use under these circumstances. By aid of the slender silver probe the physician can ascertain whether the mass grows from the cutaneous walls of the canal or from the middle ear or mastoid cells. Where the growth is of such a size as to fill the canal, it is not necessary that he should satisfy himself of the exact situation of the base of the polypus before applying the loop of wire. It is sufficient for him to ascertain by actual probing that he can pass his snare over the mass to a given depth (distance from the orifice of the meatus) without encountering any obstacle. The loop is then pushed in over the mass to this depth and tightened sufficiently to hold the polypus firmly in its grasp. If the growth is succulent and not very firm, and especially if it can easily be rotated about its long axis, steady traction should be made, in the hope of pulling out the polypus, peduncle and all. In not a few cases this object will be attained; but even if the effort fail to remove the entire growth, at least as much of the mass will be torn off as would have been if the wire had been made to cut through the polypus instead of simply grasping it firmly. If the growth is firm in texture and not easily rotated, it is better to use the loop simply as a means of cutting off portions of the growth. The same remark applies to the use of Hinton's polypus-forceps. Where the growth is firm in texture and firm in its deeper attachments, traction must not be employed. As soon as the bleeding has ceased, and the portion cut off by the wire loop has been removed with the bent forceps, the remainder of the growth is to be treated in precisely the same way as the first portion. The wire loop is to be applied again and again until the base of the growth has been cut away to the level of the surrounding mucous membrane or skin. If the polypoid mass springs from some portion of the external auditory canal, it will be found as a rule decidedly firmer in texture and more sen-

and but one millimetre in diameter (externally) throughout its entire length (except where it fits into the handle), while the steel or German-silver one measures two millimetres in diameter and at the flaring end over two and a half millimetres. In cases where the external auditory canal is narrow, or where it is found necessary to remove a polypus which is situated within the tympanic cavity and which can only be reached through a comparatively small perforation in the membrana tympani, the great advantage of the slender silver cannula is very apparent. But this is not the only advantage. In the double-mouthed cannula the wire does not cut entirely through the polypus; a slender connecting cord of tissue always remains uncut between the wire and the septum which separates the two mouths of the cannula. With this cannula, therefore, the last step of the operation always consists in the tearing asunder of this connecting bridge of tissue—a procedure necessarily more or less painful to the patient. In the simple silver cannula the wire, on being withdrawn into the tube, cuts the polypus off entirely at the point of seizure, all necessity for traction being thus done away with. As a result of this, the operation of removing a polypus from the ear is in very many cases an almost painless procedure. Finally, the employment of very fine malleable steel wire (size—No. 37), may be designated as the latest improvement which has been introduced in connection with Blake's snare. Wire of this size possesses all the strength required for the removal of the great majority of polypi, and at the same time causes far less pain to the patient, whenever it comes in contact with the healthy and very sensitive walls of the auditory canal or of the middle ear, than does the heavier wire hitherto commonly employed.

FIG. 65.—Cross Section of an Angioma Cavernosum of the Ear. Magnified only a few diameters. Drawn by Dr. Ira Van Gleason, from a specimen belonging to the Author.



sitive than one of middle-ear origin. It will also not possess the same degree of mobility as the latter. In polypi of middle-ear origin we shall find that they spring more frequently from the upper and posterior portion of the tympanum (entrance to the antrum) than from any other locality.

*It is a good rule in practice not to resort to the use of caustics until the base or peduncle of the polypus has been cut away with the snare (skin or mucous membrane). Furthermore, in deciding whether the peduncle we are not to trust to of the peduncle, when furnished the only the exact relations rounding parts. It is anticipated that we cannot benefit to the patient, tringents. Before ment, it would per- the dangers, real erative procedure*

*duncle of the polypus has been cut to the level of the surrounding parts (skin or mucous membrane). Furthermore, in deciding whether the peduncle we are not to trust to of the peduncle, when furnished the only the exact relations rounding parts. It is anticipated that we cannot benefit to the patient, tringents. Before ment, it would per- the dangers, real erative procedure*

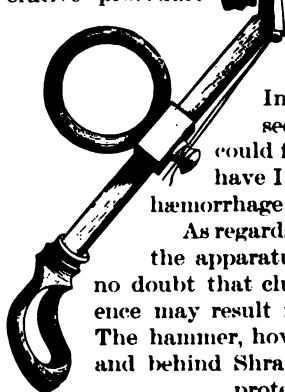


FIG. 66.—Blake's Polypus Snare. Actual size.

When the mass has been so far extirpated that we cannot benefit to the patient, tringents. Before ment, it would per- the dangers, real erative procedure

As regards *hæmorrhage* from the torn or cut surface of the mass, we need entertain very little anxiety. In malignant growths alone have I ever seen or heard of any loss of blood that could fairly be termed serious; and only once have I encountered anything like an arterial hæmorrhage requiring the use of a tampon or plug.

As regards the question of inflicting damage upon the apparatus of hearing in the middle ear, I have no doubt that clumsy and unskilful operative interference may result in serious impairment of the hearing.

The hammer, however, and the firm ridge in front of and behind Shrapnell's membrane, afford an excellent protection to the more deeply situated stirrup, which is by far the most important piece in the mechanism of the middle ear.

Polypi are occasionally encountered whose peduncles include in their substance the handle of the hammer (the rest of the membrana tympani being destroyed). In such cases the wire should be applied with caution, and no traction whatever should be employed. The few polypi of this kind which have come under my observation were quite small, and were attached to the ossicle by rather slender peduncles. In one of them, however, I made the very mistake which I am now cautioning against (*i.e.*,

I applied the wire to that portion of the peduncle which included the handle of the hammer), and only discovered my error by finding that the wire could not be drawn back into the cannula. By cutting the wire loose from the instrument and pulling upon one end of it, I experienced no difficulty in disengaging it from the ossicle.

Besides hæmorrhage from divided vessels and injuries to the ossicles, I know of no other danger which may arise in the course of the operation for removing an aural polypus.

As regards the *after-treatment*, this must be modified according to the location from which the growth springs. If the polypus grows from the cartilaginous portion of the outer canal (as a result, for instance, of an abscess in this locality), and is firm in consistency, the application of nitrate of silver in solid form to the base which remains after the removal of the fleshy mass, will act rather as a stimulant to further growth. Fuming nitric acid, applied cautiously but thoroughly to the base, is the only remedy upon which we can depend to arrest promptly a further reproduction of the growth. As the fumes of the acid are apt to prevent the operator from seeing clearly what he is doing, an instrument called a "porte-acid" has been devised, which enables the physician not only to apply the acid accurately to the desired spot, but also to confine its action in great measure to the region immediately cauterized. This instrument (Fig. 67) consists of a slender glass tube (about ten centimetres in length, not quite two millimetres broad, and somewhat flaring at both ends), through which a platinum wire of moderately small size passes. One end of the wire is bent upon itself, so as to prevent the mop of cotton-wool, which is wound round it, from falling off. When the instrument is to be used, the wire should be first pushed into the tube far enough to carry the mop end of the wire well outside of the flaring end of the tube. The mop having been dipped into the acid, the other end of the wire is then to be pulled out far enough to draw the mop well back into the flaring mouth of the tube. The base of the growth having first been thoroughly dried, the flaring end of the tube should be placed firmly upon the raw surface, and, while in this position, the mop should be pushed down firmly for an instant against the part to be cauterized. The reaction which follows is very slight, and the pain is of but short duration. The best way to remove the mop from the platinum wire is to burn it off in the gas flame.

In a few cases of middle-ear polypi, it will be found advantageous to apply nitric acid to the base of the growth in the manner just described. Where the base, for example, is unusually broad and firm in texture, nitrate of silver is apt to act rather as a stimulant to further growth, while nitric acid will much more

surely repress the tendency to grow. In these cases, however, *the acid should be applied with great caution.* The firm pressure which it is perfectly proper to use in the case of growths in the external auditory canal, would here be likely to produce a very unpleasant reaction. As regards the employment of such reagents as chromic acid, acid nitrate of mercury, acetic acid, sulphate of copper, etc., for the purpose of checking the growth of granulation-tissue or polypi, my own experience has led me to abandon them all. Acid nitrate of mercury is a very treacherous remedy; it seems to penetrate to a much greater depth than nitrate of silver, or even nitric acid, and is apt to be followed by considerable pain. Chromic acid, in my experience, is also rather treacherous. It should be used only in a fluid state. Absolute alcohol cannot be used properly unless it be made at the same time to bathe all the surrounding healthy tissues. Its effects seem to be superficial and evanescent. In the great majority of cases, pure nitrate of silver, fused upon the end of a cotton-holder or probe in the form of a rounded bead, will be found the most convenient, most efficient, and least painful of all the caustics. Each application should be followed by the mopping process with the cotton-holder, in order that the caustic may not spread beyond the limits of the diseased locality.

Oftentimes a single cauterization will suffice to complete the levelling process begun by the wire snare. In a few cases the snare will be found to have done its work so effectually that the intermediate stage of the treatment—that of cauterization—may be omitted altogether. It should be clearly kept in mind that the caustic is to be used for the express purpose of destroying the superficial portions of the stump of the growth, in order to bring it down to such a level that the surrounding healthy mucous membrane may grow out from all sides over the mass, and so furnish it with a natural covering of mucous membrane.

FIG. 67. — Glass "porte-acid" with platinum cotton-holder passing through its interior. Full size.

That nitrate of silver also exerts a beneficial astringent action,—that it sometimes seems to restrain in a most remarkable manner the tendency to the production of lymphoid elements (pus or tissue-forming cells), cannot be denied by any one who is in the habit of using it much. In a large number of cases, however, it produces the very opposite effects. Hence the desirability of resorting as soon as possible to the use of pure astringents.

The third and last stage of the treatment consists in the application of astringents to the remaining stump of the growth. The parts are to be thoroughly dried with the mop of absorbent cotton, and then powdered burned alum or iodoform (or a mixture of the two) is to be laid upon the dried surface freely but not too thickly. By moistening the end of the slender silver probe and then dipping it into the powder, one can readily take up quite a large mass, which will cling to the end of the probe with sufficient tenacity to enable the physician to transfer it to the desired spot in the middle ear or outer canal. These pellets of powder are to be applied again and again, until the granulating surface is well coated with the remedy. In a few cases I have observed that iodoform (finely powdered) has been able to completely arrest all further growth and all secretion of pus, when the alum had failed to accomplish the desired result. In my hands the iron and tannin preparations have not proved so efficient as the two remedies just mentioned.

If all these efforts fail to arrest the otorrhœa, we may safely draw the conclusion that a carious condition of some portion of the temporal bone (the posterior end of the tympanic cavity, in the majority of the cases), or an undiscovered granulation-growth is the source of the continued discharge. In regard to hidden growths, our best course is to abandon all active treatment and to simply examine the ear at longer intervals (say once in three or four months). After a varying length of time the growth may attain such a size as to encroach upon some visible part of the ear, when it will readily be discovered if the physician examines carefully.

Finally, in a limited number of cases, the external auditory canal is so narrow, or the anterior or lower wall so prominent, that we cannot obtain a view of the spot from which the polypoid springs, although the greater part of the growth can readily be distinguished and easily removed. In these cases we are quite likely to experience defeat, so far as the attainment of a perfect cure is concerned; but the removal of the greater part of the mass will, as a rule, greatly diminish the otorrhœa and oftentimes also improve the hearing, for a period of several weeks or even months.

If I have said nothing about the removal of polypoid growths by means of the galvano-cautery wire, it is simply because I cannot see what advantage is to be gained by the use of this instrument. Blake's snare fully meets all the requirements of the case, and in the matter of simplicity and cheapness it is far superior to the complicated galvano-cautery.

*Foreign Bodies in the Middle Ear.*—As my only experience with this rare condition relates to a case of chronic purulent inflammation of the middle ear, of the proliferative variety, I may with propriety give a detailed account of it in this place.

The patient, a lady about sixty years of age, consulted me on the 24th of March, 1879, for a painful affection of the right ear. According to her statement, she had had a slight discharge from the right ear all her life. About the first of March of that year she noticed that her hearing was more dull than usual, and, at the suggestion of a friend, she consulted a physician. He gave her very little encouragement, but said that she might experience some relief by wearing an artificial drum-membrane, and, with her permission, he introduced one into her ear. As this artificial membrane, however, did not improve her hearing, but, instead, caused her considerable discomfort, he undertook to remove it. Although he failed, as will be seen, to accomplish his object, he in a measure satisfied the patient that the membrane had been removed. From that time forward the ear had grown more and more painful, and she had latterly experienced considerable pain throughout the entire right side of the head. At the time when I saw her she presented the appearance of a person who had passed through a prolonged period of suffering. On examination I found the inner half of the canal filled with a soft polypoid mass, bathed with moderately thick pus. I removed the growth with the snare and found that it sprang from the edge of a moderately large perforation in the drum-membrane. In the centre of the opening I noticed something of a peculiar grayish white color, and on touching it with the probe I discovered that it consisted of some hard material which was firmly lodged in the cavity of the tympanum. By aid of the slender angular forceps I succeeded in extracting this foreign body, which proved to be a rather thick disk of whitish rubber, in the central portion of which was a small hole for the reception of a thread or the end of a slender probe. This circular piece of rubber was of almost precisely the same size and shape as the normal drum-membrane.

After this foreign body had been removed from the middle ear the pain soon disappeared entirely, the discharge became again insignificant, and when I examined the ear, after the lapse of about ten days, I found a perfectly smooth and unirritated drum-membrane, in the centre of which was a circular perforation not more than three millimetres in diameter. No further treatment was advised.

It is difficult to understand how any physician, possessed of his senses, could have deliberately done such a foolish thing as to force a comparatively large disk of rather stiff rubber through an opening in the drum-membrane scarcely three millimetres in diameter. And yet the condition in which I found the ear showed very clearly that the rubber disk had been placed deliberately in the situation where I found it.<sup>1</sup>

### *III. Cases in which the Bone is Involved.*

The pathology of these cases is often difficult to determine. Imprisonment of the pus during the original acute attack is probably, in very many cases, the cause of the carious process in the bone. The imprisoned pus subjects the mucous membrane of

<sup>1</sup> For other instances of the presence of a foreign body in the middle ear see an article by Dr. Huntington Richards entitled "Tympanum, Foreign Bodies in the," in vol. vii., of the Reference Handbook of the Medical Sciences.

the middle ear to great and prolonged pressure, and, as a consequence of the resulting interruption in the circulation, death may take place at one or more points in the membrane. As the mucous membrane, however, is also at the same time a periosteum or nourishing membrane of the bone, the superficial portions of the latter at the points mentioned are also apt to die. This explanation will perhaps often suffice for those limited spots of caries which are so frequently found in the middle ear, but it will scarcely account for the extensive areas of necrosis which are sometimes encountered. In such cases we must assume that other processes, perhaps embolic in their nature,<sup>1</sup> have contributed chiefly to the production of the result in question. Schwartze, in his "Treatise on the Pathological Anatomy of the Ear," mentions the extension of a simple ulcerative process from the mucous membrane to the subjacent bone as one of the common ways in which caries of the middle ear is produced. In the more serious cases, however, of caries or necrosis of some portion of the temporal bone, it will almost invariably be found that retention of pus, and especially of cheesy and decomposing pus, in the tympanum proper or in the mastoid antrum, is in some way connected with the disease of the bone. This danger lurks in every case of chronic purulent inflammation of the middle ear, and is particularly to be dreaded in those cases that are characterized by a small perforation in the drum-membrane, or by one located in Shrapnell's membrane.

The cases that belong in this third subdivision may readily be divided into several smaller groups, in accordance with the differences in the parts involved, in the symptoms manifested, in the issue of the disease, etc.

1. *Superficial Caries, with Unobstructed Outlet for the Discharge.*—In cases of the proliferative variety it is a very common experience to find, in the immediate neighborhood of the mass of granulations, or at the base of the polypoid growth, a spot of exposed and roughened bone. The favorite situations for such spots of bone-caries are the posterior wall of the tympanum, just below the entrance to the antrum, the bony floor of the tympanum, near the posterior end of the cavity, and the ridge of bone separating the middle ear from the external auditory canal. In two cases I found the mucous membrane of the promontory very much thickened (the drum-membrane had been totally destroyed), and on manipulating it with the probe I discovered that, below, it was not continuous with the mucous membrane covering the floor of the tympanum, but ended in a thickened and rounded edge, which could be lifted up like a hanging curtain. The end of the probe, passed beneath the edge of this fleshy cur-

<sup>1</sup> See Trautmann: *Archiv. für Ohrenheilkunde*, XIV., p. 73.



tain, encountered quite an extensive surface of denuded but smooth bone.

In cases that belong to the present group I am not in the habit of modifying my mode of treatment materially. The plan suggested by some authorities, of subjecting the bone at these spots to a thorough scraping with some sharp instrument, does not commend itself at present to my judgment. The principle is undoubtedly sound, but the application of it to a carious spot of unknown depth and extent does not appear to me to be safely practicable. The removal of the granulation-tissue or polypus, as the case may be, the careful daily cleansing of the ear with lukewarm water (with or without the addition of boracic acid), and the judicious application of caustics or astringents to the proliferating mucous membrane, will be found to produce fairly satisfactory results. So long as the outlet is sufficiently free—as it is in cases where the perforation in the drum-membrane is large, or where the membrane is entirely destroyed—this group may be considered as identical, in all essential particulars, with that of the proliferative cases. The chief difference lies in the fact that it is only in exceptional cases that treatment proves successful in completely arresting the discharge.

2. *Caries with more or less Obstructed Outlet for the Discharge.*—Cases belonging to this group are not very numerous, but they furnish a large proportion of the deaths from ear disease. In the present section, however, I propose to consider only the more favorable cases belonging to the group. It is in these alone that we can study quietly the ordinary course of this serious form of disease of the ear. The early stages of the malady can only be inferred from the lesions observed at some later stage of its course. The whole picture, however, points clearly to the lack of proper treatment during the early stages of the acute attack. I will give the details of one or two well-marked cases:

CASE I.—The patient, a strongly built man, thirty-eight years of age, consulted me on the 15th of May, 1874, on account of a very offensive odor which came from his left ear. He stated that he had had scarlet fever during childhood, and that from that time forward, with occasional short intermissions, he had been troubled with a scanty but offensive discharge from the left ear. Inspection revealed the existence of two perforations: one situated in the posterior fold, involving a little of the drum-membrane proper; the other involving only the anterior fold and part of the bony ridge above it. Both perforations partook rather of the nature of fistulous tracks communicating with some more deeply situated centre of disease than of that of simple perforations. In other respects the membrana tympani was a fairly healthy, though much thickened membrane. A little dark-colored and very offensive secretion was found in the neighborhood of the fistulous openings, but elsewhere the parts were quite clean and dry. The edges of the posterior opening were

in a slightly granulating state. As there was no evidence of active local irritation, I advised the patient to douche the affected ear very gently about three times a week, simply for the purpose of removing the foul discharge from the meatus.

On the 30th of March, 1875, the patient came to see me again. He had experienced considerable pain in the left ear during the previous three days. I examined the ear and found the soft parts surrounding the anterior opening red and swollen, and the orifice of the sinus obliterated. Treatment: Two leeches to be applied to the tragus, and the ear to be frequently douched with warm water.

These measures relieved the pain, and the patient was then not seen again until September 9, 1876. He had for a short time previously suffered considerably from dizziness, and the discharge from the ear had increased in quantity. On examination I found the inner end of the meatus occupied by quite a large, two-lobed polypoid growth. I removed it with the wire loop, and found that its peduncle occupied the posterior fistulous opening.

On the 13th I removed a portion of the peduncle with the snare, carrying my wire loop a short distance into the fistulous opening.

On the 16th I succeeded in passing the wire-loop deep down into the fistula, and in cutting off the peduncle at a point probably very close to its actual base. With the porte-acid I then made an instantaneous application of nitric acid to the remaining stump at the bottom of the fistula.

On the 18th I noticed for the first time that a small knob of granulation-tissue, about the size of a No. 3 shot, protruded from the orifice of the anterior opening. By passing the wire loop over the mass as far into the sinus as possible, I succeeded in removing probably the greater part of the growth. I also applied nitric acid to the base of this second growth. The pain following these applications of undiluted nitric acid was insignificant and of only short duration.

On the 20th, and again on the 22d, I succeeded, with Blake's snare, in removing masses of granulation-tissue from the bottom of the posterior sinus. I also discovered that exposed and roughened bone could be reached with the probe in the vicinity of the entrance to the antrum.

On the 25th the patient reported that the discharge from the ear had nearly ceased, and that he was completely relieved of his distressing dizziness.

On the 2d of October I was again obliged to employ the snare in both openings. On the 4th I could discover no trace of granulation-tissue in either fistula. I therefore introduced into them pellets of powdered burned alum. On the 7th and 10th I repeated the applications of burned alum, and then dismissed the patient, as the discharge had practically ceased. I advised him, however, to use the douche faithfully at least three times a week.

On the 4th of January, 1877, he reported that a very slight discharge had persisted since his last visit. On examination I found a small mass of granulation tissue at each of the two orifices. I used the snare in the same manner as on previous occasions, and then introduced powdered iodoform into the openings.

From this time forward patient remained almost free from discharge until shortly before the 14th of July, 1879, when I was obliged again to use the wire snare. (From that time to the present I have not seen the patient.)

CASE II.—The patient, a merchant, thirty years of age and in

good general health, consulted me on the 21st of October, 1878, for an offensive discharge from the left ear. He stated that about four months previously he had experienced severe pain in that ear, and that after the lapse of a few days a discharge had made its appearance and had continued steadily since. At times the discharge had been tinged with blood. On examination I found the left auditory canal noticeably smaller than the right. It contained a moderate amount of brownish, offensive secretion. The membrana tympani was very opaque, but smooth, uninflamed, and possessing, apparently, the normal degree of curvature. Just above and in front of the short process of the hammer there was a small excavation, filled with a dark-colored cheesy material. The tissues immediately surrounding it were red and somewhat swollen. By means of a curved probe I ascertained that this excavation was in reality the outer orifice of a sinus which led inward and a little upward, probably to the upper part of the tympanic cavity. From the appearance of the membrana tympani at that time, and from the subsequent course of the disease, I suspect that the cavity which supplied the pus was shut off from the general cavity of the middle ear by a partition of adventitious tissue or by the prolapsed and thickened mucous membrane belonging to the upper wall of the tympanum. For a short time I made the attempt (by thoroughly cleansing the sinus and by the application of caustics and astringents) to diminish the quantity and the offensiveness of the discharge, but I failed to accomplish this object.

On the 27th of October, 1879, I was sent for by the patient, as he was too ill to leave his bed. He was in considerable suffering, and stated that the pain in the left ear had developed three days previously, and had steadily increased in severity up to that time. Leeches had been applied by his regular medical attendant, but they had afforded only temporary relief. I examined the ear and found that a red, conical swelling occupied the situation of the former excavation, and that from a small opening in the apex of this swelling pus was escaping. Believing that the patient's suffering was largely due to the inadequate size of the outlet for the pus, I made a free incision through the centre of the conical swelling.

I was not sent for again until the 5th of November. The patient then stated that the operation had relieved the severe pain, and had rendered the discharge quite active, but that every day, and especially toward night, he had experienced a dull pain throughout the entire left side of the head. He had also been very much annoyed by dizziness. On examination I found the inner end of the meatus filled with a large, succulent polypoid mass. I removed it with the snare, and found that it grew from the region of the former excavation. I also found, on probing the sinus, that it contained a small fragment of exfoliated bone. On withdrawing the probe I brought to the orifice of the sinus some white cheesy material.

The removal of the polypoid growth afforded considerable relief for a short time, but on the 29th of November he came to see me again, as the pain was steadily increasing. To my surprise, I found the external auditory canal almost filled with a polypoid growth. I removed it thoroughly with the snare.

On the 20th of December I found the condition of the ear materially changed. The polypoid growth had not reappeared, but equivalent changes had taken place in the cavity of the tym-

panum. The drum-membrane appeared to have become amalgamated with an intra-tympanic growth, which had already attained such dimensions that the visible background, at the bottom of the meatus, appeared like a solid, rounded mass of flesh. There was nothing in the appearance of the mass to remind one that its outer portion, at least, consisted of the membrana tympani. At one spot, near the floor of the canal, this otherwise tough-looking mass appeared to be granulating, and on pressing my probe against the spot it passed readily inward to a distance of about one-third of an inch. The dizziness and pain still persisted, and the patient was unable to attend to business.

On the 10th of January, 1880, I removed with the snare a rather large polypoid mass which sprang by a slender peduncle from the lower part of the drum-membrane. Since the 20th of December a very noticeable change had taken place in the condition of these deeper parts. The membrana tympani still occupied an unnatural position, but it was evident that the intra-tympanic growth had diminished very decidedly in size, as the membrane then protruded only to a moderate degree.

On the 10th of February the patient reported that he was almost entirely free from dizziness and pain in the head, and that the discharge had greatly diminished in quantity. On examination, I found everything restored to the state in which I had found the ear in October, 1878. The drum-membrane was entire and occupied a very nearly natural position; no granulating surface was anywhere to be seen; in a word, the only difference that I could discover was a slight enlargement of the orifice of the sinus—and of this, even, I could not be positively certain.

The preceding cases suggest two points with regard to which I should perhaps say a word or two. In the first place, in both of these cases marked dizziness was a prominent symptom, and in both it seemed to depend upon increased intratympanic pressure. In these cases, therefore, of caries with obstructed outlet for the pus, we should make use of this symptom as a measure of the degree of obstruction that exists, and as an indication that we should interfere for the purpose of re-establishing a free outlet. In the second place, the obstacles that stand in the way of a successful treatment of this pathological condition are very great. As a rule, we are obliged to rest satisfied with only partial success.<sup>1</sup> The persistent and systematic use of the douche with warm water constitutes the most efficient, and sometimes the only practicable, plan of treatment.

3. *Extensive Caries or Necrosis of the Temporal Bone.*—The few cases of this nature that I have seen came under my observation for the first time only after the damage had been done. I am therefore unable to throw any light upon their pathology, but can simply record the nature and extent of the damage found

<sup>1</sup> For further information with regard to these perforations in the region of Shrapnell's membrane, consult the articles by Blake and Burnett, in the Transactions of the American Otological Society for 1874; and one by Miller, in the volume for 1878.

at the time of my examination. Thus, for example, in the case of a boy, seventeen years of age, I found all that part of the squamous portion of the temporal bone which separates the upper part of the tympanic cavity from the external auditory canal, destroyed. The anterior and posterior folds were still intact, and so was the drum-membrane proper. The head of the hammer, however, with the exception of only its extreme upper portion, stood out prominently in the centre of the irregularly shaped excavation. In a second case the anterior and posterior folds formed the dividing ridge between two *cysts-de-sac*, the upper one being formed by a carious excavation in the bone situated in front of the head and neck of the hammer, the lower one consisting of the exposed cavity of the tympanum. In a third case the membrana tympani, the hammer and anvil, the anterior and posterior folds, and a large part of the bone situated above the drum-membrane, had all been destroyed. The appearance presented to the eye of the observer was as if the external meatus terminated in quite a cavern. Notwithstanding this extensive destruction of the parts, the hearing-power of that ear remained fairly good. In a fourth case I extracted quite a large mass of bone from the external auditory canal, and, on examining it, I found it to consist of the larger part of the cell-structure of the mastoid process. I have never seen a case of necrosis and casting-off of the labyrinthine portions of the petrous bone, but many such have been reported.<sup>1</sup> There is even a case on record<sup>2</sup> where almost the entire temporal bone was cast off, as the result of necrosis.

4. *Desquamative Processes*.—Under ordinary circumstances the inflamed mucous membrane of the middle ear casts off pus, mucopus, or a simple serous fluid. Under certain conditions, however, it casts off, in addition to these elements, layer upon layer of flattened or pavement epithelium. These layers, as a rule, are not floated out of the ear with the fluid portions of the products of inflammation, but show a disposition to adhere to each other and to the subjacent living tissues, thus forming laminated masses of epithelium which sometimes attain very large proportions. The laws governing the development of this desquamative process are not known. It is very commonly found associated with carious processes in the tympanum, mastoid antrum, or mastoid cells, but it is not always clear whether the irritating effects of the caries have called forth the desquamative process, or whether the pressure of the constantly growing mass of cast-

<sup>1</sup> For instance, by Toynee; by Schwartz (A. f. O. IX., p. 278); by Dennert (op. cit., X., p. 231 and XIII., p. 19); by Luca (ibidem, p. 236); by Agnew (American Med. Times, vol. vi., No. 10); by Pomeroy (Transactions of the American Otological Society, 1872), and by Spencer (Transactions Missouri Medical Association, 1875).

<sup>2</sup> Dr. J. Gottstein: Archiv. für Ohrenheilkunde, XVI. Bd., Erstes und Zweites Heft.

off epithelium has produced the caries. In exceptional cases we may encounter such laminated masses of epithelium in a middle ear which presents no evidence of being the seat of a carious process. Thus, for example, in February, 1878, I was consulted by a gentleman, who stated that since boyhood he had been affected with occasional but very slight discharge from both ears. On examination I found in the left ear a fistulous opening in the anterior fold, and a small perforation in the posterior inferior quadrant. In the right ear I found a little watery secretion in the meatus, and an opaque and tough-looking membrana tympani, which at first sight appeared to be entire. On more careful inspection, however, I discovered a linear, slit-shaped perforation, perhaps two millimetres in length, running parallel with and close to the posterior periphery of the membrane. When the patient performed Valsalva's experiment, the entire drum-membrane yielded to the pressure from within, just as an unbroken membrane would. From this behavior of the membrane I inferred that either a mass of mucus or a polypoid growth, acting like a valve, prevented the air from escaping through the perforation. I accordingly enlarged the opening in the membrana tympani by making two incisions, one at each end of the perforation and at right angles to it. By these incisions I converted one lip of the opening into a rectangular flap, and so secured a broad outlet. Inflation by Politzer's method was then resorted to, and as a result a whitish mass, three-eighths of an inch long, two-eighths of an inch broad, and about one millimetre in thickness, was driven out into the external auditory canal. Under the microscope small fragments of this mass were found to consist solely of flattened epithelium (non-nucleated). The removal of this large mass from the cavity of the tympanum gave the patient marked relief from an annoying sense of fulness in the ear, and also materially improved his hearing, but did not arrest the discharge. The patient remained under observation for about four days, and was then obliged to return to his home in Ohio.

It is a more common experience to find the laminated mass of epithelium filling the cavity of the tympanum, or at least its upper portion, as in the following case:

CASE I.—The patient, a lady about thirty years of age, consulted me on the 23d of November, 1878, for a painful affection of the left ear. According to her story she had had a discharge from this ear since girlhood, though not constantly. Recently, however, the discharge had become quite active, and she had suffered from a steady, dull pain, which seemed to be most acute in the neighborhood of the mastoid process. Her head had also felt heavy and full. After removing two polypoid growths, which obscured the view of the deeper parts, I discovered that quite a large mass of tough, laminated epithelium filled the entire cavity

of the tympanum. By dissecting the edges carefully I was able to loosen it and remove it as a single tough, leathery mass. A considerable portion of the bony ridge situated just above the drum-membrane had been destroyed, and the larger part of the epithelial plug was located in the excavation which remained. The polypoid growths sprang from the outer margin of this same excavation. The relief which the removal of this tightly fitting mass afforded the patient was apparently very great.

On the 27th of December the patient returned to the city and reported that she had carried out my instructions (simply to douche the ear daily with lukewarm water) faithfully, and that as a result the discharge had ceased entirely since the middle of the month. The pain and sense of discomfort in the head had also entirely disappeared. I examined the ear and found the parts perfectly clean and pale, with no signs at any point of a tendency to develop granulation-tissue.

The preceding case may be taken as a fair type of these not very rare cases. If one can judge correctly from the published reports of many of the best authorities, the mastoid antrum is the most frequent starting-point of such desquamative processes.<sup>1</sup> Marked variations from the type described above, however, are occasionally encountered. As an instance of such an exceptional course of the disease, I will narrate the following case:

CASE II.—The patient, a strong, healthy man, twenty-five years of age, had been subject to frequent earaches and to an occasional discharge from both ears since childhood. During the last three weeks of September, 1875, he had experienced constant pain in the left ear. When I examined his ear on the 1st of October, 1875, I found the external auditory canal blocked up with a red, fleshy mass, which sprang from the upper wall of the canal. The most prominent portion, which looked like ordinary granulation-tissue, was removed with the snare, and then it was ascertained that the fleshy mass which blocked the entrance of the external auditory canal was really the prolapsed upper cutaneous wall, in which an opening had established itself. A probe introduced into this opening could readily be passed in to a distance of fully three-fifths of an inch, without encountering at any point denuded bone. Considerable cheesy and very foul pus was removed from the contracted meatus, but no view could be obtained of the deeper parts, owing to the fact that the prolapse of the upper cutaneous wall of the canal extended inward as far, apparently, as to the immediate vicinity of the membrana tympani. As this prolapsed portion could not be lifted back to its natural position, it was evident that some substance (cheesy pus, as I supposed) had accumulated between it and the bony wall. For its removal I adapted a slender nozzle (diam.  $1\frac{1}{2}$  mm.) to an ordinary hard-rubber ear-syringe, interposing between it and the nozzle of the syringe a short bit of rubber tubing. This slender nozzle was introduced without any difficulty into the mouth of the sinus, and upon forcing in the warm water it was found that the greater part of it returned by the side of the nozzle, while the

<sup>1</sup> Consult Von Troeltsch (Arch. f. Ohr., IV., p. 105); Toynbee (Medico-chirurg. Trans., vol. xlv.); Lucas (A. f. O., VII., p. 255); Duncanson (Edinb. Med. Jour., Nov., 1877); Matthewson (Trans. Amer. Otol. Soc., 1878); Moor (Archives of Ophthalm. and Otol., III., No. 2), and Kipp (Archives of Ophthalm. and Otol.).

rest made its way through the sinus into the deeper parts of the ear, whence it escaped through the meatus proper. This procedure caused the patient not a little pain, and consequently could be repeated only a few times at a sitting. The first time (October 2d) almost nothing was brought away by the syringing, but on subsequent days the stream of water regularly brought away fragments of epithelial laminae of the most perfect whiteness. The bent forceps was also frequently used in dislodging the larger masses, which were too large to pass through the orifice of the sinus except with the aid of some tractile force. On October 10th (the syringe having been used daily in the meantime) the last fragment was dislodged. The total amount of epithelium removed was sufficient to fill a two-drachm bottle (no force being used to pack the substance into small compass). A microscopic examination revealed the presence of a few crystals of cholesterine in addition to the lamellae of large, polygonal, perfectly transparent, sharply outlined epithelial cells. From day to day, as the accumulation of epithelium became reduced in quantity, the calibre of the external auditory canal grew steadily larger, until, on the 11th of October, I was able to ascertain quite accurately by inspection the condition of the middle ear and deeper portion of the meatus. There was at the same time a very perceptible improvement in the hearing. After the last mass of epithelium had been removed, the probe introduced into the sinus encountered roughened bone surface at the point where the posterior wall of the meatus becomes the outer surface of the mastoid process. Farther inward, however, the end of the probe passed over a series of small, smooth hummocks, which conveyed to my mind the impression of being the exposed septa of the mastoid cells (the solid bone composing the posterior and upper wall of the meatus having been destroyed by caries,—or possibly by pressure). At the farther end of the sinus, and encroaching slightly upon the posterior fold, was a second opening (in the cutaneous wall), which communicated with the inner end of the meatus, and was fringed like the outer one with granulation-tissue. Upon the removal of the granulations with the snare, the membrana tympani could be seen. It was still entire, but amalgamated at almost every point with the tissues of the inner wall of the tympanum. In the posterior upper portion, and in one or two places below, the membrane was still free. There was no swelling or tenderness over the left mastoid process. (I can give no further details in regard to the progress of this case, as the patient soon afterward passed from under my observation.)

It is not easy to build up any theory that will satisfactorily explain all the aspects of this unusual case. Originally there was probably a severe inflammation of the middle ear, which, not finding a free escape for its products through the membrana tympani,—that membrane probably being more resistant than usual,—extended to the mastoid cells. From this resulted in course of time a caries of that portion of the mastoid process which forms the posterior and upper wall of the external auditory canal. A fistulous opening then established itself in the cutaneous wall of the canal, and, as it was of small size and probably from time to time became closed for a short time, the accumulating pus from



the carious region must have dissected a way for itself in the direction of least resistance, that is, inward toward the posterior fold. At this point, too, the cutaneous wall is thinnest, and here it was that a second opening established itself. As the mastoid cells were found to be exposed over quite an extent, without at the same time being carious, a condition which I will not venture to explain, it is fair to assume that the immense mass of epithelium found in this situation must have been cast off from the mucous membrane lining these cells, cheesy and foul pus having originally supplied the necessary irritating stimulus.

5. *Extension of the Ulcerative Process to Neighboring Organs.*—If we leave out of consideration for the present those cases in which the brain and its membranes and the lateral sinus are invaded by the disease, there still remain those cases in which



FIG. 68.—Cyst-Like Protrusion of the Upper Posterior Quadrant of the Right Membrana Tympani. (After Politzer.)

the chorda tympani nerve, the facial nerve, and the carotid artery become affected. With the exception of a few cases of facial paralysis, the various conditions which I have just enumerated have never come under my immediate observation, and I am therefore unable to give any information based upon personal experience. Cases of fatal hæmorrhage from the carotid artery, dependent upon caries of the temporal bone, will be found in Marcé's monograph on this subject.<sup>1</sup> The only instance that I can recall of an affection of

the chorda tympani nerve occurring in the course of a chronic purulent inflammation of the middle ear, is that reported by Noyes.<sup>2</sup>

6. *Cyst-like Tumors of the Drum-Membrane.*—I can find in my records but six cases of well-defined cysts of the membrana tympani. In four of them there had previously existed a purulent inflammation of the middle ear. In one of these four cases, which I reported in detail, in 1872,<sup>3</sup> the cyst seemed to have formed between the layers of the drum-membrane. In the other three cases, however, the cyst-like tumor consisted of the posterior half of the drum-membrane, which, having lost its substantia propria through the prolonged pressure of the exudation in the tympanic cavity, had no longer been able to resist that pressure, and so gradually became converted into an elastic diverticulum. A case of this kind is pictured in Politzer's work (see Fig. 68.) In acute cases I have frequently observed, during convalescence, a

<sup>1</sup> Marcé: De l'ulcération de la carotide interne dans la carie du rocher. Paris, 1874. See also a case reported by Hermann (A. f. O., IV., p. 294).

<sup>2</sup> Transactions of the American Otological Society, 1874.

<sup>3</sup> In the Medical Record of November or December of that year.

very marked pouting of the membrane in the immediate vicinity of the perforation; and in one case, which is now under my care, I found on returning to the city, after an absence of a week, that the simple pouting of the membrane had developed into a well-defined, almost pedunculate cyst, fully three millimetres in diameter. A minute perforation still existed, but it was so inadequate, as an outlet for the purulent secretion, that the neighboring parts were kept in a constant state of tension.

In the remaining two cases the cysts were of quite a different nature. One of them occupied the very centre of the drum-membrane and measured nearly three millimetres in diameter. It was also somewhat flattened, as if a portion of the fluid contents had been absorbed.

The other cyst occupied the lower two-thirds of the posterior half of the membrane. It had evidently originated at the upper part of the membrane, and had, as it increased in size, dissected its way down to the lower part. Both of these cysts contained apparently pure serum, unmixed with blood. Both occupied spaces which they had made for themselves between the substantia propria and the outer dermoid layer. Both seemed to have originated in a subacute congestion of the middle ear, which had run its course, however, without causing any appreciable exudation in the tympanic cavity. After the contents had been evacuated, both cysts soon disappeared completely.

So far as the size of these tympanic cysts is concerned, the largest that I have seen was so large as to completely conceal all the remaining half of the drum-membrane; that is, it was as large as a medium-sized pea. In every case but one the posterior half of the drum-membrane alone was involved. Finally, in one of the four cases first described I was surprised to find that there was quite a large perforation in the anterior half of the membrana tympani, and that pus escaped freely through it. To explain this condition of things satisfactorily, one must assume that inflammatory adhesions had at some previous time shut off the posterior from the anterior half of the tympanic cavity, perhaps not entirely, but at least to such an extent as to keep the fluid contents of the posterior half under great pressure.

So far as the treatment is concerned, the most urgent indication, in the case of cysts that communicate with the middle ear, is to establish a very free opening in the diverticulum, and then to treat the case in the same way as we should a simple case of purulent inflammation of the middle ear.

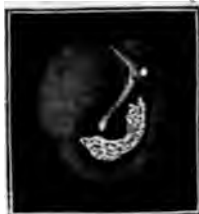

FIG. 60.—Crescent-shaped Deposit of Calcareous Material in the Anterior Lower Quadrant. (After Politzer.)

7. *Deformities caused by both the Acute and the Chronic Forms of Purulent Inflammation of the Middle Ear.*—Even the very worst cases of purulent inflammation of the middle ear will often

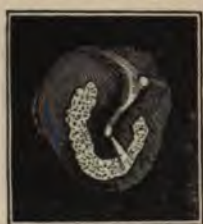

FIG. 70.—Horseshoe-shaped Deposit of Calcareous Material. (After Politzer.)

heal, and cease thereafter to give the patient any annoyance beyond that caused by the impairment of his hearing. This symptom, however, often brings such patients to the physician's office, and in this way we get opportunities of seeing a great variety of deformities. It would require considerable space to give anything like a full list of the numerous pathological pictures presented by the cases that belong in this category. I will therefore simply allude briefly to some of the more important ones.

*Calcareous deposits* in the drum-membrane furnish good evidence that the middle ear has at some previous time been the seat of a purulent inflammation. During the course of this inflammation aggregations of pus-cells are deposited between the layers of the membrana tympani, and in this position undergo, first cheesy, and then calcareous degeneration. According to the original distribution of the pus-cells there will ultimately be developed either a plate of calcareous material or a series of small calcareous spots. I have seen almost the entire area of the drum-membrane occupied by one or more calcareous plates. Of themselves these chalky deposits in the drum-membrane exert very little influence upon the acuteness of the hearing. I have seen extensive chalky patches in the drum-membranes of individuals whose hearing was very acute. Their chief value lies in the evidence which they afford of a previous purulent inflammation of the middle ear, and also in the light which they throw upon the nature of the lesions underlying certain cases of marked deafness. Such calcareous deposits have been found, post-mortem, in the neighborhood of the stapedio-vestibular joint, a location where they may produce a high degree of disturbance in the mechanism of hearing. During a patient's lifetime we cannot inspect this particular region; but if we find calcareous plates in the membrana tympani of a very deaf individual, would it not be natural to infer—in the absence of other satisfactory causes—that a similar chalky material has been deposited in the tissues surrounding the foot-plate of the stirrup?



FIG. 71.—Calcareous Thickening of the Margin of a Large Perforation. (After Politzer.)

*A tough and thickened drum-membrane* is sometimes left as a

permanent sequela of an otitis media purulenta of long standing. Taken by itself, such a thickening of the drum-membrane cannot very greatly impair the power of hearing. As an evidence, however, of a general thickening of the mucous membrane lining the middle ear, it must be considered as an important lesion.<sup>1</sup>

*Cicatrices*, or incomplete reproductions of the drum-membrane substance (as represented by its three essential layers), are very common. They are usually round, oval, or kidney-shaped, but they may also have other shapes. They are, as a rule, smooth, extremely thin, and transparent, and yield to pressure as if they were made of rubber. In a few cases we find the cicatrix in a crumpled condition, as if it had been unduly stretched. Anatomically such

cicatrices consist of the dermoid layer on the side toward the meatus, and of a continuation of the epithelial layer which constitutes the free surface of the tympanic mucous membrane. Between these will be found some elastic fibres and a few capillary blood-vessels, but probably no nerves. The significance of the existence of such cicatricial spots in the drum-membrane is simply this: they afford strong, if not absolutely positive, proof that at some previous time the middle ear has been inflamed, and that, as a result of such inflammation, a perforation of the same size as the cicatricial spot was established in the membrana tympani. After inflation, these cicatrices, unless the Eustachian tube happen to be unusually pervious to air,

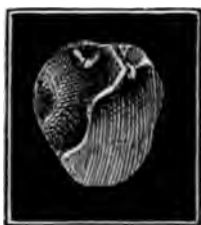

FIG. 79.—Depressed Cicatrix resting upon the Inner Wall of Tympanic Cavity and showing the Stapedio-Incudal Joint. (After Politzer.)

will be found to present a totally different appearance. In the place of a flat, or, more commonly, a concave, smooth, transparent surface, we shall see a tense, slightly opaque, hemispherical or tomato-shaped blebs, which in the course of a few minutes usually returns to its former flat or concave state. More than once I have ruptured such cicatricial reproductions of the membrana tympani, and have in the majority of instances seen no harmful results from such a rupture. In one case, however, the inflation produced pain and some impairment of the hearing. I must therefore dissent from the views expressed by Politzer in 1868.<sup>2</sup> I believe it is better to avoid rupturing these cicatricial portions, and especially such as are found lying against the mucous membrane of the promontory. In these particular cases there is some likelihood that adhesions may have formed between the cicatrix and the mucous membrane, and forcible inflation under such

<sup>1</sup> Urbantschitsch (Archiv. f. Ohrenheilkunde, X., p. 7) describes peculiar pearl-like thickenings of the epithelium of the drum-membrane.

<sup>2</sup> Wiener med. Presse, 1868.

circumstances is quite sure not merely to rupture the adhesions (which may in certain cases be a desirable thing), but also to tear the mucous membrane and cause hæmorrhage (which in the middle ear is never a desirable thing).

So far as the size of these cicatricial reproductions of the membrana tympani is concerned, I may say that in this respect there is practically no limit to the reproductive powers of the membrane. The substantia propria, it is true, seems to possess extremely little regenerative power. On the other hand, the dermoid and mucous surfaces possess this power to an amazing extent. In one of my cases exactly one-half of the drum was cicatricial, *viz.*, the posterior half. The dividing line between the original membrane and that which had been reproduced was very sharply drawn. The elastic nature of this cicatricial half manifested itself in a striking manner when I made an incision in it,—the lips of the wound instantly gaping widely apart as the tissues were divided. In four other cases there was very clear evidence that the drum-membrane had been entirely reproduced. I will describe each of these cases in brief outlines.

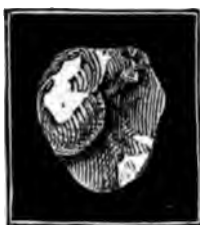

FIG. 73.—Same Drum-membrane, immediately after Inflation of the Middle Ear. (After Politzer.)

**CASE I.**—The patient, a boy about twelve years of age, consulted me at the New York Eye and Ear Infirmary, on the 3d of May, 1871, for a slight general impairment of his hearing. On questioning him, I ascertained that from early childhood up to a recent date he had been subject to a discharge from both ears. On examination I found the left auditory canal normal. At the inner end of the canal the picture presented to the eye was as if the membrana tympani had been destroyed. On closer inspection, however, I discovered that a very thin membranous structure dipped directly inward from the annulus tympanicus, and applied itself closely to all the irregularities of surface of the inner wall of the tympanum. The tip of the handle of the hammer was firmly bound down to the tissues of the promontory. Behind it the long process of the anvil and the posterior arch of the stirrup were seen standing out in relief, but from their peculiar glistening aspect it was evident that they too were covered with the cicatricial membrane.

**CASE II.**—The patient, a girl ten years of age, was brought by her mother to the Infirmary on the 23d of August, 1871. The history given was this: Five years previously the child had contracted a double otorrhœa, which lasted without interruption for about two years and then gradually ceased, leaving her with a moderate degree of deafness. On examination I found that the posterior half of the right drum-membrane consisted entirely of cicatricial tissue, while on the left side the appearances presented were almost precisely the same as those observed in the preceding case.

In regard to both of the preceding cases the objection may be

raised that the thin membranous structures, which I have described as reproduced drum-membranes, may have been in reality atrophied drum-membranes, which, through some intercurrent inflammatory action, had contracted adhesions with the inner wall of the tympanum. I admit the possibility of such a series of pathological changes, and I also admit the fact that an atrophied drum-membrane may present to the naked eye precisely the same appearances as a newly-produced membrane. I think, however, that of the two hypotheses mine is the more probable; especially if we take into consideration the previous history of each of these cases, and if we remember that the reproduction of a substitute for a drum-membrane that has been entirely destroyed is now a well-established fact.<sup>1</sup> In the following two cases the evidence is certainly conclusive.

CASE III.—The patient, a strong healthy boy, eight years of age, was brought to see me on the 3d of October, 1872. The history which his mother gave was this: Three or four years previously he had passed through an attack of scarlet fever, which left him with a discharge from the left ear, which had continued ever since. I examined the ear and found that the drum-membrane had been entirely destroyed, and that from the posterior and upper part of the tympanum a pedunculate growth sprang which partially filled the inner end of the meatus. I removed this growth with the snare, and treated the thickened spot of mucous membrane from which it grew, first with pure nitrate of silver (in the form of a bead), and afterward with powdered burned alum. The right ear was perfectly normal.

On the 24th of October, the discharge having ceased and there being no evidence of a return of the growth, I dismissed the boy from active treatment.

On the 19th of January, 1880, I had an opportunity of examining the patient's left ear again. He said that he had remained perfectly free from a discharge since 1872, and that the ear had given him no trouble beyond that due to the slight impairment of the hearing. To my surprise I found that a thin, dermoid membrane had grown from the rim that remained of the original membrane, and followed the inequalities of the inner wall of the tympanum in much the same manner as was observed in the preceding cases.

CASE IV.—The patient, a boy fifteen years of age, came to the New York Eye and Ear Infirmary on the 27th of May, 1874. He stated that two years previously he had had scarlet fever, and that it was followed by a discharge from both ears, which had continued without intermission up to that time. On examination I found the right external auditory canal filled with pus. I cleaned the parts thoroughly, and then ascertained that the drum-membrane had been destroyed, and that the mucous membrane of the tympanic cavity was almost everywhere in a granulating condition. No effort had been made to keep the deeper parts of the ear clean, and as a result the purulent secretion had become highly offensive, and was undoubtedly extremely irri-

<sup>1</sup> See the report of such a case by Dr. H. N. Spencer, of St. Louis, in the Transactions of the American Otological Society for the year 1871.

tating to the mucous membrane of the middle ear. I saw the patient at irregular intervals and treated the case in the usual way. It was not, however, until during the latter part of October of that year that I finally succeeded in arresting the tendency, on the part of one or two spots in the mucous membrane of the middle ear, to develop granulation-tissue.

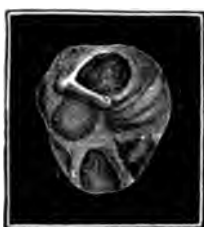

FIG. 74.—Cicatricial Retractions and Band-like Thickenings in the Membrana Tympani. (After Politzer.)

and opposite the mouth of the Eustachian tube, as a tense, creased membrane."

*False membranes* or *bands of adhesions* are often encountered in the middle ear. They must be considered as sequelæ of an acute or chronic inflammation (generally purulent in character) of the middle ear. I will select a few examples of this pathological condition from my case-books. In one case the description reads thus: "The drum-membrane is entirely destroyed, with the exception of a narrow rim at the periphery. The hammer is drawn out of position, so that the neck and a part of the head are visible. Its handle is bound down to the long process of the anvil by adhesions." In a second case I found "a strong, isolated fibrous band running from the lower part of the tympanic ring (the posterior half of the membrane having been destroyed) to (possibly) the head of the stirrup." In a third case a band ran from the centre of the handle of the hammer forward and a little downward to some point in the vicinity of the mouth of the Eustachian tube. In a fourth case the drum-membrane was found either to have undergone a high degree of atrophy or to have been replaced by a cicatricial membrane, through which was distinctly seen a whitish band running almost directly upward from the tip of the handle

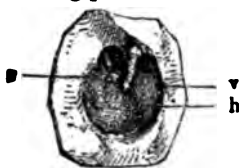

FIG. 75.—Large loss of Substance of Right Membrana Tympani, with Formation of an Adherent Cicatrix. v, Thickened anterior remains of membrane fast to promontory; a, stapes-head with an opening above it leading into the attic of the tympanum. The Eustachian tube is wholly shut off from communication with the major part of the tympanic cavity. (After Politzer.)

of the hammer to the region of the stapedio-ineudal joint. In a fifth case the rigidity of the handle of the hammer, as ascertained by pressing upon it with the end of the probe, justified the as-

sumption that the high degree of deafness which existed in this case was probably due to a similar ankylosis of the other joints, and particularly of the stapedio-vestibular joint. In a sixth case I found the hammer drawn completely out of its natural position and bound down by firm adhesions to the anterior wall of the auditory canal, or, at all events, to the anterior edge of the annulus tympanicus. Finally, in a seventh case I found one of the larger ossicles similarly bound down to the upper and posterior wall of the canal. It was so enveloped in firm cicatricial tissue that I was unable to distinguish accurately which of the two ossicles it was.



FIG. 76.—Schematic Section of the External Auditory Canal and Middle Ear of the preceding case. (After Politzer.)

The deformities which I have just enumerated are comparatively rare. Much more common are those adhesions which bind the handle of the hammer, or the drum-membrane, or both, to the opposite promontory. In comparatively recent times attempts have been made, and occasionally with measurable success, to sever adhesions which interfere with the power of hearing. In Fig. 77, which shows the handle of the hammer bound down to the head of the stirrup in a manner calculated to interfere seriously with the hearing, a short, straight black line indicates where Prof. Politzer divided the attachments between these two ossicles. The result, in this instance, proved to be unexpectedly good. It has not been my good fortune to see more than two or three cases in which, after careful consideration of the attendant risk and the possible benefit, I felt justified in advocating operative interference. In only one of these was an operation actually performed, and the results in this single instance did not encourage me to repeat the experiment at an early day.

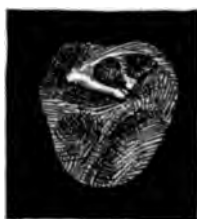

FIG. 77.—The Handle of the Hammer bound down firmly to the Head of the Stirrup. Division of the adhesions produced marked improvement of hearing. (After Politzer.)

Perforations are found in the membrana tympani of all sizes and shapes, and in every conceivable part of the membrane. Double perforations in the drum-membrane proper are by no means common. In one of my cases the two perforations occupied the lower half of the membrane. In two other cases two small perforations were found, one in the anterior inferior quadrant, the other in the posterior inferior quadrant. In the fourth case my notes

read as follows: "All that remains of the drum-membrane is a narrow bridge of tissues stretching from the tip of the handle of the hammer to the opposite portion of the sulcus tym-



panicus." Instances are on record of three, four and even five perforations in the membrana tympani. (See Figs. 80 and 81.)

Finally, in the category of deformities, I might mention the *destruction or expulsion of the ossicles*.

—It is a very common experience to find the handle of the hammer reduced to a mere knob in the vicinity of the short process. If the hammer has disappeared, we may be very confident that the anvil has gone with it; for when the anvil loses the support of the hammer, it becomes a mere dangling body, having only two remaining supports and those comparatively feeble (the stapedio-incudal and the tympano-incudal articular ligaments). Unless extensive caries or necrosis of the petrous portion of the temporal bone exists, the stirrup seems to be able to maintain its position firmly in the fenestra ovalis. When it goes, or, rather, when its foot-plate goes, the hearing-power also vanishes. This, at least, must be the rule, but that exceptions may occur will appear from the facts developed in the following case:

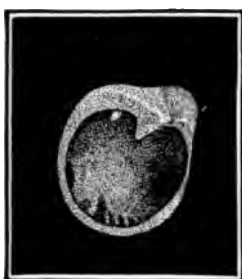

FIG. 78.—Right Ear of a Boy, Eight Years of Age, with a long-standing Suppurative Otitis after scarlatina. The membrane is extensively destroyed, leaving but a narrow margin all around, except where a triangular portion remains along the retracted manubrium. The tip of the incus process is just visible posteriorly, the niche of the round window appears behind, and the irregular depressions of the floor of the tympanum below. Anteriorly, we look into the Eustachian tube as far as to the isthmus. (After Randall.)

The patient, a well-known physician in this city, about forty-five years of age and very deaf, consulted me on the 17th of October, 1879, on account of a very distressing tinnitus. He said that during boyhood he had been subject to a discharge from both ears, and that on one occasion his mother had discovered in the discharge from the right ear the stirrup, in a perfect state of preservation. She put it into a box and kept it as a curiosity. The doctor had himself seen this ossicle as recently as during 1877, and was positive that it was the stirrup and not one of the other ossicles. During recent years he had been entirely free from discharge, and at times heard fairly well. I tested his hearing and found that words loudly spoken were heard about equally well in both ears. The sound of the tuning-fork, when placed upon the forehead, was referred by the patient to that region, and not to either ear; when held near the ear, it was heard by him at a distance of about four inches, in both ears. Every trace of the drum-membrane, hammer, and anvil had vanished from both ears, and a thick and pale (fibrous) cicatricial tissue covered the entire background, the only decided depression being a niche at the tympanic orifice of the Eustachian tube.

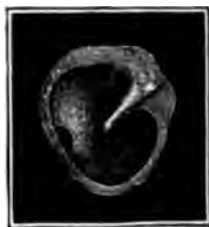

FIG. 79.—Another Large Perforation. (After Politzer.)

This is the only instance that I have met with in which the evidence was fairly conclusive that the expulsion of this most important ossicle had not wholly deprived the patient of the hearing-power in the ear thus maimed. Nature, we may assume, had in this instance probably provided a fibrous substitute for the foot-plate of the stirrup before the actual separation and expulsion of the ossicle took place.

The question of *treatment* of these deformities of the middle ear may be dismissed in a very few words. Excision of the hammer, and attempts to render it mobile by the employment of a certain degree of force in cases where this ossicle has acquired a rigid, immovable position, do not commend themselves to my judgment. Operative interference in cases of adhesions between the membrana tympani and the mucous membrane of the promontory, or between the ossicles and some portion of the tympanum, may possibly in certain cases accomplish some good; but, as already stated, I have only encountered one case in which I felt in the slightest degree encouraged to undertake such opera-

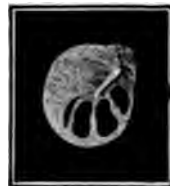

FIG. 80.—Right Membrana Tympani of a Man about Fifty Years of Age, showing Four Perforations in the Lower Portion. The narrow, most posterior opening, closed under observation. (After Randall.)

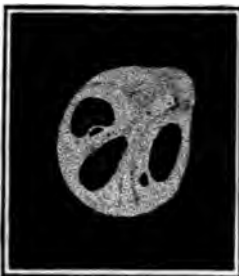

FIG. 81.—Right Membrana Tympani of a Man, Forty Years of Age, who died about a year later of Tuberculosis. An oval perforation occupies the anterior portion of the membrane, a more pear-shaped one is down and back from the umbo, and a third of kidney-shape is up and back. Two small and elongated openings are close to the first and the third. The membrane shows plications below the umbo. (After Randall.)

tive interference. In cases of simple perforation of the drum-membrane, where the discharge has ceased, I never make any attempt to cause the healing over of the opening by a cicatricial membrane, the gain which might result therefrom being altogether too insignificant. There is one point, however, which should be borne in mind with regard to these cases of simple perforation. I refer to the harm which sometimes comes from the introduction of water into the external auditory canal. It is almost sure to find its way into the tympanic cavity, and—the tympanic mucous membrane being in a comparatively healthy state—its presence there is apt to give rise to considerable irritation, and perhaps even to re-establish a subacute purulent inflammation of these parts.

The removal of impacted cerumen from the external auditory canal by means of the syringe, may, in cases such as we are considering, result in the production of an evil which in its turn may require considerable treatment. In

cases, therefore, in which there are good grounds for suspecting the existence of a perforation in the drum-membrane (without otorrhœa), the syringe should not be used, if we can possibly dispense with it. The patient should also be cautioned about bathing in either salt or fresh water, without first protecting the affected ear against the entrance of water.

So far as the symptom of deafness is concerned, a certain degree of relief may be obtained, in a few cases, by the wearing of Toyn-



FIG. 82.—Toynbee's Artificial Drum Membrane. (After Moos.)

bee's *artificial drum-membrane*. I have never seen more than four or five cases in which this contrivance, or some substitute for it, materially increased the acuteness of the patient's hearing. At the same time I must confess that my lack of faith in its efficacy has led me to test its virtues in comparatively few cases. Furthermore, the presence of such a foreign body in the meatus, and in close contact with the drum-membrane, or with the stump of the manubrium mallei, is very annoying to the great majority of patients.

## CHAPTER XI.

### FRACTURES OF THE TEMPORAL BONE.

THE subject of fractures of the temporal bone belongs chiefly to the domain of general surgery, and yet the participation of the organ of hearing in the damage inflicted brings it also very properly among the topics which should be discussed in a treatise on the diseases of the ear. The so-called "fractures at the base of the skull" probably always involve the temporal bone. These cases do not often come under the observation of the aural surgeon, and the medical man first called to see the case probably never thinks of making an examination (with the speculum and reflected light) of the external auditory canal and drum-membrane. Hence our supply of facts with regard to the lesions demonstrable during life in the temporal bone of a person who is believed to have a fracture at the base of the skull, is very scanty. It is sufficient, however, to justify the following deductions.

Fractures of the temporal bone may be subdivided into two classes:

1. Fracture or diastasis of the tympanic or squamous portion, in the region of the middle ear, without implication of the pars petrosa.

2. Fracture of both the tympanic and the petrous portions.

Both of these kinds of fracture are produced, not by direct violence to the parts, but by *contrecoup*;—that is, the patient, in falling, strikes upon the back or the top of his head, while the fracture occurs at the base of the skull. In the first variety, the line or lines of fracture correspond with the lines of union of the three bony portions which together form the temporal bone, and which in fetal life represent separate centres of growth, viz., the squamous portion (together with the zygoma), the tympanic portion (annulus tympanicus), and the petrous portion (together with the mastoid process). These fractures, therefore, partake somewhat of the nature of diastases. In the second variety, the fracture of the petrous portion of the temporal bone represents a genuine fracture. It takes place in the middle part of the bone, where it is greatly weakened by the presence of several large cavities (the meatus auditorius internus, the cochlea, the vestibule, and the semicircular canals), which are separated one from an-

other by comparatively thin partitions of bone. While it is possible that a fracture may take place in the petrous portion of the temporal bone without a contemporaneous fracture or diastasis in the adjacent squamous or tympanic portion, we possess no facts as yet which will justify such a belief. In fact, the general surgeon is not in the habit of recognizing even two subdivisions, such as I have here made. Now, I am satisfied that these subdivisions are by no means fanciful, but rather the reverse: they are eminently practical. Let me illustrate. A person falls, or receives a blow upon the head. Bleeding from the ear follows, and may even be copious in amount. He is unable to hear the ticking of a watch in the affected ear, and, when the good ear is closed, he finds difficulty in distinguishing spoken words. The general surgeon, if he make the attempt to locate the fracture without resorting to an examination of the ear, will be very likely to make this diagnosis: fracture of the temporal bone through its petrous portion; a diagnosis which almost necessarily implies the permanent loss of the hearing of the corresponding ear. On the other hand, an examination of the ear with the speculum and reflected light might show a fracture running along the Glaserian fissure, and a tympanic cavity filled with blood. By aid of the tuning-fork, the fact might also be learned that the sonorous vibrations of this instrument were heard best in the affected ear. The diagnosis would then have to be made of a fracture involving the squamous and tympanic portions, and not the petrous; and the patient could properly be encouraged to hope for a partial, if not a complete, restoration of the hearing. Furthermore, the knowledge gained by such an examination of the ear would be likely to materially modify the treatment that would otherwise be adopted.

There are still other phenomena with regard to which the general surgeon is more than likely to form an erroneous opinion, if he does not take advantage of the light which an examination of the ear is competent to afford him. I refer particularly to two symptoms, viz., hæmorrhage from the ear, and a watery discharge from the same region. In cases of fracture of the temporal bone, a hæmorrhage from the ear means, as a rule, a rupture of the blood-vessels in the vicinity of Shrapnell's membrane. Such a hæmorrhage may be copious, and may continue for a comparatively long time; and the mere fact of its copiousness does not indicate that a communication has been opened between the cavity of the tympanum and any of the large vascular channels which surround the temporal bone. I am convinced, from actual observation in numerous cases, that the blood-vessels in the neighborhood of Shrapnell's membrane, are amply able, under favorable circumstances, to provide both a copious and a pro-

longed bleeding. I am also satisfied, from examinations which I have made in cases of injury to the head of recent occurrence, that fractures of the temporal bone often occur without the slightest bleeding from the external auditory canal. That these views, however, are at variance with those of the best surgical authorities, may be gathered from the following statement, which I have copied from Sir Prescott Hewett's remarks on Fractures of the Base of the Skull, in Holmes's System of Surgery :

"Bleeding from the ears, in severe injuries of the head, has, for many years past, been held, and deservedly too, as one of the most valuable diagnostic signs of fractured base. But this bleeding, to be of any value as a means of diagnosis, must be of a serious nature, and, above all, it must continue for some time. With such a bleeding it may be safely diagnosed that there is a fracture of the base running through the petrous bone, and opening up a communication between the cavity of the tympanum and some of the numerous and large vascular channels which surround this bone, or with an extravasation of blood within the cranium itself."

The other symptom, which is considered to be of so great diagnostic value in cases of suspected fracture of the temporal bone, is that of a watery discharge from the external auditory canal. While our direct knowledge with regard to this symptom is almost a blank, apparently no examinations having been made of the ear in suitable cases, a general knowledge of ear-diseases and of the anatomy of the temporal bone would prevent me from accepting in their entirety the views put forward by Sir Prescott Hewett in the following paragraphs, taken from the article quoted above:—

"There are, then, as far as is known at present, three classes of cases of this watery discharge. In the first class, where the fluid from the ear is plentiful and of a decidedly watery character immediately after the accident, there need be no doubt as to the nature of the injury—the watery discharge is due to the escape of the cerebro-spinal fluid, which, as already stated, can only take place through a fracture of the petrous bone implicating the internal auditory canal and its membranes.

"In the second class of cases, characterized by a copious and prolonged bleeding from the ear, followed by a watery discharge, a fracture of the petrous bone may also be safely diagnosed; but it cannot be said that the fracture follows any particular course. In these cases, it must, however, be clearly understood that it is not to the watery discharge that we can trust for our diagnosis, but to the copious and prolonged bleeding.

"Thus far there is no difficulty. Not so, however, in the third class of cases, in which there is at first a discharge of blood only, neither copious nor prolonged, which is followed by a watery discharge, varying as to the time of its appearance—varying as to its quantity. It may be present within a very few hours after the accident—it may be profuse within a few hours after its appearance. These are the cases in which experience has of late proved

that the diagnosis ought to be doubtful. The discharge of blood is certainly not of a character to warrant a diagnosis of fracture of the petrous bone; and as to the watery discharge, it is now well known that such a discharge may occur within a few hours after the accident, that its quantity may even be profuse, and yet there may be no fracture.<sup>b</sup>

I may be in error with regard to this matter, and yet it appears to me to be a very simple problem, at least so far as the existence or non-existence of a fracture is concerned. To determine the full extent of the fracture, is quite another matter; although even here, as I have said before, it is easily possible to define rather coarsely the parts of the temporal bone affected. If we consider for a moment the solid, masonry-like construction of the temporal bone, we can scarcely resist the conclusion that, when a blow upon the top, back, or opposite side of the head is followed by any decided symptom whatever in the ear (as, for instance, bleeding, a watery discharge, or even simply pain), a fracture or a diastasis must have taken place in the corresponding temporal bone. A mere jar of the head is not competent to produce a hæmorrhage from the external auditory canal. On the other hand, an actual stretching of the soft parts to such a degree as to tear one or more blood-vessels, is not, under such circumstances, physically possible in the vicinity of the drum-membrane, unless at the same time there shall have been an actual giving way of some part of the surrounding arch of bone. Such a laceration of the parts is sure to be followed by inflammation, and this inflammation will be proportionate to the degree of damage done to the parts. A profuse, and sometimes long-continued watery discharge from the middle ear, by way of the external auditory canal, is a well-known characteristic of an ordinary, non-traumatic, acute inflammation of the middle ear, provided that an opening has been established, either by natural or by artificial means, in the membrana tympani. In the severer cases of fracture of the temporal bone, the drum-membrane is very apt to be lacerated, and it is in precisely these severe cases of fracture that we encounter this symptom of a watery discharge from the ear. In estimating, therefore, the diagnostic value of a watery discharge from the ear, in cases of fracture of the temporal bone, I am disposed to go no farther than this—it affords a good measure of the degree of damage done to the temporal bone and contiguous parts. It is by no means necessarily a fatal symptom, for I have known several such cases to recover. I should perhaps not be justified in insisting that all of this watery discharge came from the middle ear and parts bordering upon it. Such, however, appears to me to be the more rational belief.

The treatment ordinarily employed to arrest an acute inflam-

mation of the middle ear, is the treatment that can best be adopted for the relief of the inflammation caused by the fracture. I do not see why it may not, in certain cases, turn the scale in favor of recovery.

I will close this brief chapter by giving the histories of two cases of fracture of the temporal bone due to the impact of bullets.

CASE I.—The patient, a powerful out idiotic-looking negro, thirty-five years of age, while animated by a desire to end his life, fired one chamber of a loaded revolver into his right ear, and then, finding that he was still alive, he discharged the contents of a second chamber into his left ear. This was done on the 6th of March, 1874, and on the 18th he was brought to the New York Eye and Ear Infirmary. I was not able to learn what had been the man's condition during the interval between these dates. The patient himself was perfectly deaf, and the person who accompanied him simply knew the facts relative to the shooting. On examination I found the right external auditory canal filled with polypoid granulations. These sprang from the anterior and lower wall of the meatus, about midway between the outer orifice and the drum-membrane. At this point the bent probe entered an excavation in which loose pieces of bone were encountered. On the left side the auditory canal was also found to be filled with pus. Several small polypoid growths were removed from the narrow canal, but no region of exposed bone could be detected, nor could I obtain a satisfactory view of the deeper parts of the canal. There could be very little doubt, however, of the absence of the drum-membrane, and probably of the ossicles. The right ear being very painful, I prescribed leeches.

On the 23d of April I saw the patient a second time. The leeches had relieved him from pain. With the slender angular forceps I removed two fragments of bone from the right auditory canal.

On the 2d, and again on the 6th of May, I removed fragments of bone, one of which presented a blackened appearance.

On the 9th of May I encountered some hard substance in the region of the middle ear, and succeeded in extracting it. It proved to be a mass of lead; about the size of a half-pea, probably a portion only of the ball fired from the revolver. The opening in the canal from which the fragments of bone had been removed presented every appearance of being on the point of healing.

On the 16th of May I removed another piece of lead and some fragments of bone from the region of the right middle ear.

On the 3d of June I found that the wound in the meatus had healed, and that the mucous membrane of the middle ear was free from all evidences of active irritation. The discharge had apparently ceased entirely.

After the removal of the polypoid granulations from the left auditory canal all active discharge from that ear ceased.

If the damage observed in this left ear is to be ascribed to the effects of the shooting, the bullet must have been extracted by some physician during the period of twelve days that elapsed between the infliction of the injury and the time of entrance into the Infirmary.



In the preceding case it is quite possible that the squamous and petrous portions of the temporal bone (on both sides) were also fractured. The ball, however, may simply have driven the stirrup violently into the vestibule, and not have produced an actual fracture of the petrous bone. In the following case the petrous bone could scarcely have been involved to a serious extent, although probably the squamous portion did not wholly escape.

CASE II.—The patient, an apparently strong man, thirty-four years of age, and a soldier, was admitted to the New York Eye and Ear Infirmary, June 12, 1872. He gave the following history: In the course of an engagement with the enemy, in Valverde, New Mexico, on the 22d of February, 1862, the company of which he was a member (Co. G., First U. S. Cavalry) was ordered to retake a battery. While they were advancing he was shot in the right side of the head, the ball entering the skin just in front of the ear. The shot had come from a detachment of the enemy in the rear. Three days later the ball was extracted from beneath the skin, just above the right eyebrow. He then noticed a sensation of throbbing and fulness in the right ear, and not long afterward a discharge made its appearance in the outer canal. He remembers also that one of his comrades, at about that time, removed a bunch of hair, clotted with blood, from the right ear. During the first ten or twelve months following the injury he frequently found small fragments of bone in the discharge from the ear. Six months previous to his visit to the Infirmary he had experienced a severe attack of pain in the right ear, but before that time he had always been comparatively free from pain. From the very first he had been annoyed by a tinnitus, like the roaring of a shell. All sounds, moreover, seemed to reach him by way of the left ear. At night he had always been obliged to sleep on the right side, for whenever he attempted to lie on the left side the sense of weight in the right ear became unbearable. About a week previous to his visit to the Infirmary the parts about the right meatus became very painful and swollen. The swelling subsided in the course of a day or two, and then for the first time he discovered the presence of some hard substance filling the outer canal. He came to the Infirmary for relief, and in this way became my patient. On examination of the ear I found a black mass, partly covered by pus, blocking up the entrance to the right auditory canal. I experienced no difficulty in extracting it with the forceps, and on examination found it to be a very much corroded, oblong leaden bullet, a little over half an inch in length, and three-eighths of an inch in diameter. The deeper portion of the meatus was found to be filled with a mass of granulations. No sinus could be found, nor any exposed surface of bone. The Eustachian tube was pervious. In front of the tragus there was a depressed scar, indicating the point where the other ball had entered. The patient was unable to hear the ticking of my watch in the right ear. The sound of a vibrating tuning-fork, placed on the central part of his forehead, was referred by him to that point, and not to either ear. With the left ear tightly closed, and the right turned toward the speaker, he could understand ordinary conversation at a distance of four or five feet.

On the 15th of June the patient reported that he had been

quite free from pain since the removal of the ball, and that the discharge had also ceased.

On the 24th of July he again visited the Infirmary. The discharge had not returned. The tinnitus continued unchanged, but the sense of weight had disappeared, and he was able to lie indifferently on either side. Cicatrization had taken place in the ulcerated portion of the meatus, and there was then a clear but funnel-shaped passage down to the cavity of the tympanum. No trace was found of either the drum-membrane or the ossicles.

At the time when he was wounded, and even up to the time when he visited the Infirmary, the patient supposed that his ear trouble had been caused by the glancing backward of a fragment of the ball which struck him in front of the ear. Even the removal of a tuft of hair from the external auditory canal had not suggested to him the idea of a second ball, until after I had shown to him that the leaden mass removed from the meatus could scarcely be considered as a fragment of the ball that had been extracted from above the eyebrow of the same side. He then stated that many of the men in the enemy's ranks were armed with double-barrelled fowling-pieces, and suggested the possibility of his having been shot by the simultaneous discharge of both barrels of such a weapon. A more natural supposition is that he was shot by two balls contained in a single cartridge—one of them entering the meatus directly, without leaving any external wound, the other striking the bone in front of the ear and glancing forward.<sup>1</sup>

<sup>1</sup> For other cases of gunshot wounds of the temporal bone, see Moos, *Archives of Ophthalmology and Otology*, vol. iii., 342; vol. iii., pp. 111 and 216; Terrillon, *Annales des maladies de l'oreille*, 1876, p. 242.

## CHAPTER XII.

### DISEASES OF THE MASTOID PROCESS.

It has been the custom to speak of diseases of the mastoid process as if they were separate and distinct from the different types of inflammation of the middle ear. While, as a matter of fact, the two groups of diseases are inseparably connected, as a matter of expediency it is better that this custom of separating them should be maintained. The mastoid cells ordinarily participate in whatever inflammatory processes take place in the tympanic cavity, without manifesting any symptom that is likely to attract our attention to that quarter. In some cases, however, the symptoms pointing particularly to this region outweigh the others, and under such circumstances no hesitation need be felt in grouping these cases together under the title of diseases of the mastoid process. Before attempting to portray this class of cases, I will first describe briefly some of the more important anatomical features of the mastoid region, as it will be very difficult, without such knowledge, to understand the varying pictures of mastoid disease.

At birth, the mastoid process consists of a small, flattened tuberosity containing but one cell of material size—viz., the antrum. During the first year of infancy this cavity usually lies so near the outer surface of the process that only a thin wall of bone, perhaps only a millimetre in thickness, separates it from the external periosteum. Furthermore, this thin partition of bone is often perforated by quite a large opening, through which passes at least one of the mastoid emissary veins. It is important to remember these relations of the parts as they exist in infancy; for without this knowledge we might experience anxiety over phenomena which, indeed, seem to point to serious disease, but which appear comparatively harmless when interpreted in the light of the anatomical relations which I have just described. The phenomena to which I refer are these: A large swelling develops rather rapidly behind the ear of an infant, who has been fretful and feverish for a few days. There may or may not have been a slight discharge from the ear; but if there have been a discharge, it will very probably have ceased before the swelling makes its appearance. From the fluctuation, which is readily

discoverable, from the inflamed appearance of the neighboring skin, and from the elevation of the body-temperature, it becomes reasonably certain that the swelling represents an abscess. An incision is then made, and the correctness of the diagnosis is established; the recovery that follows is rapid and complete. I have had the opportunity of examining the ear in two or three such cases, and have satisfied myself that the pathology of these abscesses is simply this: The resistance offered to the pus accumulating in the cavities of the middle ear, happens to be less in the direction of the mastoid integuments than in that of the membrana tympani, and the pus accordingly forces a way for itself in this direction rather than through the tissues of the drum-membrane. The abscess is not, as in adult life, an indication of a severe and unchecked inflammation of the middle ear, but simply a revelation of the peculiarly free communication which happens to exist between the antrum and the outer surface of the mastoid bone. The absence of any marked swelling of the walls of the auditory canal shows clearly, in these cases, that the pus has not travelled outward—as we occasionally see it travel in older individuals — between the bone and the skin of the external meatus, but is seeking an outlet by way of the antrum and one of the openings for an emissary mastoid vein.

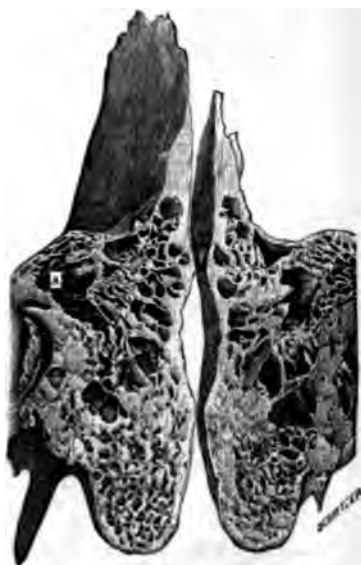

FIG. 83.—Mastoid Process of Adult. Transverse, vertical section, showing both halves of the process. *a*, antrum. (From a photograph by B. Alexander Randall.)

The anatomical relations of the antrum, in infantile life, have other important bearings of a practical nature. In the first place, the outer bony wall of this cavity is quite easily broken, at this period of life, by moderately firm pressure with some hard instrument. It is therefore easy to penetrate from without into the antrum, whenever the condition of the ear seems to call for such a procedure. In the next place, counter-irritation behind the ear, in quite young children, often produces promptly beneficial effects upon a sluggish inflammation of the middle ear. The explanation of this fact may be sought for in this peculiar near-

ness of the antrum to the skin covering the mastoid process, and in the intimate vascular and nervous relations that exist between the two regions.

The mastoid process of a child, four or five years of age, already presents all the essential features of that belonging to a full-grown adult. It is smaller, however, and the bone substance is still somewhat less dense and firm than it is in adult life. Even in its fully developed state the mastoid bone will be found to vary greatly in size in different individuals. I can give no exact measurements, as the limits of the mastoid portion of the temporal bone are not sharply defined. I have a specimen, however, in

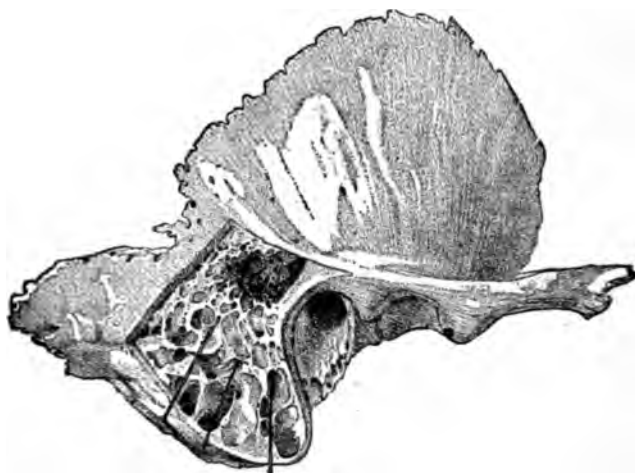

FIG. 84.—Dissection (by chiselling) of the Mastoid Process, showing the Free Communication which exists between the Pneumatic Cells in the body of the Process, and the Antrum. The upper ends of the bristles may be seen projecting into the cavity of the antrum. (From Nuhn's Atlas of Surgical Anatomy; slightly reduced in size.)

which the distance between the upper and lower limits of the mastoid cells measures an inch and three quarters, while horizontally the extreme limits are an inch and a quarter apart. This specimen, I am satisfied, must be considered as an unusually large one, for among a number of temporal bones in my possession I can find no other in which the mastoid cells are of equally great extent. That represented in Fig. 84 shows the distribution of the air cells, as seen in the majority of specimens. Strictly speaking, the term mastoid process refers only to the lower, teat-like projection of the bone, but in this article, and in fact in medical parlance generally, the expression is intended to refer to all that portion of the temporal bone which contains the honeycombed structure usually found in the mastoid process. This peculiar

structure consists of a number of small cavities or cells, which vary greatly in size and shape, not only in the same temporal bone, but also in those belonging to different individuals. Many of these cells, probably the great majority of them, are lined with an extension of the mucous membrane of the tympanum, and communicate one with another. Under normal conditions they contain air, and are therefore spoken of as the pneumatic cells. The remaining cavities are filled with a fatty tissue resembling that which is found in the diploë of fresh bones. Zuckerkandl, who examined one hundred mastoid processes in the fresh state, and one hundred and fifty macerated temporal bones, found that air-cavities were wholly lacking in twenty per cent. of the specimens, and that perfectly pneumatic mastoid processes, without any diploëtic spaces, represented only 38.6 per cent. of the entire number. Furthermore, he ascertained the fact that in some individuals only the lower half of the process was diploëtic, while the upper half was entirely pneumatic. These comparatively recent researches throw a great deal of light upon the pathology of acute and chronic purulent affections of the middle ear. They make it easy to comprehend how in one individual, whose mastoid cells are quite large and communicate freely one with another, an inflammation of the middle ear may, almost at the very onset of the attack, involve the mastoid region, while in another the same disease, in perhaps a far more severe form, will leave this region wholly unaffected. Unfortunately, Zuckerkandl's researches do not show whether we are permitted to consider the absence of pneumatic cells, in the specimens examined by him, as a perfectly natural peculiarity of construction, or whether these spaces may not have been obliterated by an unnatural hypertrophy of the bone, the result of disease.

We must next consider the mastoid cells in their relations to neighboring parts. Superiorly, they may extend as high as to within half an inch of the temporo-parietal suture. In this comparatively thin part of the temporal bone they are separated on the outer side from the periosteum, and on the inner side from the dura mater, by a dense layer of bone which varies from one to three millimetres in thickness. Anteriorly, the pneumatic cells extend forward over the external auditory canal. Posteriorly, they cease somewhat abruptly, that is, without any material diminution in size, in the immediate vicinity of the temporo-occipital suture. Hyrtl, according to the authority of Schwartz, found three skulls (among six hundred which he examined for this purpose) in which the pneumatic cells extended even into the occipital bone. I once, in trephining the skull, found pus between the outer and inner tables of the occipital bone, a short distance back of the temporo-occipital suture, and thought, at

the time, that it had travelled along the diploëtic spaces from a large abscess which existed in the body of the mastoid process. In the light of Hyrtl's discovery, it now seems to me at least equally probable that the pus found at this remote spot was really lying in pneumatic spaces which stood in direct communication with those immediately surrounding the abscess. The lateral sinus occupies a groove in the bone in the immediate vicinity of the posterior limits of the mastoid cells. Not far from the centre of the irregularly shaped mass of mastoid cells, but much nearer to their inner than to their outer limit, lies a single cavity, known by the name of the "antrum," or "horizontal portion of the mas-

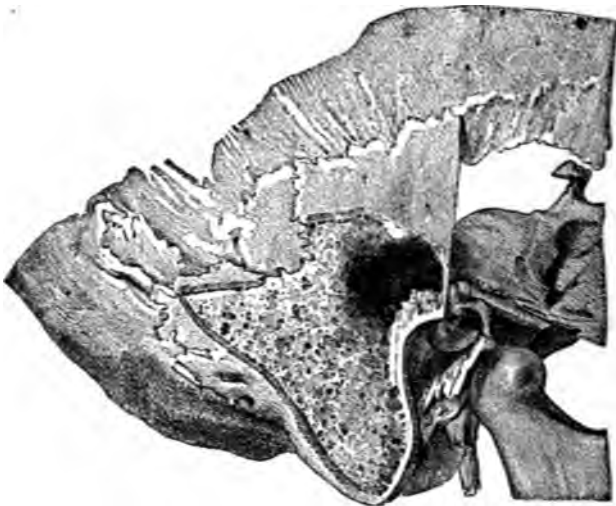


FIG. 85.—Dissection of a Mastoid Process in which the Pneumatic Cells are less well developed than in the preceding figure. (After Nuhn.)

toid cells," as it is termed by Toynbee. It opens anteriorly, by a comparatively large mouth, into the tympanum proper. Its floor usually lies at a higher level than that of the tympanum. Its walls present a honeycombed appearance, which is due to the presence of numerous openings leading into the surrounding pneumatic cells. (Fig. 86.) A medium-sized pea would probably fill the antrum. Pneumatic cells are found on the inner and posterior sides of this cavity as well as on its outer side. They also extend to a considerable depth beneath its floor. In fact, they are absent only along the roof of the cavity. At this point a comparatively thin lamina of dense bone, often less than a millimetre in thickness, serves as a dividing partition between the dura mater above and the tympanic mucous membrane

below. The distance from the posterior extremity of the antrum to the groove for the lateral sinus varies from three to six millimetres; that from the outer wall of the cavity to the outer surface of the bone varies from twelve to twenty millimetres (one-half to three-fourths of an inch). In cases of hyperostosis the antrum may be found to lie at even a greater distance from the outer surface of the bone. Finally, there are several points at which the bone surrounding the antrum is pierced by small channels which give passage to blood-vessels and lymph-vessels, and their sheaths of connective tissue. The most important of

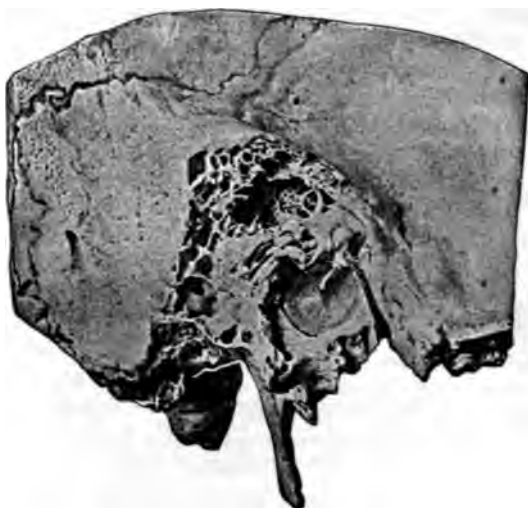

FIG. 86.--View of the Mastoid Antrum, as seen by a person looking from within outward. (Natural size.) The short process of the anvil may be seen resting against the lower edge of the entrance from the tympanic cavity into the antrum. Toward the right the outer wall of the antrum (the background of the cavity, in the picture) shows distinctly the numerous small openings which lead from this cavity into the adjacent mastoid cells. Furthermore, the picture enables one to judge very satisfactorily of the relations of the antrum to the membrana tympani,—the only part of the middle ear that it is usually possible for us to see by direct inspection. (Copied from a photograph taken by Dr. B. Alexander Randall, of Philadelphia.)

these are: the petro-squamous fissure, which crosses the bony roof that is common to both cavities (the tympanum and the antrum); and the channels for the mastoid emissary veins, which traverse the bone from within outward. One of these canals commonly opens near the centre of the outer surface of the process, about on a level with the upper wall of the external auditory canal. Minute blood-vessels pass from the mucous membrane of the middle ear to the dura mater by way of the petro-squamous fissure, and by the same route an inflammation may spread from the ear to the brain. The redness, tenderness,



and swelling of the mastoid integuments, in cases of inflammation of the middle ear, may be explained by the assumption that the inflammation has followed the course of the mastoid emissary veins. Finally, I have still to mention the close proximity of the facial canal to the mastoid cells. (Fig. 87.) In the immediate neighborhood of the mouth of the antrum, this canal turns sharply from its previous horizontal course, and passes directly downward through the pneumatic and diploëtic cells of the mastoid bone. It is therefore easy to understand why the facial nerve should be particularly liable to participate in any pathological changes that may take place in the mastoid cells.

Although the antrum and the tympanic cavity proper are, to all intents and purposes, one and the same region, and although we have no just grounds for believing that, in an acute inflammation of the middle ear, the larger cavity of the tympanum is

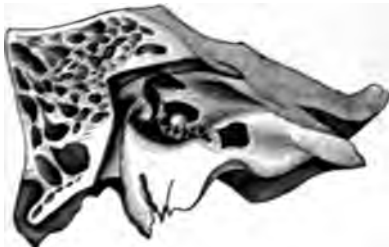

FIG. 87.—Relations of Facial Canal to Middle Ear Proper and Mastoid Cells. Oblique vertical section of petrous portion of temporal bone. (The inner wall of the tympanic cavity has been incorrectly drawn.)

much more actively involved in the disease than the smaller cavity of the antrum, we are apt, it appears to me, to entertain this very belief. Our patients would fare better, I am confident, if we adopted the more rational view, and utilized the degree of inflammation presented by the drum-membrane and visible adjacent parts as a fairly true measure of that which must at the same

time be going on in the antrum. In this connection, however, we must remember that in a few exceptional cases the membrana tympani may show comparatively insignificant evidences of inflammation, and yet an abscess may be present in the adjacent mastoid process. The mechanical relations of the tympanum proper, the antrum, and the pneumatic cells of the mastoid process, exert a determining influence upon the course of the inflammation that may from any cause be excited in them. At almost the very outset of such an inflammation the only natural outlet which these cavities possess, viz., the Eustachian tube, becomes closed by the swelling of its walls. The conditions then are those of an inflammation taking place in a cavity whose walls, at every point but one, consist of unyielding bone. The membrana tympani represents the only point at which the accumulating products of the inflammation can force a way of escape for themselves. In a few instances the case may be in even a worse plight than that which I have just described. For

example, the mouth of the antrum, or the mouths of the numerous pneumatic cavities which open directly into the antrum, may become closed; in which event the establishment of even a very free opening in the membrana tympani would fail to afford an exit for the secretions confined in those more remotely situated cavities. This occurrence is, I believe, not uncommon. The question then presents itself, what is likely to be the succession of pathological events if the products of inflammation are allowed to remain pent up in these cavities? If we possess some knowledge with regard to the individual's previous aural history, we may form a tolerably correct notion of what is likely to take place in these inflamed parts. In an individual who has not been subject to frequent or prolonged attacks of discharge from the ear, we may assume that the pneumatic cells still contained air at the time of the attack. In that case the inflammatory exudation in the cells will soon change from a mere bloody serum to a thick pus, and, as the pressure increases, the lining mucous membrane of many of the cells will die and break down into purulent detritus. Even the thin bony partitions may soften and become detached. At all events, loose fragments of the bony septa are sometimes found in recent abscesses of the mastoid process. In favorable cases, the pus may burrow a way for itself along one of the emissary canals, and pour its contents into the space between the outer surface of the bone and the periosteum, and through the latter into the cellular tissues behind the ear; or it may travel downward and develop an abscess in the soft parts below the mastoid process, between the skin and the muscles of the neck. In a third series of cases, the pus may work for itself a channel through the mass of bone which separates the floor and anterior part of the antrum from the upper and posterior wall of the auditory canal. Finally, if the resistance in these directions be too great, or if the channels of communication between the antrum and the intra-cranial cavity be unusually free, pus will find its way to the latter region, and will induce either a diffuse meningitis or an abscess in the very substance of the brain. It is possible, also, that in recent cases a carious process may be set up in that part of the bone which lies next to the groove for the lateral sinus, and that ulceration of this vein, with accompanying phlebitis, pyæmia, etc., may result therefrom. This issue, however, is to be looked for rather in chronic cases, in which the main portion of the pneumatic cells has been obliterated by sclerosis.

If a severe inflammation of the middle ear goes on unchecked, in an individual whose previous aural history points to the frequent occurrence or prolonged continuance of a discharge from this region, especially if associated with imperfect or obstructed

drainage from the inflamed area, we may assume, with considerable confidence, that the majority of the pneumatic cells have become obliterated through a process of sclerosis. It will be seen at once that in such an ear the chances of a spontaneous cure are seriously diminished. When the antrum, in such a case, takes on a more acute type of inflammation, the confined pus cannot, as in recent cases, burrow a way for itself outward through the thick mass of ivory-like bone. The bony roof of the antrum is then likely to become carious, and as a result the pus finds an outlet in this dangerous direction. Or the mass of bone which sepa-

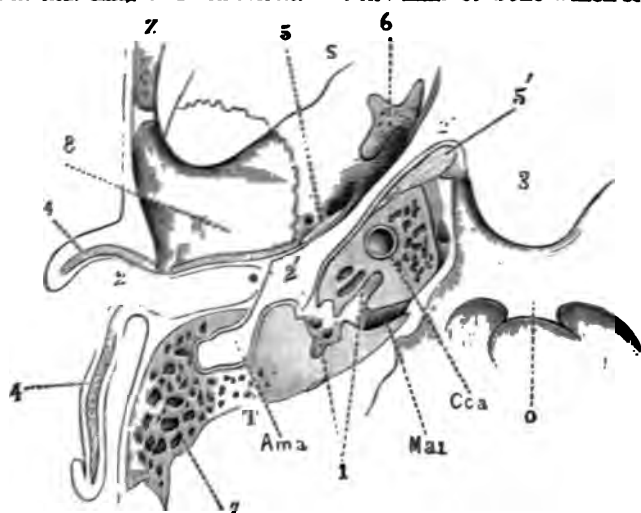


FIG. 86.—Henle's Diagram showing Relations of all parts of the Temporal Bone to each other. 1, Various cavities constituting the labyrinth; 2, External auditory canal; 2', Tympanum; 2'', Pharyngeal mouth of the Eustachian tube; 3, Vault of pharynx; 4, Cartilaginous framework of auricle; 5, Inner cartilaginous lip of orifice of Eustachian tube; 5', Cartilaginous plate at tympanic orifice of Eustachian tube; 6, Pterygoid process of sphenoid bone; 7, Mastoid cells; 8, Glenoid fossa of temporal bone; \* Membrana tympani; Ama, Mastoid antrum; Cca, Carotid canal; Mai, Meatus auditorius Internus; O, Basilar process of occipital bone; S, Sphenoid bone; T, Temporal bone; Z, Zygoma.

rates the antrum from the lateral sinus, and which, I believe, is largely composed of diploëtic spaces, breaks down under the effects of caries, and then the fatal issue is not long delayed.

In addition to these destructive forms of inflammation of the mastoid process, there is one which partakes rather of the nature of hypernutrition of the bone. To this form, which leads to the condition known as *sclerosis of the mastoid cells*, we shall give the name of *condensing osteitis of the mastoid process*. This type of mastoid inflammation has now been accepted, thanks chiefly to the writings of Dr. J. Orne Green, of Boston,

as a fairly distinct disease, characterized by certain well-marked symptoms, and requiring, for the relief of the most prominent of these, a particular therapeutic procedure. A chronic hyperæmia of the mucous membrane lining the pneumatic cells, and also of the vascular connective tissue that fills the diploëtic spaces, undoubtedly constitutes the essence of this osteitis. A chronic inflammation of the mucous membrane of the tympanum proper, and of the antrum, furnishes the provocation for this hyperæmia. Increase in the amount of bone follows this chronic hyperæmia, and in the course of time this increase may even go so far as to obliterate the pneumatic spaces entirely. The constantly increasing pressure exerted upon the mucous membrane lining these spaces, explains the severe pain experienced by patients who are affected with this disease.

A *periostitis* of the mastoid process is always, I believe, to be interpreted as the result of direct violence (a blow or a fall), or as an extension of an inflammation, located either in the external auditory canal or in the mastoid cells. I have never seen anything that I could consider as a primary, idiopathic, mastoid periostitis, although such a disease has been described by different writers on otology.

In actual practice we find that no two cases of mastoid disease are exactly alike. At the same time, it is not a difficult matter to distinguish among them a few groups, in each of which there are certain characteristic features which belong to the members of the group in common. Formerly I made a subdivision of these cases into five groups, but I am satisfied now that it is a better plan not to recognize more than three types of mastoid disease. They are as follows: (1) Subacute, condensing, mastoid osteitis; (2) Acute, diffuse, mastoid osteitis; (3) Chronic ulcerative inflammation of the mastoid antrum. These three groups differ materially from the three classes into which I have divided mastoid affections in my former treatise on ear diseases. It is my belief and hope that this new subdivision, which simplifies the subject considerably, will enable the practitioner to arrive more quickly and surely at a correct diagnosis.

#### I. SUBACUTE CONDENSING MASTOID OSTEITIS.

*Sclerosis or Hyperostosis of the Mastoid Process.*—It is only a short time since the somewhat independent nature of this affection has been known to us. It owes its origin to a chronic purulent inflammation of the antrum and other parts of the middle ear, but it may continue as an active disease for some time after the exciting cause has been removed. In very many cases it probably runs its course without giving rise to any decided symptoms, but in other instances severe pain and outward evidences of mas-

moid periostitis accompany the disease and reveal its existence to us. The protracted subacute inflammation of the mucous membrane which lines the pneumatic cells, and also probably of the connective tissue which fills the diploëtic spaces, leads to the gradual filling up of both these varieties of cavities with bone substance. This form of osteitis rarely comes before us as a disease requiring treatment. It usually assumes importance when we are called upon to investigate and treat those cases of mastoid disease which are grouped together in this treatise under the title of Chronic Ulcerative Inflammation of the Mastoid Antrum. The question is then sure to present itself: What is the condition of the mastoid cells which lie between the antrum and the outer surface of the bone? The following rule may safely guide us under these circumstances: If the history of the case reveal the previous existence of chronic purulent inflammation of the middle ear, and especially if we find evidence that the outlet through the drum membrane has been too small to afford free drainage, we may assume that the mastoid cells have been greatly reduced in size, if not obliterated, by earlier attacks of subacute osteitis. In the few cases of condensing osteitis which are likely to come under our observation because they require treatment for the disease itself, we may very readily be led into the error of supposing that we are dealing with a case in which the essential lesion is an acute, diffuse, mastoid osteitis, of a serious nature. The pain is sometimes so severe that no other diagnosis seems possible. Under these circumstances we may be guided by the following considerations: If the case be one of simple, condensing, mastoid osteitis, our attention cannot fail to be drawn to the persistence of decided pain in and around the mastoid region, despite the existence of an apparently adequate outlet in the drum-membrane for the pus secreted in the middle ear, despite the absence of anything like an acute inflammation of the middle ear or external auditory canal, or, finally, despite the employment of such therapeutic measures as would be likely to allay any ordinary inflammation of the mastoid structures. Furthermore, if, in addition to the pain, there be redness, tenderness, and swelling of the mastoid integuments—in the supposed case which we are now considering,—these manifestations must be interpreted as furnishing corroborative evidence of the existence of a persistent, subacute inflammation of the underlying bony structures. Actual enlargement of the bone itself may be considered as furnishing almost positive proof that the mastoid cells have been obliterated, or are still being obliterated, by a process of hyperostosis.

As far as the affection itself is concerned, the *prognosis* is by no means bad. The obliteration of the mastoid cells by the conversion of all this part of the mastoid process into solid bone, is apt

to do harm only in two ways: It shuts off the possibility of a spontaneous cure in the event of the development of serious inflammation in the antrum; and it is also apt eventually to prevent the development of those outward evidences which afford so valuable a warning of the existence of deep-seated disease in this part, *viz.*, redness, swelling, and tenderness of the skin covering the mastoid process.

*Treatment.*—Hot poultices, leeches, and even Wilde's incision, will probably fail to give more than temporary relief. If such prove to be the case, and if the pain continue unabated, we should not hesitate to resort to perforation of the painful bone with a drill or other suitable instrument. One opening will probably suffice, provided that it be carried to a depth of fully half an inch. As the beneficial effects of this operation, in a case of this nature, depend not upon the establishment of an outlet for pent-up products of inflammation, but rather upon the derivative effects exerted by such a wound in the bone, no effort need be made to reach the antrum. The healing of the external wound may be delayed to advantage, by inserting into it a tent of sheet-lint, well anointed with carbolated vaseline. At the end of twenty-four, or at the most forty-eight hours, the tent should be removed. In addition to these measures, which are directed more particularly to the osteitis, we must not neglect to do whatever may be found necessary for the relief of the disease which involves the middle ear proper. The systematic cleansing of the antrum, by means of the douche, will often be found to serve an excellent purpose in these cases, although as a matter of course the local conditions may not always be such that we can resort to this procedure. The following cases will serve as illustrations of the type of mastoid disease which I have just been considering:

CASE I.—The patient, a lady, about thirty-five years of age, consulted me on March 30, 1880, on account of a discharge from the right ear, and frequent attacks of pain throughout the right side of the head. I was not able to obtain a very full account of her previous history, so far, at least, as it related to the affected ear; but, as the result of my cross-questioning, I ascertained that the disease had begun in early childhood, as an acute purulent inflammation of the middle ear; that it had then run an irregular course, lighting up at long intervals into an acute exacerbation, and then subsiding again into a comparatively quiet state; that there had always been some discharge from the ear, at one time very scanty, at another quite copious; and that the disease had finally, during a period of ten or twelve months immediately preceding the time when I first saw her, settled down into a steady discharge from the ear, associated with frequent and sometimes quite severe attacks of pain involving the right side of the head. The affected ear still possessed a useful degree of hearing. An examination with the speculum and reflected light revealed the existence of a thick laminated mass of epithelium, pus, and

cheesy matter, occupying the deeper part of the external auditory canal. Fresh pus was oozing out from beneath the mass. By aid of the eurette, a slender silver probe, and a mop of cotton wound around the end of a cotton-holder, I was able to clear away all these old and foul-smelling products of inflammation, and to obtain a clear view of the diseased region. About two-thirds of the membrana tympani still remained, and the greater part of the discharge evidently came from the mastoid antrum, the tympanic mouth of which was partly blocked by a small polypoid growth. I removed this growth with the wire loop and Blake's snare, and advised the patient to use regularly, for a short time, the douche with lukewarm water. My scant notes say nothing about the condition of the mastoid process; and from this I infer that I must have overlooked certain conditions which very probably existed at that time, but which I did not discover until later.

On March 8, 1882, or nearly two years later, the patient again consulted me. During this long interval the ear proper had given her very little trouble, and there had only been an occasional slight discharge, but she had still continued to be subject to periods of pain involving the right side of the head, and occasional attacks of flushed face. During the previous week, however, the pain had been quite severe and had localized itself more particularly in the ear. She had also experienced considerable dizziness at times. I examined the ear and found that the degenerative process had a second time produced a tough plug that filled the deeper end of the meatus. I also found, by aid of a bent probe, that the upper part of the tympanic cavity, posteriorly, was filled with a tough white mass of laminated epithelium. It was only after prolonged efforts, made partly with the bent probe and partly with a douche provided with a slender glass end-piece, bent at a right angle, that I finally succeeded in completely freeing the cavity from the offending masses.

A sharp inflammation followed this prolonged operative interference. It spread along the cutaneous lining of the external auditory canal, and caused it to become greatly swollen; it extended along the Eustachian tube, and rendered the act of swallowing painful; and, finally, it involved the cellular tissues behind, above, and in front of the ear. Throughout all these outer regions tenderness on pressure, redness of the surface, and decided œdematous swelling were noticeable already on March 10th. The body-temperature was 102° F. The application of hot poultices having failed to afford much relief from the pain, I made a Wilde's incision and divided the mastoid periosteum freely. I also prescribed the frequent application of hot flax-seed meal poultices.

On the following day I found the patient in a more comfortable condition, but there was still a great deal of inflammation all around the ear. Three leeches were applied behind the ear, and the continuance of hot applications was advised.

On March 12th I found more decided evidences of the subsidence of the inflammation.

On the 13th the body-temperature was 99° F., and the patient expressed herself as feeling fairly well again. A small amount of pus constantly escaped from the auditory canal, and its walls were still so much swollen that I could not obtain a satisfactory view of the deeper parts. The tenderness, however, had almost entirely disappeared, except immediately over the mastoid region.

About the middle of April I removed another polypoid mass of

granulations from the tympanic orifice of the antrum, and from that time forward the discharge ceased altogether.

On May 10th I made a careful examination of the ear, and found that all those parts of the middle ear which could be seen were pale, dry, and perfectly free from the slightest trace of congestion. So far as I could ascertain by means of the bent probe, the antrum and the posterior upper portion of the tympanum were empty. The cutaneous walls of the auditory canal were also perfectly free from either redness or swelling. Behind the ear, however, the skin was noticeably red, and firm pressure with the finger, at almost every point over the mastoid process, caused some pain. These parts were at the same time slightly œdematous. On comparing this region with the corresponding one on the other side of the head, I discovered, for the first time, that the right mastoid process was appreciably larger than the left. On simple inspection it seemed to be markedly larger, but on palpation, and after making due allowance for the œdematous condition of the integuments, I became satisfied that the difference in size was only moderate in degree, though yet unmistakable. As the patient was still subject to almost constant pain in the region behind the ear, and in fact throughout the entire right side of the head, I applied three leeches directly over the right mastoid process, and allowed the after-bleeding to go on unchecked for a considerable time.

On October 6th I again had an opportunity of examining the patient's condition. She reported that the local blood-letting referred to in the preceding paragraph, had afforded her decided relief from pain for a period of several days. The pain had then returned, and all through the summer she had experienced more or less of it, not constantly, but yet very frequently. Blisters had also occasionally been applied over the mastoid region, but without any beneficial effect. Notwithstanding the persistence of the pain, she had had the best of health in all other respects. On examination, I found the deeper parts of the ear in a perfectly quiet state, and free from even the slightest evidence of inflammation. On the outside, however, the previously described condition of redness, tenderness, and slight œdema still persisted. In fact, the tenderness extended as far back as the occipital protuberance. As the pain had been more acute than usual during the previous three or four days, I advised a repetition of the local blood-letting. (The patient has since moved away from the city.)

CASE II.—A physician, a resident of South Carolina, fifty-six years of age, and of a strong constitution, consulted me on October 6, 1872, for a painful affection of the ear. He gave the following history: In 1835 he contracted an acute inflammation of the left middle ear from the violent concussion of the ear caused by the bursting of a gun. The severe symptoms soon passed away, but the purulent discharge from the ear continued for some time afterward. Then, for a period of many years, he experienced no trouble beyond a moderate degree of deafness and some tinnitus. The perforation in the drum-membrane remained unclosed through all these years. About twelve weeks before the time when I first saw the patient, he noticed that there was a slight watery discharge from the left ear, which was at the same time somewhat painful. The pain became gradually more severe and was associated with headache and fever. The doctor bled himself to the extent of about sixteen ounces; six hours later he took from the arm an additional quantity of



about eight inches. A profuse suppuration from the ear soon took place, and the pain then became less severe. For a month no marked change occurred in the condition of the ear. The discharge continued, though at times it would almost cease. On August 23d he had a rigor which was followed by a return of all the acute symptoms. The pain was referred to the base of the brain, the mastoid process, and the articulation of the jaw, and was very severe. Resulting to the amount of twelve or fifteen ounces afforded some relief, and the discharge again became abundant. For a week the pain remained moderate. On August 31st he had another rigor, followed by intense pain, referred to the mastoid process, whence it extended backward toward the occiput and occipito-vertebral articulation; in fact, the whole side of the head was painful. There was tenderness over the mastoid process, and the auricle was pushed out somewhat from the head. On September 15th, no material improvement having taken place in his condition, the doctor started for New York, in the hope of obtaining relief there. The sea-voyage from Charleston benefited him very decidedly. The severe symptoms abated, and, for some time after reaching this city, he enjoyed, at least during the day, comparative comfort; toward night, however, the old trouble returned with greater or less severity. During the few days preceding his visit to me he suffered acutely from pain in the region of the ear. On examination I found the meatus in a normal condition, the membrana tympani perforated anteriorly, the Eustachian tube freely open, and only a trace of pus in the middle ear. The mastoid integuments were oedematous and tender on pressure. The tenderness also extended back toward the occiput. General condition fair; pulse a little accelerated; no heat of skin. At a consultation held by Dr. James R. Wood, Dr. Hermann Knapp, and myself, it was deemed best to perforate the mastoid process. At the patient's own request the operation was performed without the aid of an anæsthetic. The appearance of the bone, after the periosteum had been divided and lifted to one side, was entirely normal. The drill was applied on a level with the upper wall of the meatus, and was made to penetrate to a depth of three-fifths of an inch without encountering the characteristic cells. At this depth, however, a tolerably firm pad of connective tissue was felt. It was supposed at the time that this mass filled the antrum, but on subsequent inspection I became persuaded that, owing to the thickness of the swollen integuments and the recumbent position of the patient, I had erred somewhat in the direction which I gave to the drill, pointing it too far backward. The pad of connective tissue was undoubtedly the outer wall of the lateral sinus.

October 13th.—Patient passed a comfortable night. Pain much less than before the operation. Ordered quinine, gr. vj, daily.

October 14th.—Pain again severe. Consultation with Dr. Robert F. Weir and Dr. Hermann Knapp. A second perforation was made with the drill, this time nearer to the meatus and on a somewhat lower level than the first. The mastoid cells encountered were small and congested, but no pus was found. Tent inserted; poultices.

October 15th.—Slight improvement.

October 16th.—Pain diminishing. Temperature, 97° F. Free discharge from wound.

October 17th.—Marked improvement in every respect. Application of poultices to be discontinued.

October 23d.—Tenderness over mastoid process almost gone.

November 14th.—Patient is quite well again. There is no discharge from the meatus, and the wound behind the ear has healed except at two points, corresponding to the two perforations in the bone.

A few weeks later I heard from the patient, who had returned to his home, that he had remained free from pain, and that his general health was quite good again.

To these two cases I wish to add one reported by Dr. J. Orne Green. While it is comparatively free from disturbing complications, and therefore admirably adapted to serve as a type for purposes of study, I cannot help believing that this patient, at some earlier period of his life—perhaps many years before the occurrence of the acute attack which, according to the history given, apparently afforded the exciting cause of the mastoid hyperostosis—must have had a prolonged inflammation of the middle ear. The history of this case is as follows:

CASE III.—“Another case in which osteo-sclerosis existed, and was proven by operation, was that of a man seen in 1878. He was about thirty-five years of age, previously healthy; one week before, he began to have pain in the left ear, followed by discharge two days after, and severe vertigo with vomiting and great weakness; there were also subjective noises as of hissing. Examination showed purulent inflammation of the tympanum with a minute perforation, which was enlarged with a paracentesis needle so as to give free evacuation. A few days after, there was a slight paralysis of the left facial nerve. The inflammation of the tympanum subsided under treatment, the perforation healed, the paralysis disappeared, and at the end of two months the ear was apparently well, but the deafness was absolute on that side. Pain in the mastoid and over the side of the head continued, however, with slight tenderness of the mastoid on deep pressure, but without any swelling of the soft tissues; no enlargement of the bone was perceptible. Other means failing to relieve the pain, the bone was perforated under ether with a triangular borer to the depth of half an inch; no pneumatic cells were reached, the bone throughout being dense and ivory-like. The relief from the operation was gradual, but decided, and the patient made a good recovery. In this case also there was no reason to suspect syphilis.”

## II. ACUTE DIFFUSE MASTOID OSTRITIS.

This variety of mastoid disease includes all the different degrees of inflammation which may develop in a previously healthy mastoid process. It is essentially an inflammation of the mucous membrane lining the air cells of this bony prominence. A widespread congestion of the mucous membrane of the antrum and pneumatic cells represents, therefore, the simplest type. The inflammation may cease spontaneously, or may be arrested by therapeutic interference, when it has reached this stage, and the parts may then gradually return to their normal condition (see Cases

I., II., and III.). However, if the inflammation continue, both the antrum and the pneumatic cells will soon be filled with exudation, and whatever be the character of this exudation at first, it is sure before long to become distinctly purulent. I think it possible that, even after the disease has reached this advanced stage, a spontaneous recovery may still, under favorable circumstances, take place, without the formation of an abscess in the bone (as in Case IV.). I may mention, as one of these favorable circumstances, the sudden escape of part of the exudation, through one of the channels which naturally give passage to the mastoid emissary veins, into the soft parts on the side of the neck. It is more likely, however, that the disease, if left to itself, will pass from this second stage into a third, which is characterized by the death of some part or parts of the mastoid process. Pressure continued beyond a certain period is sure to result in the death of the mucous membrane pressed upon; and, in the case of the pneumatic cells, the mucous membrane is probably the only source of nourishment which very many of them possess. Hence the death of those bony septa which have been deprived of their periosteal coverings. Softening and disintegration of the bone follow next in order, and, if the pressure continue, we may expect the area of dead bone to increase. In cases belonging to this second group of mastoid affections, this progressive death and ulceration of the bone are fortunately somewhat more likely to follow an outward course toward the skin than an upward direction toward the brain, or a backward one toward the lateral sinus. In this way a spontaneous cure has often taken place, the pus finding an outlet through a carious channel in the outer part of the mastoid bone.

The *symptomatology* of this form of mastoid disease is at first precisely the same as that of an ordinary acute, purulent inflammation of the middle ear. The pain, however, shows a marked tendency to persist, even when active measures are adopted for the purpose of alleviating it, and is apt gradually to involve the entire side of the head. Usually there is a moderate elevation of the body-temperature, though I have known even this symptom to be lacking. In a boy of eighteen, I once noted, just before establishing an artificial opening in the mastoid bone, a temperature of 105 Fahr. It fell to 99° F. soon after the operation. Redness, tenderness, and swelling of the skin covering the mastoid process, indicate the existence of a mastoid periostitis; and the development of a mastoid periostitis in the progress of an undoubted acute inflammation of the middle ear admits of only one interpretation, viz., it indicates the existence of an inflammation of the mastoid cells. Unfortunately, it does not indicate how far the inflammation has progressed, but this important fact

can be ascertained approximately in other ways. For example, the degree of redness and swelling of the upper and posterior cutaneous wall of the auditory canal, in the neighborhood of the membrana tympani, furnishes a safe criterion of the activity of the inflammation in the antrum. A glance at Fig. 88 will show how near these cavities are to each other at this point. The duration and severity of the pain, both in the mastoid region and throughout the entire side of the head, must also be remembered when we are endeavoring to decide in our minds what is the exact condition of the mastoid structures. In the presence, therefore, of well-marked mastoid periostitis, of decided redness and appreciable swelling of the skin along the posterior and upper wall of the meatus, close to the drum-membrane, and of a history of pain behind the ear and throughout the entire side of the head for a period of not less than one week, we may unhesitatingly assume that the inflammation of the antrum and pneumatic cells has reached a stage in which pus must have formed in the antrum, and probably in many of the pneumatic cells. If a prolapse of the posterior and upper cutaneous wall of the meatus has already taken place, we can feel confident that the disease has gone even farther, and that caries is liable to ensue at any time if it have not already occurred. This drooping or separation of the skin from that portion of the bony wall which serves at the same time as the floor or anterior wall of the antrum, indicates a high degree of inflammation in this particular region of bone; and if the adjacent body of the mastoid process is still pneumatic—and, in the class of cases which we are now considering, we have a right to assume that it is still in that condition,—it is scarcely conceivable that it should not be participating, to a more or less marked degree, in the inflammation.

The following brief histories of cases are given as illustrations of the different types and degrees of severity of an acute diffuse mastoid osteitis:—

CASE I.—Female, thirty-two years of age, and in robust health; she was attacked with an influenza on the 9th of November, 1872, and had more or less fever, with a constant catarrh of the eyes and nose. On the 12th the right ear became involved, the symptoms being moderate deafness, roaring and some pain. Watch heard at a distance of six inches. External auditory canal healthy. Membrana tympani dull, opaque, and rather flatter than normal. The air during inflation entered the middle ear with a dry sound. Four leeches applied in front of the ear.

November 14th.—The leeches afforded only partial relief. Membrana tympani oedematous in appearance and somewhat convex outwardly.

November 15th.—Patient passed a bad night. The pain is again severe, and is referred by her to the entire side of the head. Tenderness on pressure over the mastoid process, but no redness or swelling of the integuments. The posterior wall of the ex-

ternal auditory canal has also become tender upon pressure. A free vertical incision through the posterior half of the membrane was followed by an oozing of bloody serum from the wound. By inflation of the middle ear through the Eustachian catheter the serum was made to escape in such quantity that it ran down over her cheek.

November 16th.—Comparatively free from pain last night. The watery discharge continued through the night, as shown by the stains on the pillow. The tenderness has disappeared, and patient feels quite well again. No subsequent return of the pain.

CASE II.—Female, about thirty-five years of age, and of a rather delicate constitution. January 20, 1877. Two days ago, while suffering from a bad "cold in the head," and not very long after snuffing salt water for the relief of her trouble, she was seized with a rather sharp pain in the right ear. Yesterday, the pain in the meantime having grown worse, five leeches were applied behind the ear. These afforded only temporary relief, and, as a consequence, she was able to get but little sleep during the night. To-day the pain has been severe. On examination with the speculum and reflected light, the membrana tympani, and especially the upper and posterior portion, is found to be red and swollen. Two small blebs, springing from the lower wall of the canal, conceal the lower part of the drum-membrane from view. Incision of posterior half of the membrane afforded escape to a drop of bloody serum. Warm douche to be used freely. Patient to remain in bed.

January 21st.—She has passed another night of suffering. There is now a free sero-purulent discharge, but the pain has not abated. On examination the posterior wall of the meatus is found to be greatly swollen in the vicinity of the drum-membrane. Tenderness over the mastoid process, but no redness or swelling of the integuments. Patient being under the influence of ether, two free incisions were made through the inflamed tissues of the external auditory canal and posterior fold of the drum-membrane, and a third through the mastoid integuments. Tent introduced into the external wound. Poultices to be applied, and patient to be given 10 minims of Magendie's solution of the sulphate of morphia.

January 22d.—She passed a fairly comfortable night, and to-day feels comparatively free from pain. Tent removed.

January 23d.—Pain again moderately severe. The discharge from the ear is now decidedly purulent. Pulse, 104; temperature, 99.2 F.

January 24th.—Pain still persists throughout the entire right side of the head, and is especially noticeable whenever she coughs.

January 25th.—Last evening pain again became quite severe. Temperature rose to a little over 100 F. Four leeches were applied in front of the tragus. This morning patient feels better. The discharge is now profuse. Temperature normal. Patient is conscious of a constant escape of pus through the Eustachian tube into the back part of the nose. From the character of the matter expectorated (absence of mucus) and from the sensations experienced by the patient, I have very little doubt that the discharge referred to comes from the middle ear by way of the Eustachian tube. Swelling of inner end of meatus diminishing.

January 26th.—Continued improvement. Temperature, normal; pulse, 88. Tubal discharge diminishing; discharge by way of the meatus still active.

February 3d.—Patient is now entirely free from pain, and there is very little discharge from the ear.

February 14th.—The perforation in the drum-membrane has healed, and very little swelling of the parts remains. An insignificant scar indicates the location of the incision behind the ear. Watch heard at a distance of four inches.

CASE III.—The patient, a girl, six years of age, and of apparently delicate constitution, was seen by me for the first time on January 4, 1876. About four weeks previously she had passed through a pretty severe attack of pharyngeal diphtheria, from which she had scarcely recovered, when she began, about one week previously, to complain of pain in both ears. The pain, which soon became severe, had continued with unabated severity up to the time when I saw her, robbing her of sleep and of all desire to take nourishment. On the day when I was asked to see her she had been a little delirious at times. Temperature, 105° F.; pulse, 140. The deafness seemed to be almost total. Examination with the speculum and reflected light showed the right drum-membrane to be red and swollen in its upper portions, and somewhat bulging superiorly and posteriorly; the parts were perfectly dry. On the left side the external meatus was partly filled with masses of whitish moist epithelium. The drum-membrane was red and swollen. There was no redness, swelling, or tenderness of the mastoid integuments on either side. I made a free incision through the posterior half of each membrana tympani. Only blood was evacuated by the incision. Warm douche to be used freely, also poultices.

January 5th.—No improvement. Temperature, 105° F.; pulse, 140, and feeble; sordes on teeth; tongue dry; no discharge from either ear. Child lies as if in a state of partial coma. At the suggestion of Drs. Markoe and James R. Wood, who were called in to see the child, mercury was administered: internally, in the form of calomel, in small doses; externally, in the form of inunctions of the oleate of mercury (10 per cent.), frequently repeated. Bromide of potassium was also given, in conjunction with the calomel.

January 6th.—Yesterday the child was decidedly delirious, especially toward night, and cried out, at intervals, with pain (referred to the left ear chiefly). This morning, however, the child is very much better, an active discharge having established itself during the night in both ears.

From this time onward,—as I learned from her physician, Dr. A. A. Davis,—she made a rapid recovery, and regained her hearing almost perfectly.

CASE IV.—Male, twenty-one years of age, in good general health (New York Eye and Ear Infirmary), November 3, 1875. About three months ago he contracted a severe earache in the left ear from bathing in salt water. The pain continued to be severe for a period of two weeks, and then became bearable. About six weeks ago the pain again returned and has continued with, on the whole, increasing severity up to the present time. Besides the pain and deafness he has noticed a roaring sound in the affected ear, but never any discharge. The pain now involves the entire side of the head. On examination, I find the inner half of the meatus filled with a dark-colored material looking like a mixture of cerumen and pus. There is no appreciable redness or swelling of any part of the canal. The drum-membrane is covered with a tough, whitish material—undoubtedly a

soaked and thickened layer of epithelium—which completely conceals the outlines of the hammer. A V-shaped incision was then made in the membrane, but it was not followed by any escape of fluid. By lifting up the flap, it was observed that the middle ear was filled with a semi-gelatinous substance which very soon, however, became infiltrated with blood. Nothing abnormal observed in the region of the mastoid process.

November 6th.—Since last note there has been a constant discharge from the left ear. To-day, for the first time, the pain has been appreciably less severe than usual.

November 17th.—During the past few days there has been no discharge from the ear. The parts behind the auricle, however, have become tender and swollen. On examination I find the external auditory canal dry, and the perforation in the drum-membrane healed. The membrane has a tough, leathery appearance, and there are no evidences of inflammatory action in the immediate vicinity. The swelling behind the ear is found, on examination, to be due to the presence of a collection of fluid beneath the skin. Fluctuation can be felt, not only behind the ear but also above it. A free incision affords escape to quite a large quantity of pus, and the probe reveals the fact that it lay, at least in part, between the periosteum and the bone. While exploring the denuded bone surface, I discovered an opening, just large enough to admit the probe, at a point about an inch and three-quarters immediately above the tip of the mastoid process. The direction of the opening was upward, inward, and a little backward, and the probe passed into this bony canal a distance of half an inch without encountering any resistance. A fresh tent to be introduced into the wound daily.

November 20th.—Entire relief from pain since abscess was opened. Wound healing rapidly. Almost no tenderness in the vicinity. (No further data.)

CASE V.—Male, aged thirteen. February 23, 1885. Sharp ear-ache in right ear ten days previously, followed by a profuse discharge. Comparatively little pain since then, but the discharge continues to be profuse. Examination shows that the pus is escaping, not through the membrana tympani proper, but through a pouting orifice in the upper cutaneous wall, a short distance from the drum-membrane. Slight tenderness behind the ear. Temperature, 100.5° F. Douche to be used several times daily with a saturated solution of boric acid.

March 1st.—At noon to-day he had a slight chill; temperature, 104° F.; pulse, 92. The chill was followed by a noticeable increase in the amount of discharge. No increase in the mastoid tenderness.

March 2d.—Persistent vomiting and retching last evening. Mastoid tenderness more marked to-day; temperature, 102.4° F.

March 3d.—Marked diminution yesterday in the amount of the discharge. He has taken fifteen grains of quinine daily during the past two days. Yesterday he had a profuse sweat. This morning he began to complain of pain in the metacarpo-phalangeal joint of the left middle finger. With the pain was associated a small, well-defined red spot, which gradually spread and soon presented all the appearances of an acute inflammation of the joint. The least movement caused great pain in the part. On inquiry, I ascertained that he had never before had anything like rheumatism. Nevertheless, I put him on ten-grain doses of salicylate of soda every four hours.

March 4th.—The redness and swelling have not extended appre-

ciably beyond the limits of the knuckle. The pain in the part is already beginning to subside.

March 6th.—Patient passed a bad night, the pain in the right side of the head being severe. It is referred chiefly to the right temple. No redness or œdema of mastoid integuments, but still some tenderness over the upper portion. Calibre of the external auditory canal markedly reduced in size. Discharge still profuse, and now at times a little bloody. Perforation of bone advised.

March 7th.—He is again feeling better; temperature normal. Patient is given ether, and drill applied at usual spot. At a depth of half an inch the bone appeared to be noticeably softened. On breaking into the antrum, creamy pus welled up to the surface of the bone. In chiseling out the drainage groove I opened into some of the more superficial cells, which were found full of thick pus. In washing out the antrum I used an unusually strong solution of bichloride of mercury (1 to 1,000) and, as a good deal of it passed through the Eustachian tube into the pharynx, it gave him not a little discomfort afterwards for at least an hour.

Patient made a rapid and complete recovery, the discharge from the meatus ceasing entirely on March 9th, and the external wound healing permanently on or about April 1st.

CASE VI.—Infant, seven months old, and apparently healthy. (New York Eye and Ear Infirmary.) October 21, 1874. For some time past the mother had noticed that there was a discharge from the left ear. Three days ago the child began to be very restless, and the mother then discovered that there was a swelling behind the left ear. This increased quite rapidly in size, and to-day it causes a marked dislocation of the auricle forward. The skin covering this tense swelling is red, and fluctuation can easily be distinguished on palpation. An incision affords escape to about a drachm of thick, healthy pus. By means of the probe introduced into the wound it is ascertained that a carious sinus exists in the central portion of the rudimentary mastoid process. As the probe passes inward along this sinus a crumbling condition of its bony walls can be distinguished. Tent introduced into the wound.

October 24th.—The mother reports that since the operation the child has been, so far as she could judge, perfectly well. The external wound has not yet healed, but there is very little discharge from it, and the surrounding skin appears to be quite healthy. The discharge from the meatus has also diminished in a marked degree. (Child not seen again.)

CASE VII.—The patient, a resident of Orange, N. J., twenty-one years of age, of a healthy constitution, consulted me September 4, 1872, for a painful affection of the mastoid process. He stated that in June he was seized with a severe pain in the ear after bathing. The pain continued for three or four days, and then stopped, leaving him quite deaf in the affected ear. At the expiration of two weeks a discharge appeared, and this had continued since until the fourth or fifth day previous to his visit to me. Shortly before the discharge stopped, he noticed some tenderness behind the affected ear. The pain, which for four days had been growing steadily worse, was referred to the mastoid region, whence it extended upward and backward to the parietal and occipital regions. Tinnitus. Appetite poor. Countenance pale. Watch heard at a distance of four inches on the affected side. The skin covering the mastoid process red and swollen. External auditory canal diminished in calibre by the falling



forward of the posterior cutaneous wall. *Membrana tympani* invisible. Incision of the integuments covering mastoid process. Free escape of pus and blood. The periosteum was dissected up a short distance on either side, and the underlying bone seemed healthy. The following day, September 5th, while pressing pretty firmly against the bone with a steel director, it seemed to me that the point of the instrument met with less than the usual resistance. I then attempted to perforate the outer shell with a small steel drill, and in doing so suddenly exposed a large abscess which occupied nearly the entire mastoid process. The opening was further enlarged with a conical drill until the little finger could be admitted, and the contents were then entirely evacuated. Tent inserted and patient allowed to return to his home, where he said that he could get further medical treatment. The incision of the integuments on the previous day had already greatly alleviated his sufferings.

On the 14th of November following he wrote: "The pain never returned since you performed the operation, and the wound healed inside of ten days. I went to a doctor to have it dressed, but he refused to have anything to do with it, and said that it was a very dangerous operation, and might have killed me; so I went to a friend of mine and had it dressed. In ten days the outside was all healed, and I could hear a great deal better. Now I can hear my watch tick about twenty-four inches from my ear."

CASE VIII.—Male, twenty-eight years of age, and of robust constitution. (New York Eye and Ear Infirmary.) August 25, 1875. About ten days ago he began to suffer from pain in the right ear, after bathing in the ocean. A discharge soon made its appearance, but the pain has continued unabated up to the present time. On examination I find the drum-membrane red, swollen, and perforated. The skin covering the mastoid process is red, swollen, and tender when pressed with the finger. Free incision of the mastoid integuments; warm douche at home.

September 15th.—The incision afforded almost entire relief from pain. The wound, however, has not yet fully healed, and more or less tenderness still remains in the vicinity. The discharge from the meatus is abundant.

October 7th.—During the past few days the discharge has been slight, but the pain has returned and is now quite severe. It involves the entire right side of the head. There is still tenderness on pressure behind the ear, and the skin in this region is red and swollen. Patient having been brought under the influence of ether, the mastoid integuments were divided in the line of the former incision, and the drill was applied at the usual point on the surface of the process, where the periosteum was found to have become separated from the underlying bone throughout a limited area. After two or three turns the instrument suddenly entered an oblong cavity, estimated to be about three-fifths of an inch long (vertically) and about a quarter of an inch wide. The bone through which the drill passed felt appreciably softer than natural. As the bleeding from the external wound was quite active, it was impossible to ascertain whether the cavity referred to contained pus, or not. No fragments of bone were discovered. Tent introduced into the wound.

October 8th. Patient passed a comfortable night. Temperature, 99.5 F. Carbolic-oil dressings.

October 9th. —Quite sharp pain last night for a few hours. To-

day he feels again quite free from pain. Introduction of tent to be discontinued.

October 12th.—Decided increase of pain since yesterday. It is referred to the mastoid region. Pulse is to-day quite weak (104), and patient has a decidedly drowsy appearance. Temperature, 99° F. Three leeches to be applied behind the ear; afterward hot poultices.

October 18th.—A few days ago a swelling began to develop on the right side of the head, midway between the mastoid process and the occipital protuberance, but on a little higher level than the line drawn from the latter point to the external meatus. This swelling has steadily increased in size until now it forms a well-defined lump on the side of the head. On palpation distinct fluctuation is felt. The drowsiness noticed on the 12th still continues. At the same time the patient's countenance wears an expression of suffering. An incision through the centre of the circumscribed swelling afforded escape to about half a drachm of thick pus. By means of the probe it was ascertained that the pus lay between the periosteum and the bone. Pulse ranges from 76 to 84, and is fairly strong.

October 20th.—Decided improvement in patient's condition. He has lost his appearance of drowsiness, and says that the pain is very much less than on the 18th. Both external wounds still remain open. The discharge from the auditory canal has nearly ceased.

October 27th.—Patient again complains of pain in the right side of the head, more particularly toward the occipital region and in the temple. The wound made by the last incision has apparently healed, and no visible swelling remains, but tenderness on pressure still persists in this region. A probe directed backward and upward from the bottom of the mastoid wound passes easily onward a distance of an inch and a half without encountering any resistance. Firm pressure over the point reached by the end of the probe causes a few drops of pus to escape from the mastoid wound. During the past four days the patient has been able to leave his bed and walk about the ward.

November 20th.—Since last note patient's condition has changed very little. His general condition is good. The pain has moderated to such an extent that he no longer complains of it. The second wound is again open in the form of a very small sinus. Denuded bone can still be felt through both openings.

November 24th.—The two fistulous openings not showing any tendency to heal, I to-day connected them by a deep incision, thus converting the pus-secreting region into an open wound. The bone was found to be denuded over quite a large area, but at no point could anything like a carious process be made out. At one spot an opening in the bone was found. It led in an upward direction, and its upper edge was sharp and shelving. Whether this opening, which in a normal state probably afforded a passage for one of the emissary veins, in the present pathological condition of the parts furnished an outlet for the pus that had accumulated between the periosteum and the bone, I was unable to determine. Wound to be stuffed daily with charpie, for the purpose of favoring its healing from the bottom.

December 15th.—For several days past the patient has been entirely free from pain in the head. The wound is apparently healing permanently.

January 15th.—External wound has healed perfectly, and patient feels as well as he ever did.

### III. CHRONIC ULCERATIVE INFLAMMATION OF THE MASTOID ANTRUM.

From this class of mastoid affections come probably the greater number of fatal cases of ear disease. Through a period of months or, more commonly, of years, the patient is affected with a chronic discharge from the ear. The underlying disease begins as a simple purulent inflammation of the middle ear, and then, in the course of time, usually through the instrumentality of an obstructed outlet, the solid elements of the discharge—pus-cells, epithelium, detritus, cholestearin-crystals, etc.—begin to accumulate in the antrum. While these changes are taking place the mastoid cells are being steadily reduced in size by a chronic osteitis, and by the time that the accumulating solid matters have filled the antrum, the mastoid process will be found to have reached the condition of complete sclerosis. The natural outlet into the tympanum, and oftentimes the tympanum itself, become so blocked up with cheesy material, granulation tissue, etc., that conditions are afforded which are favorable to ulceration or caries of the surrounding bone. This ulceration of the walls of the antrum will take place in whatever directions the least resistance is met with. The directions in which the resistance is least are, first, upward toward the brain, and next, backward toward the lateral sinus. In one or both of these directions, therefore, a destructive carious process may be expected to take place, if a vent be not established by artificial means sufficiently early to prevent such an issue.

In this variety of mastoid disease, pain, at times severe, is the most prominent symptom. While in the previously described variety external evidences of the underlying mastoid disease are rarely wanting, in this form of the disease they are rarely present. On the other hand, one can usually find unmistakable evidence that the outlet through which the pus has been escaping from the middle ear into the auditory canal is too narrow to permit the discharge to escape freely from the more deeply situated cavities. The persistence of pain, therefore, under such circumstances, becomes a very important indication—in fact, often the only indication—of the severity of the deeper lying ulcerative inflammation. If we wait for the development of additional manifestations of this treacherous disease of the antrum before taking active steps to check it, we may rest assured that in many cases we shall let slip the golden opportunity of saving the patient's life.

Cases are now and then encountered in which, by skilful interference, we may succeed in clearing the antrum of its foul contents, and in re-establishing a free outlet for the secretions that

constantly accumulate in it, without boring through the outer portion of the mastoid process. As a rule, however, this is not practicable. In a general way, we may say that this form of mastoid disease admits of only one safe and effective plan of treatment, viz., that which consists in the establishment of a free channel of communication between the antrum and the outer air, through the mastoid process.

## ILLUSTRATIVE CASES.

CASE I.—On the 21st of September, 1872, I was asked by Dr. Herman Knapp to see with him, in consultation, a Mr. F., aged fifty-seven, and of a strong constitution. The history of the case was briefly this: During the previous ten or twelve years Mr. F. had had five distinct attacks of acute purulent inflammation of the left middle ear, from all of which he made a good recovery. The present attack began about seven weeks previously, and was characterized by headache and dulness of hearing, unaccompanied by discharge. On examination of the ear Dr. Knapp found the external auditory canal swollen, especially on the posterior side; the membrana tympani injected, and the mastoid process tender on pressure. In the progress of the disease, the membrana tympani becoming more congested and convex outwardly, the doctor incised it. No pus escaped, but the patient experienced relief from his suffering for about a week. The pain then returned, and the integuments covering the mastoid process became swollen. The patient also noticed a gurgling sensation in the ear, whenever he shook his head. An incision down to and through the mastoid periosteum afforded only temporary relief. The pain again became severe. At the consultation (September 21st) it was decided that perforation of the mastoid process was the only course that offered any hope of recovery. The patient, however, refused to have the operation performed.

September 22d.—Up to this time there had been no brain symptoms, but to-day, being called in haste to see the patient during the absence of Dr. Knapp from the city, I found him unconscious, pupils non-responsive, face flushed, and head very hot; pulse about 120, and full; breathing stertorous. The friends were then willing enough to have the operation performed, but it was clearly too late. The patient died the same night.

At the post-mortem examination, purulent basilar meningitis was found, together with a free communication between the mastoid antrum and the cavity of the lateral sinus. The two formed together an irregularly shaped cavity filled with pus. The pus did not extend down into the jugular vein, nor back toward the torcular Herophili. Both these portions of the vein contained venous blood. Sclerosis of the mastoid cells. Membrana tympani entire.

CASE II.—Female, twenty-nine years of age, in fair general health (New York Eye and Ear Infirmary), February 10, 1875. She states that she has been subject to a discharge from the left ear since childhood. About six months ago a "tumor" was discovered in the affected ear. Several attempts were made at different times to remove this "tumor," but it constantly reappeared. Of late she has experienced a great deal of pain throughout the entire left side of the head. The pain has been especially



severe at night, and at times has been accompanied by what she describes as "brain fever." Occasionally she has experienced a sensation as if the left eyeball were being pushed out from its socket.

On examination the meatus was found to be blocked by the presence of a mass of granulation-tissue. After removing the greater part of this growth with the snare, I discovered, by aid of the probe, that it sprung from the posterior wall of the meatus, near the junction of the cartilaginous with the osseous portion, and that its point of origin was close to the orifice of a sinus that led quite a distance inward and a little upward and backward. In its course the probe, which did not seem actually to enter the substance of the mastoid process, encountered denuded and crumbling bone. No redness or swelling of the skin behind the ear. Moderate tenderness on pressure over the lower part of the process and also over that portion of the skull which is situated immediately in front of the occipital protuberance.

She was advised to become an in-patient of the Infirmary, in order that she might receive better care than it would be possible for her to receive at her tenement-house home. She readily consented and was assigned to a bed in a separate room.

February 13th.—Pain still continues. Patient having been etherized, the mastoid integuments were divided, and the bone perforated with the larger drill to a depth of three-fifths of an inch. No pus or softened bone encountered. Anteriorly, however, the periosteum was found to have become separated from the underlying bone, thus allowing the probe to pass easily along the surface of the bone into the meatus.

February 14th.—Marked relief from pain.

February 16th.—Decided swelling and tenderness in front of and above the auricle. Motions of the jaw cause pain in the region of the ear. Temperature nearly normal.

February 20th.—Since last note patient has had an attack of syncope, lasting about one hour, and requiring the use of stimulants. To-day she is in about her usual condition. Her temperature varies from 98.5° to 99.5° F. The pain in her head is nearly constant. The parts around the ear still remain swollen. The polypoid mass in the meatus having grown to such a size as to obstruct the free escape of pus from the deeper regions, I removed the larger part of it to-day with the snare.

February 24th.—This morning patient had two epileptiform seizures of short duration. The swelling in the vicinity of the ear has diminished quite noticeably. The pain, however, continues. When asked in what part of the head she felt the most pain, she replied at once, in the left eye. Her answers to other questions were at times almost unintelligible. She would begin her answer and then stop as if trying to think what else she should say. Temperature remains at about 99° F. Profuse sweats. Occasional vomiting.

February 26th. She is now very restless, and force has to be used to keep her in bed. Her mind wanders constantly, and she no longer pays any attention to questions addressed to her. The right eye is drawn outward and the right upper lid droops. Temperature, 101° F.

She died the same night. The discharge from the ear continued to be abundant up to the very last. No post-mortem examination was allowed. By means of the probe, however, I ascertained that the inner and posterior bony walls of the tympanum

were denuded and roughened. The bent probe passed upward and backward, through what felt like a small opening in the tegmen tympani, into the cranial cavity.

I have very little doubt that, in the case just narrated, an abscess of the brain existed already at the time when the patient first entered the Infirmary; but at that early period of my experience with this class of cases I did not fully appreciate the two important points to which I have already called attention, viz., that in long-continued purulent inflammation of the middle ear, with obstructed drainage, one may confidently assume the existence of sclerosis (condensing osteitis) of the mastoid cells, and that it is useless to do anything less than to establish a very free communication between the antrum and the outside world. The establishment of such a free communication would probably, in the present instance, not have saved the patient's life. Nevertheless, it was the thing which ought to have been done.

In the preceding description of mastoid diseases, I have endeavored to portray only well-defined types of these affections. I will now recapitulate very briefly the main distinctive features of these diseases, in the hope of rendering this branch of the subject still clearer. The first variety of the mastoid disease—sub-acute, condensing, mastoid osteitis—is really nothing but an accompaniment of an ordinary, chronic, purulent inflammation of the middle ear. An acute exacerbation of such a chronic otitis media purulenta is very often the direct exciting cause of a more than usually active condition of such a condensing osteitis. It is only, therefore, on grounds of practical utility, and for the purpose of giving greater prominence to the idea of a condensing osteitis, that I feel justified in treating it as a separate form of mastoid disease. It does not immediately threaten either the life or the health of the patient. It may not even cause pain, and under such circumstances we are not likely even to have our attention drawn to the fact that the disease is present. In a few instances, the single symptom of pain becomes a prominent feature of the disease—so prominent, indeed, that we may be obliged to resort to operative interference in order to secure for the patient the desired relief. Here, then, we have a well-defined and very important accompaniment—if not type—of mastoid disease. But its importance does not cease here. The chief result of this condensing osteitis is the obliteration of the pneumatic cells of the mastoid process. In ulcerative disease of the antrum, therefore, this condensing osteitis plays an important part. It commonly prevents the development of certain symptoms which are of great diagnostic value, and at the same time it interposes a solid wall of bone between the cavity of the antrum and the outer air, thereby greatly enhancing the serious character of an ulcerative inflammation of that cavity.

The second and third varieties differ in these respects: in the former the pneumatic cells participate in the inflammation of the antrum, while in the latter they play no part as a separate system of cavities, but a very important one as a wall of bone impenetrable to ulcerative processes.

SIGNIFICANCE OF CERTAIN PHENOMENA OCCASIONALLY MET WITH IN DISEASES OF THE MASTOID PROCESS.

In addition to the symptoms ordinarily encountered in these cases there are others which occur only in exceptional cases. Thus, for example, partial or complete paralysis of the facial nerve sometimes develops during the progress of either the second or the third form of mastoid disease. It is probably brought about by the pressure of an effusion that has been poured out into the bony canal through which the facial nerve passes. That such an effusion should take place, shows that the inflammation of the bone in the vicinity of the antrum has reached a serious degree of activity. The symptom is therefore of decided diagnostic value. In some cases permanent paralysis remains after the mastoid disease has entirely subsided, while in others every trace of the paralysis disappears in the course of a few weeks.

Sometimes the tissues on the side of the neck, a short distance below the tip of the mastoid process, become inflamed, and swell rather rapidly into a hard, flattened, and very sensitive tumor. The skin covering this matted cake of inflamed glands and other soft parts lying outside of the muscles of the neck, is red, œdematous, and firmly adherent to the underlying tumor. I have sometimes observed that the development of such a swelling takes place simultaneously with a decided subsidence of the pain in the mastoid region and side of the head, and for this reason I have been disposed to believe that some of the acrid secretion contained in the antrum or pneumatic cells must have found a way of escape through one of the canals for the mastoid emissary veins, thus diminishing the degree of pressure within the mastoid process, and at the same time exciting, by its acrid properties, a sharp inflammation of the tissues into which it first escaped. It is also possible, as suggested by Dr. J. Orne Green, of Boston, that a phlebitis of one of the mastoid emissary veins may be the cause of such a swelling of the soft parts below the mastoid process. By the frequent application of hot flaxseed-meal poultices, I have known such swellings to disperse without the development of an actual abscess. However, if pus forms, the knife must be used.

In several cases I have observed the development of an abscess, or at least of a circumscribed area of inflammation, in some part of the scalp of the corresponding side of the head. I believe that

any part of the scalp may become the seat of such an abscess, or of such a localized inflammatory swelling, as I have encountered them in very different regions, viz., in the vicinity of the occiput, on the very top of the head, midway between the top of the head and the mastoid region, and in the temporal region. It seems to me reasonable to suppose that the lymphatics carry some of the acrid secretions from the mastoid cavities to these different localities, thus starting, by transportation, new centres of inflammation. In opening such abscesses I have sometimes been annoyed by the profuseness and obstinacy of the bleeding.

Septicæmic manifestations are not common in mastoid affections, nor yet are they by any means rare. Their occurrence may be interpreted as signifying obstructed drainage from the inflamed area, with consequent entrance of some of the products of inflammation into the circulation. The acute inflammation of the knuckle, in the case narrated on page 318, appears to me to have been a septicæmic phenomenon, due to the lodgment of a minute septic mass in one of the capillary blood-vessels of the part; this septic particle having found its way into the circulation through some ulcerated blood-vessel of the mastoid antrum or neighboring cells. In a few cases I have observed, when the disease was at its height, the development of a cough, which I interpreted to signify a septicæmic or pyæmic condition. One or more chills, or a sense of chilliness, with fever and sweating, were further characteristics of these bronchial attacks. As some of these cases afterward recovered, despite these very serious symptoms, I am convinced that Schwartz's rule, not to operate when pyæmia has set in, must be somewhat modified. In the main, the rule is probably a good one, but it should not be allowed, in certain exceptional cases, to deter us from perforating the mastoid process.

As a rule, the body-temperature may be taken as a measure of the activity of the disease in the mastoid process. This is particularly true of youthful subjects. In adults, however, we must not allow ourselves to be lulled into a sense of security by reason of the absence of noticeable fever. In one of my cases, which terminated fatally (probably from abscess of the brain), the temperature, during the last thirteen days, did not rise above 100° F. until shortly before her death. Delirium does not necessarily indicate a fatal issue. Coma and strabismus, on the other hand, are more grave symptoms, for they point clearly to the development of intra-cranial processes which are quite likely to terminate in death.

#### TREATMENT.

The moment we have gained a reasonably clear conception of what is the nature and extent of the disease which we are called



upon to treat, the course which we ought to pursue lies clearly marked out before us. We should ask ourselves, first, this question: Is the outlet for the discharge, by way of the external auditory canal, as free as it can be made by any reasonable operative interference? If obstructions still remain,—if granulation-growths or masses of epidermis and pus block the way, or if the opening in the membrana tympani be too small,—these hindrances should be removed. This advice, however, must not be interpreted to mean that I approve of excision of the soft parts or of the ossicles for the purpose of improving the drainage from the antrum in cases of acute inflammation of the middle ear (whether primary or grafted upon a chronic subacute inflammation, is of no great consequence). This idea of securing better drainage from the antrum by way of the external auditory canal at one time seemed very fascinating to me, and I accordingly made bold to give it a trial in two somewhat similar cases. The results, however, were disastrous. In one of these cases I did succeed in improving the drainage a little, although to a far less degree than I anticipated; but I also had the misfortune to destroy the hearing of that ear, presumably through dislocation of the stapedio-vestibular joint. The bleeding from incisions made in the inflamed soft parts at the posterior end of the tympanic cavity is apt to be profuse, and after the first step in the cutting we are obliged to proceed literally in the dark. Hence the great risk of encountering the very same experience which I encountered. In the second of the two cases referred to, the hæmorrhage was so profuse from the swollen tissues that I only partially succeeded in improving the channel of communication between the antrum and the external auditory canal. Furthermore, the reaction was so prompt and so violent that in the course of two or three days no trace whatever of the opening which I had made could be discovered in the inflamed and swollen soft parts. The patient insisted on returning to his home, and within less than a fortnight from the time of the operation the news came that he had succumbed to a basilar meningitis, which soon involved the convex portions of the brain. Had I advised the ordinary plan of procedure, the perforation of the mastoid process, instead of the more innocent-looking but really more dangerous short-cut method, I fully believe that my patient's life would have been saved. Such excisions can only be made with some degree of safety in individuals whose ears are perfectly free from active inflammation.

Our next question should be: To what stage has the inflammation of the mastoid structures progressed? If we have reason to believe that the parts are simply congested, we may trust to the application of from two to five leeches, according to the

age and strength of the patient, and afterward to a thoroughly carried-out system of hot poulticing. The leeches may all be applied directly over the mastoid process, or some of them may be applied at that point and the others directly in front of the outer orifice, as close as possible to the tragus. As I have already stated elsewhere, Bacon's artificial leech may be used with at least equal advantage instead of the ordinary medicinal leeches. Rest in bed is a far more important feature of the successful treatment of these acute affections of the ear than is generally believed. On the other hand, if our minds are somewhat in doubt about the wisdom of trusting to these simpler and less powerful measures, or if we have tried them and they have failed to relieve the pain, we should promptly resort to a "Wilde's incision." In this operation, the skin and subjacent tissues, including the periosteum, are divided by an incision extending from the base very nearly to the apex of the mastoid process, the external wound measuring from three-fourths of an inch to an inch in length. If the patient's head is in the erect position, the point of the knife should be introduced into the skin about on a level with the upper wall of the external orifice of the auditory canal. If we begin the incision higher up, we shall be apt to divide a branch of the posterior auricular artery, which usually crosses the bone at about that level. On the other hand, if we make the incision a little too far forward, we may nick this artery or incise it longitudinally, and so prepare the way for the development of a false aneurism, as has already twice happened, once in my own practice and once in that of Dr. Charles J. Kipp, of Newark, N. J. After the bleeding from the wound has ceased,—and, within reasonable limits, the more protracted and the more copious the bleeding the better,—I usually introduce a small tent well smeared with vaseline, for the purpose of preventing the wound from healing by first intention. Hot flaxseed-meal poultices should then be applied to the mastoid region as often as may be found necessary to keep the parts warm and moist for a continuous period of three or four hours. As Sir William Wilde, of Dublin, Ireland, was the first to call attention to the decided restraining influence which such deep incisions of the mastoid integuments exert upon an inflammation of the body of that bone, it is eminently proper that the name of "Wilde's incision" should be retained for this most efficient therapeutic procedure.

Finally, in those cases in which the pain has persisted steadily for several days, and has perhaps resisted all the measures that may have been adopted for its relief,—and in which all the local signs point quite clearly to a serious degree of inflammation in the body of the mastoid process,—we should proceed without further delay to establish a broad opening in the outer part of this bony

prominence. Before describing in detail the procedures by which such an opening may be established in the bone, I will rehearse briefly

*The Indications for Resorting to Perforation of the Mastoid Process.*

Schwartz, of Halle, in Prussia, who has probably had a larger experience in operations upon the mastoid process than any other surgeon living, lays down the following rules in regard to the indications which call for perforation of this bone. I quote them as they are given by Dr. J. Orne Green, of Boston, Mass.

"1. In acute inflammation of the cells, with retention of pus, if oedematous swelling, pain, and fever do not subside after antiphlogosis and free incision. 2. In chronic inflammation of the mastoid process with subacute (periosteal) abscesses, or fistulæ in the mastoid. 3. With a sound cortex of the mastoid, on account of cholesteatomata or purulent retention in the middle ear, which cannot otherwise escape, and with which symptoms arise showing that the life of the patient is in danger; or when a congestive abscess has formed in the upper posterior wall of the meatus. 4. When the mastoid appears healthy and there is no pus in the middle ear, but when the mastoid is the seat of long-continued and unendurable pain which other means fail to relieve.

"The operation is of *doubtful* utility in old, incurable middle-ear secretion, when no symptoms of inflammation of the mastoid nor of purulent retention in the middle ear exist. It is contra-indicated when there are positive symptoms of already existing metastatic pyæmia, or of secondary meningitis, or of cerebral abscess."

My own experience leads me to express my entire approval of Schwartz's rules, with the exception, perhaps, of that relating to cases in which meningitis or metastatic pyæmia has developed. Farther on, I will refer to this point more particularly. However, when we come to apply any fixed set of rules, at least in private practice, we shall find that all sorts of circumstances will compel us to modify them somewhat. Among cases of ear disease in which the mastoid process is more or less involved, there are such great differences that one may correctly say that no two cases are ever exactly alike. This circumstance renders it exceedingly difficult to formulate rules which are likely to be of much use to one who sees mastoid disease rarely. By aid of the history of the case, and of the condition of the drum-membrane, or rather of the visible parts in the immediate vicinity of the drum-cavity,—and here I have reference especially to the upper and posterior part of the cutaneous lining of the auditory canal in close proximity to the drum-membrane (*i.e.*, the skin covering

that portion of bone which constitutes the bony floor of the antrum);—by aid, furthermore, of the condition of the skin covering the mastoid process itself (redness, swelling, tenderness); by aid, to a slight degree, of the thermometer; by a consideration of the time which has elapsed since the onset of acute symptoms; in a word, by the aid of all these things we must endeavor to answer this question, Has the inflammation of the middle ear, antrum, and communicating bone-cavities progressed so far, and acquired such a momentum of virulence, that we may feel reasonably confident that none of the simpler therapeutic measures—such as leeching, poulticing, Wilde's incision, or the free use of the knife on the drum-membrane—will suffice to arrest the progress of the disease, to ward off the dangers which at this late stage are associated with it, and to restore the parts to health? Some years ago I formulated what I thought were very simple and practical rules for guidance in the matter of operating on the mastoid process. Further experience has taught me that, while in the main these rules will be found useful, in not a few exceptional cases they will not be found to be adequate. These rules, which had reference only to cases of comparatively recent origin, are as follows:

"In the early stage of the disease, when there is persistent and rather severe deep-seated pain, perhaps involving the entire side of the head as well as the parts immediately surrounding the ear, and when there is tenderness on pressure over the mastoid process, and possibly also a little redness of the skin, we should apply to this region from four to eight leeches, according to the age and vigor of the patient. If the loss of blood has not produced any decided depressing effect upon his strength, the after-bleeding may be allowed to continue for half an hour or one hour. Warm fomentations should then be kept applied to the mastoid region for several consecutive hours. If these measures fail to afford the desired relief, or if, after the lapse of say twenty-four hours, the pain is found to be as active as it was before the leeching, a Wilde's incision should then be made without further delay. Finally, if this procedure also fails to relieve the pain, or if it relieves this symptom only temporarily, an opening should as soon as possible be established in the mastoid process."

The question might be raised by some physicians, whether they should interpret this rule as meaning that, in the event of their failing to alleviate the pain by the other measures enumerated, they ought to perforate the mastoid process as early as on the fifth or sixth day after it has shown signs of being inflamed. As a matter of course, the rule is not to be followed blindly, nor without due consideration of all the facts connected with the case. Circumstances undoubtedly may exist which would render

it desirable to modify the rule. For instance, the condition of the external auditory canal or drum-membrane, on the fifth or sixth day, may be such as to render it advisable that we should then devote special attention to this region before we adopt the conclusion that the mastoid process should be perforated. But if no such valid contra-indicating reasons exist, I believe that the sooner the operation is performed the better it will be for the patient. In actual practice, it will rarely happen that, in following the rule which I have laid down, and which is essentially the same as that which I published in 1873, we shall find ourselves called upon to perforate the bone as early as on the fifth or sixth day. The vigorous employment of leeches is usually followed by a remission of the pain for from one to two or three days; and a still more protracted lull is apt to follow Wilde's incision. In this way the question of an operation upon the bone does not usually present itself for serious consideration before, say, the tenth day, at the earliest.

In all cases of comparatively recent origin we must not forget one well-established fact, namely, that the majority of them will, in one way or another, get well without the aid of perforation of the bone. In some, recovery will take place after weeks or even months of suffering; in others, it will take place through the establishment of a fistula behind the ear, and this in turn may persist for many months; again, in others, recovery indeed follows, but only after irreparable damage has been done to the hearing; finally, in a few individuals, who are blessed with unusually large mastoid pneumatic cells, which communicate freely with each other and with the antrum (see Fig. 84), and are separated from the outer periosteum and integuments by only a very thin lamina of bone, a spontaneous recovery (through softening of this outer shell of bone and escape of the pus by way of a fistulous channel in the skin behind the auricle) will take place promptly and without permanent damage to the hearing. As there are no statistics at hand which give the exact proportion of deaths to recoveries among the cases of acute mastoid disease not treated by the operative method, it is not possible to show, by the statistical method, exactly how urgent is the need for operative interference.

If delirium, drowsiness, or limited paralysis develop in a case in which, judging from its history and from the conditions observed in the ear, we have already concluded that perforation of the mastoid process would be a useful procedure, we shall certainly be justified, in the presence of these new symptoms, in placing the urgency of operative interference in a much stronger light; that is, we may now unhesitatingly state that without the operation the chances of recovery are likely to be very small. We shall also

be justified in advising the operation with the same degree of urgency in a similar case in which pyæmic symptoms have developed, even though coma, delirium, and paralysis may be lacking. Schwartz, it will be remembered, says that the operation is "contra-indicated when there are positive symptoms of already existing metastatic pyæmia, or of secondary meningitis, or of cerebral abscess." If the symptoms of any of these conditions are really positive and well-defined, in a case that in other respects seems to require operative interference, I should certainly feel that the time had gone by when a useful purpose would be subserved by making an artificial opening in the mastoid process. On the other hand, successful results have followed mastoid operations in individuals in whom the symptoms of meningitis or of pyæmia were fairly well marked. It is therefore important carefully to weigh the circumstances of each case, and not lightly to reject an operation which may save life.

Finally, I believe that the operation should be urged as indispensable to life and health in those cases of chronic discharge from the ear which have been characterized by frequently recurring and severe attacks of pain on the same side of the head, and in which our examination leads us to believe that ulcerative action, with insufficient outlet for the pus toward the middle ear or the external auditory canal, is going on unchecked. In cases of chronic discharge from the ear, however, the question of when perforation of the mastoid bone should be resorted to, is far more difficult to answer than in the acute cases. The tenderness on pressure behind the ear, and the redness and œdema of the skin in this region, are very often, if not generally, lacking. In these cases, therefore, we are obliged to fall back upon the previous history, upon the appearances presented by the drum-membrane and neighboring parts, and upon the presence, never wanting, of deep-seated pain.

Here, then, are three classes of cases, some of them of acute origin and others of a chronic nature, in which I believe that all good surgeons would be of one mind in regarding the operation as advisable and more or less urgent. But there are other cases in which Schwartz and other surgeons—among whom I should wish myself to be included—would also urge the necessity of an operation; not because they believe that without it the patient cannot recover, but simply because they believe that it offers the speediest and the most effective means of putting him out of danger, of relieving him from his suffering, of preserving the hearing of the affected ear and of restoring him to health. In consultations I have, a number of times, been overruled in regard to this point, and have then sometimes seen the patient get well under the employment of less radical therapeutic procedures.

In most of these cases, however, the recovery has been tedious and the patient has suffered, as it seemed to me, a great deal of unnecessary pain which the operation would have prevented. At one time, after two or three experiences of this kind, which occurred within a comparatively short period of time, I made up my mind that I would adopt a policy of delay, and not operate until it was reasonably clear that nothing but the perforation of the bone would put the patient out of danger. Shortly after this I was called to see a young man who had been suffering with severe pain in the ear for a period of nearly four weeks. There was pus in the middle ear, but the drum-membrane, owing to the toughness of its texture, had not ruptured, and consequently there had been no visible discharge from the ear. There was marked tenderness and redness of the mastoid integuments, and marked redness and swelling of the posterior and upper cutaneous wall of the auditory canal in the vicinity of the drum-membrane. Taking into consideration the long duration and the severity of the pain, and the local evidences of inflammation involving the mastoid cells, I made up my mind that the only proper course to pursue was to make an opening down to the antrum, thereby relieving the parts of all tension, establishing a free and more direct route for drainage from the inflamed region, and so giving my patient, as I thought, the best chance of recovering his health and his hearing. My courage, however, had been so weakened by the recent rebuffs which I had experienced, that I simply advised paracentesis of the drum-membrane, a Wilde's incision, and poulticing. These measures were carried out and the patient speedily improved. In fact, ten days after this date I found him feeling so well that I discontinued my visits. Five days later, however, I was sent for in haste, and found that the patient, after a dancing party, had been seized with severe pain in the affected ear and throughout the entire side of the head. He had passed a night of suffering, his temperature was high, and there was a little tenderness over the mastoid process. This time I unhesitatingly urged the desirability of an operation, and it was performed on the same day. To my great surprise, I found that the entire mastoid process, which was one of unusually large size, was converted into an abscess cavity, all traces of mastoid cells having already disappeared. From this time forward the patient made a rapid recovery, but during the years which have since elapsed he has in many ways acted so strangely, and so unlike his former self, as to lead to the belief that the brain must have experienced some slight damage during the weeks which elapsed while this abscess was developing in its immediate vicinity.

The case just narrated is not the only one in which I have been surprised to find a great disparity between the outward

manifestations of mastoid disease, and those found after an opening had been made in the bone. In fact, on two occasions, in cases of quite recent origin, I found no redness of the skin behind the ear, no tenderness on pressure, and no demonstrable swelling of the parts, and yet, on perforating the bone, I found it to be in the condition which I have just described.

In the light of all these facts, I am convinced that it is not practicable at the present time, nor is it ever likely to be practicable, to formulate a rule by means of which we shall always be sure when the proper time has arrived for operating upon the mastoid bone. Every surgeon will have to decide for himself, in each individual case, whether or not the operation in question is called for. If he must err either way, it is far better that he should err in the direction of occasionally operating when, perhaps, an operation might be dispensed with; for to err in the opposite direction means the loss of a life that probably might have been saved, or at least the infliction of a chronic and disagreeable affection of the ear.

#### STEPS OF THE OPERATION.

*The External Incision.*—The hair having been closely shaved from the side of the head immediately above and behind the ear, the incision is to be begun at a point on a level with the top of the auricle and on a line (vertically) with the orifice of the external auditory canal. At first the knife should be carried a short distance backward in a horizontal direction, and then it should be turned so as to cut vertically down as far as to the tip of the mastoid process. Sufficient pressure should be made with the point of the knife to divide the periosteum throughout the full extent of the incision. In this manner we shall obtain a flap which may be dissected up from the underlying bone, thereby freely exposing the latter throughout the entire area in which we desire to carry out our operative procedures. The posterior auricular and perhaps one or two other minor arteries will be divided by the incision, but it is an easy matter, where we are dealing with such a flap, to ligate the bleeding vessels. There is also apt to be a copious oozing of blood from the wound. To stop this troublesome bleeding it is well to have at hand a large vessel filled with water as hot as the hand can bear. By filling a sponge with this hot water and wringing it out over the wound, the bleeding can usually be controlled in the course of a few minutes.<sup>1</sup>

<sup>1</sup> In this connection I may mention a circumstance which has attracted my attention. I refer to the rapid development of a very marked difference in thickness between the opposite edges of the wound: the anterior lip or flap sometimes attaining almost twice the thickness of the posterior one, in the course of an hour or two. This phenomenon is probably to be attributed to the cutting off of the blood which supplies the posterior flap. In the course of a few days there is developed a sufficient collateral blood-supply, and the difference in thickness then disappears.



*A Comparison of the two Methods of Perforating the Mastoid Process.*—The next step in the operation is the perforation of the bone laid bare in the manner just stated. Before describing how this perforation is to be made, it will be well for us to rehearse briefly once more what such an opening is expected to accomplish and to enumerate the different ways in which it may be made. The main object to be secured by an operation upon the mastoid bone is the establishment of free drainage from the antrum, *i.e.*, from the middle ear. Free drainage puts a stop to

the dangers of a too long-continued intra-tympanic pressure, and affords an easy egress to any decomposing substances (cheesy pus, cast-off epithelium, and necrosed fragments of bone) that may be lodged in some part of the tympanic system of cavities.

This object may be attained in two ways: (1) a direct cylindrical channel of adequate size may be made in the bone, down to the antrum, by means of a suitably constructed drill; or (2) the outer portion of the process may be chiselled away in such a manner that the wound in the bone shall represent roughly a shallow cone, the base of which corresponds with the outer surface of the mastoid process, while the apex reaches into the antrum. Both of these methods have been thoroughly tried, and it has been shown that just as good results may be secured by the former as by the latter plan of procedure. Hitherto, I have been a strong advocate of the employment of the drill (the pattern shown in Fig. 89), for the reasons that it had

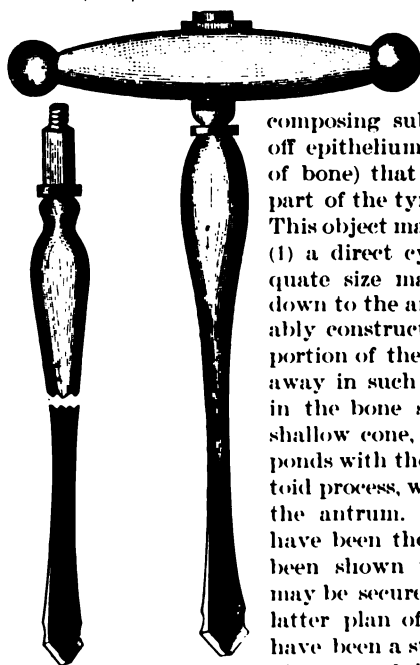


FIG. 89.—Bone Drills. (The two larger sizes.)

always proved to be a thoroughly safe instrument in my hands and in those of my colleagues; that the duration of the subsequent healing process was, on the average, much shorter than in the cases in which the chisel had been used; and, finally, that the resulting scar behind the ear was far less conspicuous than that following the chiselling operation. Furthermore, the arguments brought by the advocates of the latter operation against the employment of the drill were so conspicuously unfair, that it was difficult for me not to espouse the cause of the drill more warmly than I might otherwise have done. My attention, however, has recently been called

to one or two aspects of the question under discussion which lead me to admit that on the whole the employment of the chisel or gouge is the preferable plan of operating. Here are two of the points referred to:—The operation must often, perhaps in the majority of instances, be performed by men who do not own a suitably constructed drill, and who, besides, are probably not so familiar with the anatomy of the temporal bone that they may be safely trusted to bore into it to the depth of say three quarters of an inch. Hence an operation like that with the chisel, in which every step of the procedure is conducted in open sight, is rather to be recommended for general use than one in which the correct guidance of the drill depends upon individual skill and knowledge of the anatomy of the parts. The second argument is based on the fact that the channel established by the drill may provide ample drainage for the antrum and middle ear proper, but may fail wholly to drain some isolated collection of pus in the mastoid process not touched by the instrument in its inward course to the antrum. The great destruction of bone-tissue necessitated by the conical shape of the opening made by the chisel, renders it almost impossible for any collection of pus to remain isolated and unopened after the antrum has been reached.<sup>1</sup> For these reasons, therefore, it seems to me wiser that the drilling operation should give place to that by means of small chisels and gouges.<sup>2</sup>

A complete set of chisels and gouges, suitable for the operation in question, is shown in the accompanying figure. Fig. 91 represents a form of mallet which may be conveniently and effectively used in driving the chisels. A wooden one, however, will answer the purpose almost equally well. In cutting away the bone, in the first part of the operation, the chisel should be placed against the outer surface of the process at a point about opposite to the antrum, and, as Schwartz very properly recommends, the blows with the mallet must be struck in a direction which forms a decidedly acute angle with the surface of the bone. It is only in this




FIG. 90.—Schwartz's Bone Chisels and Gouges. (About one-third actual size.)

<sup>1</sup> The large cells situated near the tip of the process may not be opened directly in the chiselling operation, but cells adjacent to them are usually opened, and these latter are very apt to communicate freely with the former. This free communication can, I believe, be trusted to supply adequate drainage for these larger cells.

<sup>2</sup> Those who wish to learn further details in regard to the drilling operation, will find the subject fully discussed in the Transactions of the American Otological Society, for 1887, in the article on Mastoid Operations in vol. iv. of the Reference Handbook of the Medical Sciences, and in my former treatise on Diagnosis and Treatment of Ear Diseases.

way that the operator can avoid communicating to the brain a series of shocks which might do some damage. Anteriorly, immediately behind the shelving posterior edge of the orifice of the external auditory canal, it will be found necessary to cut away the bone in a plane nearly at right angles to the outer surface. While everywhere else the chisel should be placed nearly flatwise against the surface of the bone, at this particular point the flat part of the chisel must form a right angle with the surface; the actual cutting, however, must be done from above downward, or from below upward, and not directly from without inward.

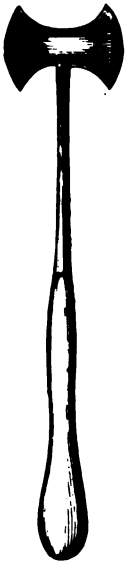

FIG. 91. - Lead-filled steel mallet, with slender shank. (Considerably reduced in size)

The chiseling, as already stated, should begin directly above that point on the outer surface which lies directly opposite the antrum, the blows of the mallet being directed downward and slightly inward. As the chisel is moved farther backward, the blows should be directed more anteriorly than inferiorly. Finally, on arriving at a point directly below the starting-point, and from a quarter to three eighths of an inch distant from it, the chisel should be directed upward and slightly inward. The area of bone removed by this part of the chiseling will probably not exceed that of a silver three-cent piece, and will be bounded posteriorly by a line more or less circular in shape, while anteriorly the boundary line will be approximately a straight line. Further progress is to be made by chiseling away more bone at the posterior and inferior parts of the opening thus started. In this way only is it possible to reach a sufficient depth without changing the angle at which the chisel is made to strike the bone. Step by step, in this manner, the bone is to be chiseled away until the antrum is reached. At the beginning the largest size of chisel or gouge is used, but as the antrum is approached it will be found necessary to use the smaller sizes. Toward

the end of the operation a small pattern of Volkmann's spoon will be found useful in reaming out the opening into the antrum and in smoothing down any rough spots left by the chisel.

When pus is encountered in the superficial mastoid cells, it is not a safe thing to assume that it is not necessary under these circumstances to keep on chiseling until the antrum is reached. The communicating channels between the latter and the outlying mastoid cells are often so narrow as to be wholly inadequate for good drainage. Our only safe course, therefore, is to reach the antrum in every case.

To locate the position of the antrum, advantage may be taken

of certain fixed points which are in view before the operator. Thus, for example, the principal fixed point is the curving bony margin of the orifice of the external auditory canal. By crowding the anterior flap of the wound well forward, a good view of this curving edge may be obtained. The antrum, as will be seen by study of Fig. 84, is situated at the intersection of two planes: a vertical transverse plane which passes in close proximity to the posterior part of this curving margin, and a horizontal plane which passes through the upper part of the same bony margin. The linea temporalis is another fixed point which will prove useful in preventing us from locating the antrum at too high a level; for this cavity lies below the level of this curving line.

After a free opening has been established in the antrum, and after all jagged surfaces have been properly smoothed, a careful search should be made in the antrum and immediate vicinity for chips or fragments of bone. For this purpose the smaller-sized curette with rounded edges will be found a useful instrument. The next step in the operation is to inject a tepid (about 100° F.) solution of bichloride of mercury (1 part to from 3000 to 5000 parts of water) into the antrum and middle ear by means of a nozzle appreciably smaller than the artificial opening made by the chisel. Such a nozzle is shown in the accompanying cut. In addition to washing out the antrum we should irrigate thoroughly every part of the wound with the bichloride solution. Then the soft parts should be readjusted as accurately as possible in their natural relations, and two or three deep sutures should be used in holding the opposite edges of the horizontal upper part of the wound in close apposition. As the strain upon this part of the wound is very great it is important that careful attention should be paid to this step of the operation. The vertical portion of the wound is to be left open. The German surgeons recommend that a drainage tube be introduced through this part of the wound into the antrum, or at least as far inward as to the orifice of the artificial opening into the antrum, and left there for a period of several weeks. My own experience justifies me in saying that this procedure is entirely unnecessary. In fact, I believe that it only serves to prolong materially the healing of the wound.

The final dressings should be as simple as possible. A small piece of sheet-lint, dipped in a weak solution of bichloride of mercury and anointed with carbolated vasoline, may be laid over




FIG. 92.—Curved Hard Rubber Nozzle, for use in washing out the Mastoid Antrum. (Actual size.) The soft rubber tubing of Davidson's syringe, or of a fountain douche, may be slipped over the lower end.

the wound, and over this a mass of borated cotton, extending well down over the side of the neck and back toward the occiput, should be placed. A piece of mosquito-netting, the size of a large handkerchief, can then be adjusted to the head, in the form of a cap, and fastened under the chin by means of safety-pins. Such a cap will hold the dressings firmly in place, and will not heat the patient's head unduly. After suppuration is well established, a fresh cap should be used with each renewal of the dressings.

During the first four or five days after the operation, it is advisable to wash out the antrum at least once a day with the weak bichloride solution, but if by that time no symptoms of septicaemia have shown themselves, and if there is a free discharge of pus from the wound, I believe that the injections may be stopped altogether. My idea in regard to this point is this: immediately after the operation there are, undoubtedly, a number of small blood-vessels left gaping in the substance of the bone. So long as they remain in this condition there is, of course, danger that poisonous materials may enter through them into the general circulation. Hence the desirability of employing antiseptic irrigation. But when the processes of suppuration and granulation are fairly well established, we may assume that these vessels are all closed, and that the danger of septic poisoning no longer exists. Of what use, then, is it to go on distressing our patients with this procedure, which always causes more or less pain? If it be said that the risk of blood-poisoning continues for a much longer period, I can only reply that I have followed this practice in at least a score of cases, and have seen no reason yet to change my belief that the plan advocated is a safe one to follow.

The subsequent progress of the healing process is uneventful. It is generally necessary to excise and suppress (with the solid stick of silver nitrate) exuberant granulations, and now and then a small sinus persists for weeks, or even months, before the final healing takes place. Sometimes, again, after perfect healing has apparently taken place, the painful symptoms return, a small abscess forms in the region of the cicatrix, and a fragment of necrosed bone is discharged. Then the parts quickly heal again, and no further trouble is experienced. Finally, in other cases, with every fresh cold in the head involving the middle ear of the affected side, evidences of inflammation show themselves in the mastoid integuments, and even in some cases this inflammation may progress so far as to cause a discharge to take place from the old cicatrix. Under favorable circumstances, however, we may expect cicatrization of the external wound to take place in about a month's time; in exceptional cases it may take place even earlier. By the fourth or fifth day following the operation, provided the body-temperature has returned to the normal and everything else is favorable, the patient may begin to sit up.



## CHAPTER XIII.

### MISCELLANEOUS CONDITIONS OF THE DRUM-MEMBRANE, OSSICLES, AND TYMPANIC CAVITY.

*Atrophy of the Membrana Tympani.*—In the condition known as atrophy of the membrana tympani, we find this membrane usually thin and transparent, and at the same time more concave than natural. In its slighter degrees one may very easily fail to recognize this condition. In such doubtful cases of atrophy the behavior of the membrane under inflations of the middle ear will often aid us very materially in arriving at a correct diagnosis. Thus, for example, if atrophy exists, an undue convexity of the membrane (after the inflation) and a certain peculiar opacity (like polished steel just breathed upon), due to the undue stretching of the outer dermoid surface of the membrane, will at once attract the attention of the observer. Furthermore, I think one is less likely to err in estimating the degree of unnatural convexity than in determining that of undue concavity. After inflation of the middle ear, a non-atrophied drum-membrane should present but a very slight degree of convexity, even when the Eustachian tube is so obstructed as to keep the air engaged in the cavities of the middle ear. The lesser degrees of atrophy are very common. A high degree of this condition is observed in cases of chronic nasopharyngeal catarrh, with hypertrophied tonsils and follicular enlargements. Prolonged undue atmospheric pressure upon the outer surface of the membrane is the cause of the atrophy in these cases. In cases of sclerosis of the mucous membrane of the middle ear, we find an atrophy of the membrane which seems to differ from that which I have just described. The membrane is apparently just as thin and transparent as in the other form of atrophy, but it seems to retain its substantia propria unchanged; for the membrane is at most very little sunken, and inflation does not cause it to bulge to an unnatural extent. This condition, as it appears to me, may be explained in the following manner: The atrophy is probably limited to the mucous lining of the membrana tympani; though perhaps the process of contraction may at the same time interfere with the circulation of blood in this membrane to such an extent as to diminish materially its entire blood-supply.

So far as the *diagnosis* is concerned, the only other condition

that might be mistaken for atrophy is a newly produced drum-membrane. The presence of other evidences of an otitis media purulenta, either in the affected ear, or in its fellow, or the history of a previous otorrhœa, would favor the diagnosis of a cicatricial membrane; while the absence of these, especially if the condition of the throat and Esutachian tube pointed to the previous existence of active disease in these localities, would favor the diagnosis of simple atrophy.

No treatment of which I have any knowledge is likely to restore an atrophied drum-membrane to its normal state; nor do I know of any procedure that will render it less elastic, that is, more capable of responding to the vibrations of the air. I have not the slightest faith in frequently repeated incisions.

*Horny Growth of the Membrana Tympani.*—I have seen but one case of this peculiar pathological condition.

The patient, a man thirty-six years of age, was admitted to the New York Eye and Ear Infirmary on the 21st of June, 1871. He stated that fourteen years previously, during exposure to severe weather, he first began to be troubled with noises and slight deafness in both ears. These symptoms had continued since, though at times they were less marked than at others. In both cases the watch could only be heard at a distance of two inches; in conversation with him, however, I was not obliged to raise my voice appreciably. On inspection I found the external auditory canal filled with hard inspissated cerumen. To facilitate the removal of these hard plugs of wax, the patient was instructed to fill the ears night and morning with a warm solution of bicarbonate of soda (gr. x. — ʒ j.). Three days later the cerumen was easily removed by syringing. On examination, the drum-membranes then presented the following appearances: On the left side there was nothing specially noteworthy; on the right, the upper three-fourths of the membrane was occupied by a flattened, sharply outlined mass of a pale yellow or yellowish-white color. It stood out from the level of the membrane to a distance of a little more than a millimetre, and terminated, throughout its entire lower border, with abrupt edges. Along its upper and anterior boundary, the mass became gradually merged in the skin of the auditory canal. Its surface was smooth and slippery, and, when touched with the probe, conveyed the impression of being quite hard. The portion of the membrane that was not covered by the mass, was of a uniform milky appearance, similar to that which is frequently observed in cases of chronic catarrh. With a view to obtaining more light on the nature of this mass, I instructed the patient to continue the use of the soda solution for another week. At the end of this period I found the mass practically unchanged. Its surface had been rendered slightly soft by the prolonged soaking, but I could discover no other change.

My interpretation of this case was, that the mass represented a horny growth from the dermoid layer of a limited portion of the membrana tympani. It has also seemed to me probable, or at least possible, that the long-continued pressure of a ceruminous plug might have been the exciting cause. (See also Fig. 93.)

*Vascular Growth of the Membrana Tympani.*—In a young lady, twenty-two years of age, who consulted me for a slight general impairment of her hearing, I found in the posterior superior quadrant, just behind the short process of the hammer, and encroaching a little upon this bone, a small, rounded, bright-red fleshy mass, about as large as a No. 12 shot (*i.e.*, about a millimetre or a millimetre and a half in diameter). It appeared to be quite soft, and was feebly movable when manipulated with the probe; at the same time it was not pedunculate. In the present instance this vascular nœvus possessed no significance beyond that of a mere pathological curiosity; and yet there is no good reason why, at some future day, a more extensive tumor of this kind may not be found growing from the membrana tympani.

In the case of a lady, sixty-five years of age, I found, in the central portion of the posterior superior quadrant of the left tympanic membrane, perhaps a trifle nearer the posterior fold than the manubrium mallei, and surrounded by a narrow zone of normal drum membrane tissue, a dark object which stood out in bold relief from the outer surface of the membrana tympani. I manipulated this object with a slender silver probe, and in this way ascertained that it was sufficiently soft to yield to the pressure of the instrument, that it was shaped like a mole or a teat, that it measured about one millimetre in diameter at its base, and projected a distance of at least one millimetre from the plane of the surrounding membrane, that it was not noticeably sensitive, and that the transition from the black of the tumor to the grayish white of the healthy drum-membrane was abrupt.

In the right ear I found a similar vascular new-growth in almost precisely the same region of the tympanic membrane. It was smaller, however, than that of the left ear. While the latter represented a perfect vascular mole, of diminutive proportions, the former consisted simply of a low, hemispherical eminence, recognizable more by its dark color than by any change which it caused in the configuration of the drum-membrane.

Beyond these two cases I have had no experience with vascular growths of the intact drum-membrane, nor have I found a record of any similar case in the text-books.

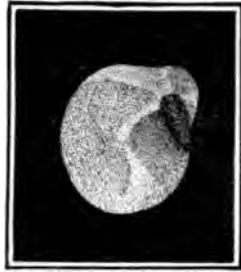

FIG. 93.—A blackish conical mass, looking like crumen, lay in front of the right drum-membrane, with its outer part touching the anterior wall of the meatus. When seized with the forceps it was found to be attached to the short process, but was removed by slight torsion and traction. It proved to be a cuticular horn, 6 mm. long and 2 mm. in diameter, composed of cap-like layers arising from the short process. No reaction or recurrence followed its removal. (Copied from Randall.)



...in size and  
 small (diameter: 2 mm.), circular, translucent  
 which occupied, so far as I could judge, exactly  
 as that which the drum-membrane should  
 merged imperceptibly into the surrounding  
 no landmarks of any kind by means of which  
 whether this membranous structure was a re-  
 brana tympani, or a membranous transformat  
 inflammatory tissue. Its situation certainly  
 view. The hearing-power in L. ear was fair.

**Absence of the Hammer.**—In examining the  
 the New York Eye and Ear Infirmary, I was v  
 to find that the drum-membrane, which seen  
 constructed in all other respects, totally lack  
 mallei. On questioning the man, I ascertain  
 years previously an operation had been perfor  
 form) on that ear, but that it had failed to r  
 deafness. From this statement, and from the c  
 I drew the inference that excision of the entire  
 ably been performed. In this case I searched  
 cicatricial tissue in the location which the m  
 occupy, but I failed to find the slightest differ  
 portion of the membrane and the surrounding

**Hook-shaped Manubrium**  
 peculiar deformity observed in  
 was probably of congenital



FIG. 94.

The patient, a boy thirteen  
 admitted to the New York  
 Infirmary on the 15th of May,  
 years old he had passed the

stitute a comparison between the two sides. The boy was in robust health, and presented no signs of ever having had rickets.<sup>1</sup>

*Ruptures of the Drum-membrane.*—In my experience, ruptures of the membrana tympani, from concussion of the air in the external auditory canal, are comparatively rare. I can find only five instances of this lesion in my records. In two of these the rupture was produced by a "box" on the ear, in two others the patients seemed to be unwilling to divulge the cause (one of them, however, stated that she fell down stairs, but I was satisfied that she was trying to deceive me), and in the fifth case the patient was struck on the ear by a snowball. In two cases the rupture ran directly downward and a little backward, in a line directly continuous with the handle of the hammer. In other words it consisted in a mere separation of the radial fibres of the substantia propria. In the third case it ran from a point near the periphery of the posterior superior quadrant directly downward in a straight line to a point near the periphery of the posterior inferior quadrant, as shown in the accompanying cut (Fig. 95), drawn from one of Dr. Randall's cases. In the fourth case the perforation ran in a slightly curved line from the lower limit of the posterior superior quadrant (midway between the umbo and the periphery) to the central portion of the anterior inferior quadrant. Finally, in the fifth case, the rupture occupied the posterior inferior quadrant and consisted of an irregularly shaped opening with jagged edges. In three cases the appearance presented by the rupture was simply that of a reddened line, without any visible solution of continuity, while the parts were at rest. In the fourth case there was slight gaping of the edges. In the case of the rupture produced by the impact of a snowball the opening showed no tendency whatever to close. I saw it as late as six months after the occurrence of the injury, and it was still in a gaping though perfectly dry state. In one case, a discharge of short duration followed the injury. Finally, in

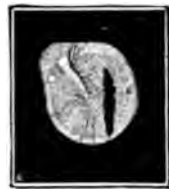

FIG. 95.—Rupture of the Left Membrana Tympani. A vertical gap extends almost across the posterior half of the membrane, and the vessels are full, especially behind the manubrium. (After Randall.)

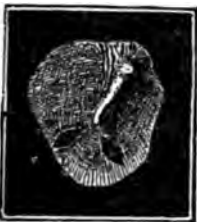

FIG. 96.—Double Rupture of Right Membrana Tympani in a Woman of Thirty, produced by a fall upon the ear—seen on the third day. The two tears have radiating directions, and show marked gaping. (Pollitzer.)

two cases, hæmorrhagic infarctions were found in the vicinity of the rupture. Double ruptures are of rare occurrence. One such

<sup>1</sup> A case of abnormally bent manubrium mallei has been reported by Buhl and Hubrich in the *Monatsschrift für Ohrenheilkunde*, II., 1, January, 1868.

instance is shown in the accompanying cut copied from Politzer's work (Fig. 96).

In the unique case reported by Dr. Robert F. Weir<sup>1</sup> the membrana tympani was ruptured horizontally, at a point about midway between the short process and the tip of the handle of the hammer, and at the point corresponding with the line of this rupture the handle of the hammer was found to be fractured.

*New-growths in the Middle Ear.*—In this category I propose to consider only those new-growths which depart so markedly from the ordinary type of aural polypoid tumors that it would be scarcely proper to consider them in the section devoted to the proliferative form of otitis media purulenta. Of the benign growths, the bony and the vascular are the only ones that have come under my observation.

*Marked hyperostosis* of the bony wall of the tympanum is, in my experience, a very rare condition.

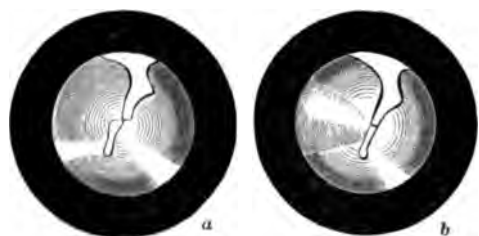


FIG. 97. Ununited Fracture of the Manubrium, the handle being broken at about its middle, and the lower fragment displaced backward (a). Valsalval Inflammation corrected the displacement (b), but it soon recurred. (Weir's case.)

I have seen but two instances of it, both of them in middle ears that had previously been affected with a chronic purulent inflammation. In the first case the bone in the neighborhood of the fenestræ had in-

creased so greatly in size that the posterior half of the drum-membrane presented a tense, polished, convex outer surface, due to the pressure of the subjacent bony growth. The handle of the hammer marked the anterior limit of the tumor, and rested firmly against it. The anterior half of the drum-membrane seemed to be cicatricial in character, and abnormally sunken. The patient was sixty-two years of age, and said that he had been quite deaf for at least thirty years. In the second case a hemispherical bony mass, apparently about five millimetres in diameter at its base, overhung the tympanic orifice of the Eustachian tube (right ear). Posteriorly it touched the stump of the handle of the hammer (the drum-membrane having been completely destroyed). The mucous membrane covering the tumor was still recognizable as a distinct, more or less succulent membrane. The patient was six-

<sup>1</sup> Transactions of the American Otological Society, 1870. Consult also, in regard to injuries of the drum membrane, Schalle, in Archiv. für Ohrenheilkunde, XII., p. 10; Burnett, in Transactions American Otological Society, 1872; Politzer, in Wiener Medicin. Presse, 1872; Bürkner: Archiv für Ohrenheilkunde, XIV., p. 290; Shaw: Boston Medical and Surgical Journal, November, 1868; Turnbull, in Medical and Surgical Reporter, Philadelphia, February 22, 1870.

teen years old, and there had been a discharge from the right ear for a period of fully seven years.<sup>1</sup>

*Intratympanic vascular growths* are probably encountered even more rarely than are those of a bony nature. So far as I can learn, there are but four instances on record in which a vascular tumor developed in a middle ear whose drum-membrane was still intact, viz., one reported by Schwartz,<sup>2</sup> two by Weir,<sup>3</sup> and one by myself.<sup>4</sup> In Schwartz's case very few details are given. The left drum-membrane, which was otherwise white and lustreless, presented a pulsating point near the umbo. The pulsations were synchronous with the radial artery, and ceased during the performance of Valsalva's experiment. From the meagreness of the details given, it is not even quite clear that the case belongs in the present category. In both of Dr. Weir's cases, however, one of which I had the privilege of examining at my office, and also in my own case, the evidence of the existence of an intratympanic vascular growth is reasonably clear. In view of the rarity of tumors of this nature, I will give in full the histories of these three cases.

*Dr. Weir's first Case.*—"Mrs. J. A., *æt.* 35, was sent to me in November, 1870, by Dr. J. T. Metcalfe, for deafness of the right ear, which had begun about a year previously, had rapidly increased during the past few months, and was associated with a disagreeable though regularly pulsating noise. There had been no pain or discharge. At times slight attacks of vertigo had been experienced.

"On examination, H. D. right side= $\frac{K}{8}$ ; left, normal. After I had removed a slight layer of cerumen, a remarkable appearance presented itself. The whole drum-membrane was evenly and intensely reddened and strongly pushed forward in a bulging manner, except along the line of the malleus, which was situated apparently in a depression, and was marked at its free end by a white spot, in strong contrast to the other parts of the membrane. The whole membrane pulsated visibly and strongly, especially so superiorly, where there was a broad light spot. The pulsation was synchronous with that of the carotids, and was arrested by pressure on the artery of the corresponding side. No distinct vessels were to be seen on the membrane, only a general redness. By Siegle's tympanoscope the drum-membrane could be forced in but little, and the pressure only rendered the pulsation more broadly and decidedly marked, and particularly so near the inner side of the malleus. By the otoscopic tube the heart-sounds were distinctly heard, but not so on the sound side. No air could be felt to enter the tympanic cavity by Valsalva's or Politzer's method, nor by the catheter. No redness or abnormal change was noticed in the external auditory canal.

"Thinking at first that I had to do with an exaggerated case of bloody serum in the middle ear, paracentesis was resorted to at

<sup>1</sup> Consult also Zaufal, in *Archiv für Ohrenheilkunde*, II., p. 48; Moos, in *Archives of Ophthalmology and Otology*, II., pp. 127 and 130.

<sup>2</sup> *Arch. f. Ohrenh.*, I., p. 140.

<sup>3</sup> *American Journal of Otology*, vol. I., p. 130.

<sup>4</sup> *Ibid.*, p. 130.

the middle of the posterior segment, giving exit to blood which rapidly filled up the canal and flowed to the amount of  $\frac{3}{4}$  j. in a few seconds, but was easily arrested by plugging the canal for a few moments with cotton. Attempts were made to inflate the tympanic cavity by the catheter, after bougieing the Eustachian tube up to its isthmus, but no air emerged from the puncture. On inspection no change in the appearance of the drum-membrane had resulted from the puncture, but three days later, when paracentesis was again resorted to, and after the cessation of a moderate hemorrhage, the drum was found collapsed and somewhat wrinkled; the hearing also was found to have increased to  $\frac{1}{2}$  ft. This improvement in hearing and condition of the drum-membrane only continued until the next day, and the pulsation was then felt as decidedly as ever by the patient, though to the eye it was much more feeble. I had by this time come to the conclusion that I had to deal with a vascular tumor in the middle ear, or that I had, according to Schwartze, a hypertrophied condition of the mucous membrane associated with an accumulation of bloody serum in the cavity. Leaning, however, to the first view, a consultation with Dr. Simrock, an acknowledged aural authority, was suggested and carried out. Dr. Simrock thought that the difficulty was due either to fluid in the middle ear, or, as he thought that he succeeded in forcing air through the Eustachian tube, that it was a collection of fluid in the tissue of the drum-membrane itself. A third puncture was made posteriorly, carrying the needle in until it reached the promontory—no air could be forced out. Convinced of the correctness of my diagnosis, on December 5th, a fourth puncture was made with a large needle, and a probe dipped in pure nitric acid was inserted through the opening into the middle ear. But little pain was occasioned by this treatment. As a result of the several punctures, it was noticed not only that after each the hearing-distance increased, but that the pulsation became less distinct. This subsidence became more and more permanent, but the cicatrices of the punctures, yielding under the pressure from within, protruded almost teat-like from the drum-membrane, and after this application of acid a mass projected through the opening there made, and, spreading out and pulsating faintly, obscured nearly the whole membrane, and assumed a polypoid appearance in the course of a week. This mass was punctured, and a probe dipped in liq. ferri persulph. introduced into its depths, blanching it at once.

"The subsequent history is in brief this: the mass sprouting from the opening in the drum-membrane was with difficulty destroyed by the use of nitric acid applied, first, every second or third day for a number of times; afterward, at intervals of one or two weeks (as the patient lived out of the city); and subsequently, as the tissue became tougher, by the use of the acid nitrate of mercury, which was carried, by means of a thin film of cotton around the end of a fine wire, through the tympanic opening into the cavity itself. At times considerable pain was caused by the applications, but as a rule they were less distressing than would have been anticipated. Several attempts were made to extract pieces of the mass for microscopical examination, and the one or two small portions so obtained were reported, by Dr. A. H. Buck, to show nothing but scales of epidermis and debris, so changed by caustics as to be unrecognizable.

"By this treatment, the tumor, in the course of four to five months, was apparently destroyed, and it was observed that in

the later cauterizations little or no hemorrhage occurred, and that when the punctures and applications—for they were sometimes conjoined—were carried into the tympanic cavity, the sensation was given that that space was more or less filled with a solid tissue. No air at any time was felt in the middle ear.

“On July 1, 1871, three weeks after the cessation of treatment, it is noted that H. D. =  $\frac{1}{16}$ ; bottom of canal closed by a smoothly depressed, fleshy-looking membrane, still considerably though irregularly injected. No pulsation whatever to be seen or heard by the physician, and only very slightly perceived by the patient.

“August 4th.—Mrs. A. presented herself, on her way from Newport, stating that she had had only occasional pulsation in the ear in the erect position, but always when in bed. On examination it was found that the membrane had changed from its former fleshy appearance to one more normal. Now the malleus could be defined; the membrane itself was still irregularly patchy, of a pink hue in spots, but with some translucency. By the use of Politzer's inflation, for the first time air is heard to enter the middle ear by the otoscope. Ordered Valsalva's experiment to be practised at home.

“November 14th.—Drum-membrane is quite normal in the posterior part. Malleus clearly seen. Anteriorly, two months ago, was seen a red bulging spot, as if the tumor was returning there, but this to-day is not seen; the drum-membrane at this point being now mottled with white bands running from the malleus to the periphery. Tube slightly open by Valsalva's method; air readily enters. H. D. =  $\frac{1}{16}$  to  $\frac{1}{8}$ . To use Politzer's bag daily.

“February 7, 1872.—H. D. =  $\frac{1}{16}$ . Only hears pulsation when in bed. Drum-membrane still mottled and sparsely injected. No evidence of return of tumor.

“December, 1878.—No recurrence of the tumor. Reports herself as hearing well. Ear giving her no trouble whatever. As patient was met in the street, exact information could not be obtained.”

*Dr. Weir's second Case.*—“A negro woman, thirty-five years of age, was seen by me December 8, 1870, with the history that for four years past she had had ‘beating noises’ in the left side of her head, which were much increased by stooping, which position would also cause severe dizziness. Vertigo came on at times in the erect position. The hearing on the same side had also failed, and on her visit to me was  $\frac{1}{16}$ , while on the left side it was normal. She believed that her heart was affected, as she so distinctly and so persistently heard the sounds in her ear. There was, however, no cardiac lesion. She was much depressed and anxious by reason of her ear trouble. On inspection it was perceived that the posterior surface of the drum-membrane, and more especially its inferior portion, was of a reddish hue, with some vessels running over it, and that it was not only bulged outward, but that it visibly pulsated synchronously with the heart. Considerable injection of the malleus was also present. The Eustachian tube was pervious. By Siegle's otoscope it was seen that a faint line half-way up the posterior segment was movable. Paracentesis was, therefore, resorted to, and blood rapidly filled the canal, but was readily checked by a mop of cotton left a few moments against the drum. Politzer's inflation being then used, air freely escaped through the opening in the drum-membrane, after which H. D. =  $\frac{1}{16}$ . She was not seen again until June 1, 1871, when she re-

turned with the statement that since the puncture she had been very much better, and her hearing had improved and kept in fair condition until a week previously, when the latter rapidly diminished. Now H. D. =  $\frac{1}{5}$ . Left drum-membrane translucent everywhere, except at postero-inferior portion, where a roundish red spot, the size of a small pea, was seen projecting forward, but not pulsating. By Siegle's apparatus fluid line was again detected; it was rendered more clear after Politzer's inflation had been successfully used. Projection outward apparently the same.

"June 15th.—Paracentesis used for a second time, causing not only H. D. to rise to  $\frac{1}{6}$ , but also disappearance of the pulsating noise and redness. This absence of pulsation was noticed only a few days.

"August 1st.—Returned with symptoms of dizziness, deafness, and pulsation. Fluid seen in tympanic cavity. Redness and pulsation in drum-membrane observed as at first. Paracentesis, with needle carried in until it was arrested by bony resistance.

"November 7th.—Repeated paracentesis. Says that after every puncture the sound is lessened in intensity.

"December 11th.—Paracentesis twice in past week, and a probe wet with liquor ferri persulphat. also introduced.

"She was not seen subsequently until February 18, 1873, when the tumor was seen projecting still on the posterior and inferior segment of the drum, pulsating, and of a red color. Dizziness complained of more than ever. H. D. = 0.

"Up to March 24th, paracentesis was performed three times, with the subsequent introduction of cotton wound around a cotton probe and dipped in acid nitrate of mercury. This kept the opening patent, and several applications through it of a solution of chromic acid (100 gr. to  $\frac{3}{4}$  j.) were made. Pulsation scarcely seen, and heard much less distinctly by the patient. Dizziness has also ameliorated.

"April 25th.—For the past three weeks she has been free from vertigo and pulsating noises. After a rest of two weeks after last state, a new and long slit was made in the drum-membrane, and the chromic acid freely applied in the drum-cavity by the cotton probe. Considerable swelling and discharge followed. This has nearly all subsided and she feels better in her head than she has felt in five or six years. She can now stoop down and do her work without an unpleasant pulsation.

"June 25th.—Has had the paracentesis and chromic acid used but twice since last note. She has steadily improved, having had no pulsation and no dizziness until about ten days ago, when both were noticed after violent exertion. By the speculum the lower part of the drum was found to be quite normal, save a few cicatricial traces. At the upper part posteriorly and advancing a little forward on the roof of the external auditory canal, is seen a reddish mass about two lines wide and about three long, not pulsating, but evidently an extension of the angioma. She was then going into the country, and promised to return to me in the autumn if any further symptoms arose. She, however, did not do so. I have recently heard of her death in 1875, from phthisis.

"From her friends I learn that the noises in her ear slowly increased, and for several months prior to her death they caused her much annoyance and distress."

*Author's Case.*—Female, æt. 33, anæmic in appearance, and with œdema of the lower extremities. March, 1871. Patient states that two months previously she began to be troubled with

a peculiar noise in the right ear, resembling in character—as she described it—the croaking of a bull-frog. This noise came at regular intervals, synchronous, as she had noticed, with the heart-beat. She had never experienced pain in the ear, and could not remember ever to have had an otorrhœa. She had also never noticed any difficulty in hearing. On examination with the speculum and reflected light, the following condition of the parts was found: the meatus was normal. The membrana tympani was moderately sunken. The handle of the hammer was whitish and sharply outlined. In the anterior superior quadrant the membrana tympani appeared to be perfectly normal; in the posterior superior quadrant it was so transparent that the long process of the anvil and head of the stirrup could be plainly seen through it. The entire lower half of the membrane presented a uniform and rather vivid red color, as if an exudation of blood or bloody serum lay upon its inner side. Such, at all events, was the diagnosis made at the time. Paracentesis was suggested, but the patient felt too weak and miserable to have anything done.

On the 17th of September, 1873, patient presented herself at the New York Eye and Ear Infirmary for the second time. Her story then was that two years previously she experienced some pain in the right ear, and afterward observed that her hearing in that ear was very imperfect. From that time to this there had been a constant, pulsating, roaring noise in the affected ear. On examination it was found that she could no longer distinguish the ticking of the watch in the right ear. The membrana tympani was found to have undergone the following changes: the lower half of the membrane was still as brightly red as in 1871 but at the umbo, passing from before backward, the upper boundary line of the red region ran upward and backward, instead of straight across. The posterior half of the membrane—chiefly the lower two-thirds—was now markedly convex and pulsated synchronously with the pulse at the wrist. Suction with Siegle's apparatus gave marked relief for the moment, but the throbbing instantly returned when the instrument was withdrawn. I advised against active interference at that time. Patient never returned.

Drs. Henry D. Noyes and Charles Laight verified the condition as described above.

The points of interest and importance in this case may be briefly enumerated as follows:

1. The development of a new-growth in the middle ear, without any apparent cause for such growth (such as inflammatory irritation), either in the past history or in the present condition of the ear.
2. The highly vascular character of the growth.
3. The slowness of its development.

The growths described in the preceding section were strictly intratympanic, and furthermore they developed as it were spontaneously, without the provocation which an irritating purulent secretion is capable of affording. In the case which I am about to describe there was ample provocation for the development of some form of new-growth, but it is not clear why a strictly vas-



cular growth—to which I have given the name of angioma cavernosum—should have been developed. Virchow, in his admirable treatise on tumors, devotes nearly two hundred pages to the consideration of vascular new-growths. He subdivides the angioma into a number of varieties, and applies the term cavernosum to that variety which is characterized by the existence of a network of blood-spaces, occupying the place and fulfilling the functions of capillaries. According to his view, the arteries, in a growth of this kind, pour their blood into these spaces, from which it then passes into the veins, and so back into the general circulation. Such a growth as this, on a small scale, came to my notice in the practice of the New York Eye and Ear Infirmary.

The patient, a mechanic, nineteen years old, was admitted as an out-patient on the 2d of April, 1870. He stated that from the time when he was seven years old to that time he had been affected with a discharge from both ears, and with frequent earaches. He had also been very much troubled by all sorts of noises in his ears. Recently, he said, the noise in the left ear had been what might be termed a pulsating, humming noise. It had been constant, but at regular intervals, corresponding apparently to the pulse-beat, it would become louder. Running upstairs, or any other violent exercise, would aggravate the noise very much. When he awoke, on the morning of the day on which he visited the Infirmary, he found his pillow covered with blood, which was still escaping from his left ear. The hæmorrhage, which was not associated with even a trace of pain in the ear, continued throughout the entire forenoon. Up to the time of which we are now speaking, the patient had never seen any blood in the discharge from either ear. On examination I found the left meatus filled with blood, partly fluid and partly clotted. I removed it by syringing out the ear, and then, on examination, I found that an oblong, dark-colored body, about the size of a small pea, was lying, apparently free, on the lower wall of the meatus. On closer inspection, however, I discovered that it was attached by a long and slender peduncle to the stump of the hammer. Dr. Robert F. Weir, in whose department the patient belonged, then divided the peduncle with slender scissors. No hæmorrhage of any account followed. Almost immediately after its removal, the small growth was placed in a weak solution of chromic acid, the only preservative fluid that happened to be at hand at the time. Later, it was transferred to a bottle containing alcohol.

On the 25th of June the patient reported that, about the middle of May, the noises and the discharge had both returned, and had continued ever since. On examination of the left ear, I found a pinkish, vascular teat dependent from the stump of the hammer, and standing out in marked contrast with the pale mucous membrane which formed the background.

When the specimen had been sufficiently hardened in alcohol, it was imbedded in a mixture of wax and oil in equal parts. No special precautions were taken to place the tumor in such a position that the sections through it should include either the point of rupture or the stump of the peduncle; but, fortunately, the middle sections included both of these points.<sup>1</sup> I will not at-

<sup>1</sup> Fig. 65, on p. 265, represents one of these sections.

tempt in this place to give a minute description of the anatomy of this tumor, but will simply state that it was found to consist almost entirely of blood-vessels, which radiated from an irregularly shaped central cavity, and which were separated from each other by a network of fibrillated connective tissue holding blood-corpuscles in its meshes. In some of the sections a large blood-vessel could be followed from the central cavity into the peduncle. In one of these, and also in other sections, the point of rupture could be distinctly traced from the central cavity to the periphery of the tumor. As the patient was asleep at the time when the hæmorrhage took place, it must be assumed that it occurred through natural causes, operating within the tumor itself. The constant pressure, which first produced the marked dilatation of the blood-vessels, and then an obliteration of their walls at different points, and eventually led to the formation of the large central cavity, must have been the chief agency in producing the final rupture of the peripheral portion of the tumor. Virchow's view, that an angioma is an independent new-growth of vessels, just as much as an exostosis is an independent new-growth of bone, finds strong confirmatory evidence in the fact that, six weeks after the original vascular tumor had been removed, a second one, of precisely the same vascular character, was found growing at the same spot.

*Malignant Tumor of the Middle Ear.*—Cancer or sarcoma of the middle ear is fortunately an extremely rare affection. Thus, for example, so far as I can learn, only one case of malignant disease of the middle ear had been reported<sup>1</sup> in this country, prior to the publication of a case by Dr. H. Knapp, in December, 1879. As this case was under my care for several weeks during Dr. Knapp's absence from the city, and as it is the only instance of malignant disease of the tympanum that I have seen, I will give here a brief sketch of it.

The patient, a man thirty-seven years of age, and in poor physical condition, consulted Dr. Knapp on the 7th of May, 1877. The conditions which were found at that time are thus described by Dr. Knapp:<sup>2</sup> "Below and in front of his right ear there was a tumor the size of a hen's egg, which he had first noticed six or seven years previously. It had increased very slowly at first, but quite perceptibly during the last six months. His left ear was affected with chronic otorrhœa, without pain or any symptoms of irritation. His right ear never discharged, and he could always hear well with it until three days before he came to me. At that time he went to bed feeling and hearing as well as ever, but on awaking the next morning, he found that he was deaf.

"*Condition at First Visit.*—When the left ear was closed, he could understand ordinary speech at the distance of five feet, and hear the watch tick when in contact with the right ear, the right mastoid process, or the forehead. There was no diminution of sensibility or mobility in the face or any part of the body, and his mental faculties were undisturbed.

"The right membrana tympani was uniformly bluish red,

<sup>1</sup> By Dr. Robertson, of Albany, in the Transactions of the American Otological Society for 1870.

<sup>2</sup> In the Archives of Otology, vol. viii., No. 4, December, 1879.



slightly convex, and greatly dislocated forward. The cone of light was absent, but there was a dull, roundish reflex on the posterior lower part. The malleus was seen in its ordinary direction from above forward to below downward, but its tip lay less deep in the canal than the short process. Neither the drum-head nor the adjacent parts of the ear-canal showed increased sensibility to the touch, and the drum-head yielded to the probe as if a soft substance, harder than liquid, were behind it.

"When, the next day, I found the condition of the patient unchanged, I made an incision with a paracentesis-needle into the drum-membrane, in front of and below the handle. The edges of the wound at once retracted, and through the gaping opening I saw a reddish, fleshy growth, filling the whole space behind the displaced membrana tympani. The cut surface showed that the membrana tympani was not thickened. The incision caused no particular pain, liberated no pus, serum, or blood, but gave rise to considerable hemorrhage, and did not improve the hearing. When touched with a probe the tumor gave the sensation as of a somewhat soft, fleshy mass.

" . . . . . The incision which I had made in the drum-head was followed for a few days by a scanty sero-purulent discharge. On May 23d he came to me again, having had great pain in the ear the previous day and night. I found the inner half of the auditory meatus occupied by the tumor, and the walls of the outer half red, swollen, and tender to the touch. I ordered warm instillations of a weak solution of carbonate of soda. During the next few days the inflammatory swelling in the outer part of the ear-canal and its surroundings was more pronounced. On May 29th the pain was relieved. An abscess had formed, and pus escaped upon pressure on the tragus. Both Dr. Sands [to whom the patient had been referred by Dr. Knapp for the removal of the parotidean tumor] and myself thought it advisable to delay the operation until the inflammatory symptoms had subsided. When in a few weeks this had occurred, on examination (June 20th) I found that the aural tumor filled the entire meatus, whereas there was no noticeable change in the parotidean tumor. My departure for Europe being at hand (June 23rd), I advised him to let another aural surgeon in my stead take charge of the case, and proposed Dr. A. H. Buck, whom he also consulted at once."

The following note furnished by Dr. Sands to Dr. Knapp gives all the facts of importance relating to the parotid tumor:

" June 26, 1877.—I excised the parotid tumor at the New York Hospital. A vertical incision, extending from the level of the meatus down to the lower end of the growth, measuring from three and a half to four inches in length, was made over the middle of the most prominent part of the tumor. It included only the superficial tissue. The remaining tissues were cut on a grooved director, and carefully dissected out with the fingers. The large mass was first removed, and beneath it was found a sort of pedicle, which was also removed by careful and delicate dissection. The growth proved to be an enchondroma, covered by parotid glandular tissue externally, and firmly adherent to the digastric and other deep-seated muscles. The operation was difficult and tedious, but no large vessel or nerves were divided. After the operation no paralysis of the facial nerve could be detected, although the tumor was apparently situated beneath the parotid gland, the tissue of which was freely divided. No con-

nection existed between the parotid and aural tumors; and with Dr. Buck's assistance I removed as much as I could of the latter by means of a dressing-forceps, having previously snapped two pieces of wire in attempting to effect removal with the 'snare.'

July 24th.—Patient remained in the hospital until a fortnight since, when he went to Ithaca. To-day he returned nearly well."

At this point my own records take up the history of the case, and from them I have compiled the following brief account:

The external tumor, removed by Dr. Sands, proved to be a mixed growth (fibrous chiefly, but in parts cartilaginous, and in still others cellular). The parotid gland was found spread out over the mass in the form of a capsule, but was not involved in its growth. Very careful search was made, but at no point could any offshoot be discovered which might be looked upon as the connecting link between the outer tumor and that within the ear. One portion of the growth seemed to terminate at the tip of the stylo-mastoid process. This suggested the idea that the extension of the growth to the middle ear had perhaps taken place by way of the stylo-mastoid foramen. This could hardly have been the case, however, as there was complete absence of facial paralysis.

July 25th, 1877.—The external wound in the neck has almost entirely healed, and the patient is now exceedingly anxious to have an effort made to remove the aural growth. The pain in the region of the ear continues, and the tumor has increased quite perceptibly in size. By means of a curved blunt-pointed knife, made expressly for this case, I was able to cut off quite a large portion of the growth. The bleeding was active, but not profuse. The patient experienced pain during the cutting operation. As soon as the bleeding had ceased, I attempted to further diminish the size of the mass by gnawing away small portions with a miniature "rongeur." After one or two seizures I was obliged to desist, as the blood poured from the ear in a continuous stream, and the bleeding showed no tendency to stop of itself. The hemorrhage was readily arrested by stuffing the ear with cotton, and applying pressure by means of a bandage passed over the head and under the jaw.

The slippery character of the masses removed (like boiled sago) was a very noticeable feature; and when broken down, the fragments did not show the slightest trace of possessing any fibrous tissue in their composition.

The *microscopic condition* of one of these masses, as ascertained from thin sections made by Dr. W. H. Porter, of New York, stained with carmine, and mounted in Damar varnish, was as follows. With low powers it appears that the tumor is composed in part of round, oblong, and branching alveoli filled with medium-sized cells which have imbibed the staining material quite uniformly and abundantly. Only here and there among these cells can the outlines of a still more deeply stained nucleus be distinguished. The intervalveolar tissue occupies fully one-half of the entire specimen. It has apparently not imbibed any of the staining material, though the round and out-shaped nucleus-like bodies, scattered quite uniformly throughout its substance, are as deeply stained as the epithelioid elements in the alveoli. At many spots the stained nuclei seem to be surrounded by a perfectly colorless hyaline sub-

stance, sharply limited against the contiguous interalveolar tissue: in other words, cartilage cells seem to enter largely into the composition of the matrix of the tumor. All the blood-vessels encountered are of comparatively large size, and filled with blood-corpuscles. At no point can I find distinctly fibrillated connective tissue.

Later, on the day of the operation, a second and very unsatisfactory effort was made to diminish the size of the growth. The copiousness of the bleeding, however, again obliged me to desist.

July 26th.—I introduced four red-hot needles in succession into the mass, with a view of diminishing the bleeding. As soon as the rongeur was used, however, the bleeding became as active as on previous occasions. Before I had reached the middle ear in my mining operations, I thought it advisable to abstain from further interference.

Soon afterward a large abscess developed on the side of the neck, just below the mastoid process, and the patient was again transferred to Dr. Sands' care.

Early in August the patient returned to his home in the central part of this State. Already at that time the growth in the middle ear and meatus had begun to extend into the neighboring parts. On the 24th of October, however, when he came to New York for a few days, I was surprised to see how formidable the growth had become in that short interval of ten weeks. The auricle had been dislocated outward a distance of at least an inch beyond its normal position. This dislocation seemed to be due to the development of a broad, hemispherical mass of tissue beneath (*i. e.*, on the inner side of) the outer ear and on all sides of it. The external meatus was still filled with the growth, and there were two fistulous openings,—one in front of, the other behind, the auricle,—from which pus and blood could readily be forced by pressure made in the neighborhood. The mass could be grasped and moved a little as a whole, but in the main its attachments were very firm. Dr. Sands, Dr. Knapp, and I, agreed that an operation for the removal of this growth was out of the question. The patient returned home.

On the 29th of May, 1878, Dr. S. H. Peck, his medical adviser, wrote to me as follows. "The tumor has attained an enormous growth, is larger than a child's head, and of nearly the same shape; it measures thirteen inches in circumference at the base, and is partly covered by integument. His general health is very much impaired and he is greatly emaciated. He has slight attacks of hemorrhage. I use carbolic acid as a disinfectant. He takes morphine; does not suffer much pain."

After the patient's death from exhaustion, on the 15th of September, 1878, Dr. Peck sent to Dr. Knapp the following memorandum with regard to the condition of the tumor at that time:

"At the time of death the tumor measured in circumference at the base twenty-two inches, in the antero-posterior diameter eight inches, in the vertical seven inches. Its elevation over the surface of the skull was five inches. It extended anteriorly to within half an inch from the orbit, posteriorly nearly to the occipital protuberance, superiorly to the parietal eminence, inferiorly to the angle of the lower jaw. The ear, normal in size and appearance, rested upon the external surface of the tumor, being

carried outward by the tumor. In general appearance the tumor presented a lobulated form, viz.: a superior, middle and inferior lobe, the superior being above the ear, the middle behind, and the inferior below the ear. Mastication was slightly interfered with, simply by the weight of the tumor. No protrusion of the growth into the bucco-pharyngeal cavity was noticeable. No mental disturbance."

The instance recorded above is the only one known to me in which it was demonstrated—I might almost say, positively—that the growth originated in the tympanic cavity. Since the publication of this case other instances of malignant growths involving (and probably, but not certainly, originating in) the tympanic cavity have been reported. They are as follows:

1. A case of round-cell sarcoma, by Dr. Arthur Hartmann, in Vol. VIII. of the Archives of Otology.
2. A case of round-cell sarcoma, by Dr. J. Orne Green, in Vol. XIV. of the Archives of Otology.
3. A case of destructive adenoma, by Dr. S. Sexton, in the New York Medical Journal for 1884.
4. A case of carcinoma, by Dr. Gorham Bacon, in Vol. XVII. of the Archives of Otology, and in Vol. VII. of the Reference Handbook of the Medical Sciences.

*Subjective and Objective Systolic Murmurs.*—Subjective systolic murmurs are by no means rare, but those which can be heard by a second person, as well as by the patient, are, I believe, very rare. I know that I have repeatedly, in cases of subjective pulsating noises, applied the auscultation-tube to the affected ear, but only once have I been rewarded by hearing what the patient had previously described. In the case to which I refer, the patient, an intelligent woman, about forty years of age, consulted me at the Infirmary for a very distressing puffing noise in the right ear. She said that she had discovered that, by making pressure behind the right ear, she could stop the noise. Her hearing had not been affected, nor had she experienced any pain in the right ear. On examination, I found the drum-membrane normal both in texture and in position. No visible pulsation could be detected, nor was there any congestion of the parts. By means of the auscultation-tube, however, a distinct systolic bruit was heard, both by Dr. Wm. McFarland, who was at that time my assistant, and by myself. The pressure of the conical end of the auscultation-tube against the walls of the orifice of the auditory canal rendered the bruit inaudible. The heart-sounds were normal, and the carotids of the two sides seemed to beat with equal force. Unfortunately, I neglected to ascertain whether firm pressure upon the carotid of the right side caused the noise to



cease, or not. From the fact, however, that the woman herself was able to stop the noise by pressing upon some spot situated behind the ear, and from the fact that the conical hard-rubber end-piece of the auscultation-tube accomplished the same result, there can be very little doubt but that the bruit originated either in some twig of the stylo-mastoid artery, which supplies the drum-membrane and posterior portion of the tympanum, or in that branch of the posterior auricular artery which supplies the external auditory canal. It does not seem to me to be necessary to assume that the noise in question owed its origin to an aneurismal dilatation; it might equally well have been caused by some pathological process that took place outside of the artery, as, for example, by the contraction of cicatricial tissue in its neighborhood, causing diminution in its calibre.<sup>1</sup> Cicatricial bands may occupy any position in the tympanic cavity, and consequently may very readily, under favorable circumstances, exert pressure, either directly or indirectly, upon an arteriole.

*Otalgia.*—In the great majority of instances pain in the ear implies inflammatory action either in the middle ear or in the external auditory canal. In the absence, however, of any evidence of inflammation in these parts, we are compelled to seek for the cause in some adjacent or more remote organ. It is to this class of cases that the term "reflex or sympathetic otalgia" is usually applied. According to my experience, such cases are by no means so common as some authorities would have us believe. When a patient complains of pain in the ear, and, on examination, I fail to find any adequate cause for its existence in the condition of either the external or the middle ear, I at once suspect his teeth of being at the root of the trouble; and in the majority of these cases of otalgia I find sufficient dental disease to justify the belief that this condition is the fundamental one, and the otalgia simply a reflex phenomenon. If the teeth are found to be in a healthy condition, we may think next of a malarial, rheumatic, or syphilitic origin for this neuralgia of the ear. I have seen cases in which I have been disposed to ascribe the otalgia to malarial, rheumatic, or syphilitic influences, but I have never yet encountered a case in which I was justified in entertaining more than a mere suspicion. In one of these cases the pain was clearly due to a chronic arthritis of the temporo-maxillary joint; the motions of the jaw causing a plainly audible creaking sound. In another case the otalgia finally terminated in a facial paralysis on the same side of the face. The suspicion that the affection was syphilitic in its nature was strong, but as the patient did not

<sup>1</sup> Consult, on this subject, a paper by Dr. J. Orne Green, of Boston, in the *Trans. of the American Otol. Society* for 1878. Dr. Spencer, of St. Louis, has also, I believe, written on this subject in a recent number of one of the St. Louis journals.

remain long under observation, I was unable to arrive at a satisfactory diagnosis.<sup>1</sup>

I have had absolutely no experience with affections of the *chorda tympani nerve*, and will therefore omit all mention of them here.

---

<sup>1</sup> Consult, on this subject, a paper by J. Orne Green, on Neuralgia in and about the Ear, Transactions American Otological Society, 1874; another by Voltolini, on Otaglia Intermittens, in the Monats. f. Ohr., May, 1878, and July, 1878; a third by Gruber, on Otaglia, in the M. f. O., September, 1889; and, finally, a fourth by Weber-Liel, on Neuralgia of the Ear, in the M. f. O., May, 1878.



## CHAPTER XIV.

### SYPHILITIC AND TUBERCULAR DISEASE OF THE DEEPER PARTS OF THE EAR.

#### I. SYPHILIS.

IN cases of syphilitic sore throat it is not an unusual thing to find the middle ear involved, on one or on both sides. As a rule the picture presented to the eye of the observer is simply that of an ordinary subacute catarrhal inflammation, the membrana tympani being red and swollen, without any appreciable bulging. The subjective symptoms also are in nowise different from those of an ordinary non-syphilitic catarrhal attack. In rare cases, however, pathological changes take place in the membrana tympani which are fairly comparable with those observed in the velum palati, and may therefore be described as specifically characteristic of syphilis. I refer to the development of a perforation—or of two perforations, as I have observed in two of my cases—in the membrana tympani, through a process of melting away, or necrosis, of the tissues.

From mere inspection of the parts it is very likely that one would be at a loss to decide whether the disease were of a syphilitic or of a tubercular nature. The greater brightness of the red color, however, would aid in distinguishing the former from the latter, and the collateral evidence—physiognomy, history of the case, and perhaps the presence of other lesions of syphilis in other parts of the body—would enable the physician to render the diagnosis positive.

The prognosis is not very favorable. Antisyphilitic treatment may arrest the further progress of the disease and may effect a healing of the ulcerative process; but the hearing will rarely be restored to a perfect condition, as it often is after an equally severe non-syphilitic or non-tubercular ulcerative disease of the middle ear. Nevertheless, a course of antisyphilitic treatment will often bring back a very useful degree of hearing power. Such was the case, for example, in the following two instances.

CASE I.—The patient, a man twenty-nine years of age and in good general health, consulted me on the 24th of March, 1877, at the request of Dr. Roosa. During January of that year he had suddenly and almost completely lost the hearing-power in both

ears; chancre eighteen months previously. No other evidence of syphilis, with the exception of an ill-defined ulcer on the right side of the tongue, near its tip. Nothing worthy of note in the condition of the middle ear. Antisyphilitic treatment (by Dr. Roosa), consisting of inunctions with the oleate of mercury and the internal administration of iodide of potassium in large doses (reaching six drachms in a single day on one occasion), brought about, in the course of a few weeks, a very marked improvement of the hearing.<sup>1</sup> (Full details with regard to this case will be found on p. 528 of the fourth edition of Dr. Roosa's "Treatise on the Ear.")

CASE II.—Female, æt. 40, a teacher, somewhat anæmic, October 6, 1877. Totally deaf in the right ear since childhood. Two weeks ago she began to notice slight deafness in the left ear, together with occasional pains and a sense of tightness in the ear. Left drum-membrane apparently normal. The ticking of a watch heard at a distance of four feet. Right drum-membrane very much disfigured by inflammation that occurred during childhood. Pharynx healthy. As there are no indications for treatment, she is advised to wait.

On the 23d of October she returned. The hearing-power had been steadily and even quite rapidly diminishing. Tinnitus constant. On the 12th she began to experience a sensation of dizziness, which soon became so marked that she could only walk with the assistance of a friend. No change in the condition of the drum-membrane. Treatment: Iodide of potassium in fifteen-grain doses three times a day.

October 30th.—Slight improvement in the hearing; dizziness the same. Dose of iodide of potassium increased to twenty grains three times a day.

November 28th.—Hearing is now, so far as she herself can perceive, as acute as when I first saw her on the 6th of October. The ticking of the watch is heard at a distance of four feet. The dizziness has also disappeared entirely, although a little tinnitus still remains. All treatment is to be stopped.

From her physician, Dr. Charles Packard, I learn that he has had occasion to treat her for a suspicious periostitis on both tibiæ. The deafness was therefore probably due to a syphilitic affection of the auditory nerve, or of the labyrinth, or of some structure in its immediate neighborhood.

The treatment is that for constitutional syphilis. No local interference is of material avail, although it is very important to insist upon the patient's using, from one to three times daily, according to the activity of the discharge, some form of ear douche or syringe with tepid water.

In the great majority of instances the syphilitic lesions observed in the region of the middle ear are the result of acquired syphilis, but now and then cases are seen in which we are forced to conclude that the disease has been inherited from one or both

<sup>1</sup> It should be stated here that this patient had already been subjected to what might be termed an ordinary course of antisyphilitic treatment. Little or no benefit, however, resulted. It was not until the more vigorous antisyphilitic plan of treatment had been instituted—the plan which Dr. Roosa was the first, I believe, to employ in these cases of sudden and complete deafness—that decided benefit was obtained.

parents. I believe this to have been the fact in the following case, which is remarkable in several respects:—

A child, seven years of age, and of somewhat delicate appearance, was brought to me by his parents on January 11th, 1887, for the relief of pronounced deafness. The history given by them was, in brief, as follows:

About three weeks previously the child had what seemed to be an attack of croup, which lasted four or five days, and was followed by impaired hearing. The deafness rapidly became so marked that it was almost impossible to communicate with him by speech. Previously to the present attack the child, it was said, had never shown any signs of impaired hearing, although on cross examination the parents admitted that they had sometimes observed a certain degree of inattention on his part, yet not sufficient to make them suspect impairment of the hearing power.

Inflations of the middle ears according to Politzer's method were resorted to promptly by the physician in attendance, and were continued, at regular intervals, up to the time when I saw the case—that is, for a period of about two weeks. Noticeable improvement in the hearing, lasting for a few minutes, or for an hour or two, followed these inflations. In the main, however, the hearing power diminished rather than increased, during this period.

At the time when I first saw the child there seemed to be, for all practical purposes, total deafness. From the statements made by the parents, and also from my own observations, I became satisfied that there were brief intervals of time during which the hearing was sufficiently acute for the child to distinguish correctly at least some of the words that were spoken loudly into one or the other ear. A careful inquiry into the previous history revealed nothing that might throw light on the nature of the aural affection. There had been no complaint of pain, no staggering or uncertain gait, no paralysis. On examination, both drum-membranes were found to present a somewhat dull and sunken appearance. The dull appearance was of such a nature as to suggest the presence of mucus in the drum cavities. However, when air was forced into them by aid of the Eustachian catheter, the sound conveyed to my ear through an auscultation tube was that of air entering freely a tympanum of undiminished size and free from the presence of fluid. This satisfied me that the dulness observed was due, not to the presence of mucus, but rather to an œdematous condition of the mucous membrane on the reverse side of the membrana tympani. The hearing seemed to be impaired to an equal degree in both ears. There were ample evidences of nasal and naso-pharyngeal catarrh.

In the matter of a diagnosis I was obliged to confess that both the nature and the precise seat of the disease were unknown to me. The rapidity with which the hearing had disappeared, and the apparent absence of physical changes in the middle ears adequate to explain the deafness, favored the hypothesis of lesions involving the labyrinth; while, on the other hand, the development of the deafness in connection with a croupy attack, the existence of decided catarrhal manifestations in and about the ear, and the temporary improvement brought about by inflations of the drum cavities, favored rather the idea that the affection was, after all, simply a subacute catarrhal inflammation of the middle

ears with an unusual degree of secondary labyrinthine congestion. At that time there were no visible lesions in the external auditory canals; or, if they were present, they were so insignificant as to escape my notice.

Under these circumstances I gave a guarded prognosis, and recommended a plan of treatment based on the supposition that the disease was simply catarrhal in its nature.

On January 26th, I noticed, for the first time, the existence of a circumscribed area of redness (localized periosteitis) on the posterior and upper wall of the right external auditory canal, in close proximity to the membrana tympani. The redness of the skin did not extend perceptibly beyond the periphery of the latter membrane. An examination of the left ear showed that almost precisely the same condition of the parts existed in that ear; the only difference being that the redness was somewhat less pronounced on one side than on the other. In the absence of pain, of fever, and of any other sign of an ordinary inflammation, and from the fact that the family history was not entirely free from a tubercular taint, I drew the inference that the case in hand was one of tubercular osteitis involving the bony floor of the antrum, and extending inward and forward as far as to the fenestra ovalis and probably into the labyrinth itself. With this new light on the case I suggested to the attending physician that in addition to the inflations and tri-weekly applications of silver nitrate to the vault of the pharynx, cod-liver oil and Huxham's tincture of cinchona should be administered internally, and a modified Wilde's incision<sup>1</sup> be made behind the right ear. It was hoped that, by the aid of the decided counter-irritation which would be established by this last measure, the inflammation of the bone might be made to subside.

February 10th.—The incision was made as suggested, but the localized periosteitis still persists, and, so far as the eye can discover, it has not materially diminished in degree. The external wound has healed. There is a slight improvement in the hearing, according to the statement of the parents, but it is not recognizable by the physician.

February 15.—Incision repeated, on the same side, and wound stuffed with coarse oakum, with a view to exciting more decided counter-irritation than before.

February 21.—Very little inflammatory reaction has followed both this and the first incision, and no recognizable benefit has resulted from the procedure.

By the merest accident I learned to-day, from a person who had been acquainted with the child's parents in earlier years, that both of them had had syphilis before the birth of the child. I made careful inquiries in regard to the ailments and general condition of health of the patient prior to the attack of "croup," but failed to obtain any satisfactory information. From the attending physician, however, I learned that the patient had been a pale, delicate babe. He had had no serious illness during the first year. When a little over a year old he began to have attacks of vomiting, and at varying intervals they would recur. They began by his emptying his stomach and then he would retch and throw up whatever he took, for three days. They learned to expect a three days' siege whenever an attack began. There was no system or

<sup>1</sup> Incision of the mastoid integuments, followed by stuffing of the wound with lint or other irritating material.

regularity about their return. There were no head symptoms nor anything simulating a convulsion. The mother had had one miscarriage and had lost two or three children at an early age. An examination of the child's incisor teeth (not yet the permanent ones) shows no evidences of the characteristic defects described by Hutchinson.

Again the treatment was changed. All attempts at counter-irritation were abandoned, no further applications of silver nitrate were made to the vault of the pharynx,—which, in fact, seemed then to be in so nearly a normal condition as not to require any further active interference,—and the child was put under a regular course of potassic iodide, in slowly increasing doses. It was also suggested that mercurial inunctions should be added, later, to the internal administration of the iodide. My impression is that this part of the treatment was not adopted.

On the 27th of March the attending physician reported that the child was improving, both in his general health and in his hearing power. The iodide of potassium had been given, at first, in five-grain doses, three times a day, but it had been gradually increased, and at that date the dose had reached seventeen grains, three times a day. The cod-liver oil and compound tincture of cinchona had also been continued. "There is no change," his physician writes, "in the appearance of the external auditory canal that I can discover. The remedy has not yet shown its effect on the skin or in any other way; but the child hears better. Of this I am positive."

I quote again from a letter dated June 11th: "He has taken the iodide regularly since I wrote you last, and is improving quite steadily in respect to his hearing. He took at one time thirty-eight grains, three times a day, but it caused some coryza and he has taken less since. I have not seen him, until to-day, for nearly six weeks. Meantime he has developed a trouble with the left eye, the nature of which I do not understand [? keratitis parenchymatosa]. The chief symptoms are photophobia and watering of the eye. His parents have during this time taken the responsibility of reducing his iodide to seven and a half grains three times a day. I have directed them to increase it again. The child's general health is good. He is growing but not increasing in weight."

In answer to my request for more detailed information in regard to the condition of the hearing, the doctor wrote, under date of June 18th: "He hears equally well, as nearly as I can ascertain, with both ears. He would not hear an *ordinary* tone to know what was said. He would hear a tone *slightly* elevated, if the words were spoken slowly and distinctly. His parents think he hears ordinary conversation at times." Again, on the 12th of July, he wrote that "one of the child's knees has been in a swollen condition since ten days ago. There has been no pain, however, nor does it hurt him to use it." Finally, at a still later date (Sept. 13th), he wrote that the boy had continued to take the iodide, and that he was then able to hear almost as well as he had ever heard.

It seems to me that there can be very little doubt in regard to the syphilitic nature of the lesions which damaged this child's hearing so seriously. The miscarriage experienced by the mother, the loss of two or three of her children in infancy, the selection of



the bony parts of the ear by the disease for its first centre of activity, the subsequent development of inflammation of the eye, and then of some sluggish disease of the knee, and, finally, the markedly beneficial effects of potassic iodide administered internally,—all these facts, I believe, favor strongly the idea that the case was one of tardily developed inherited syphilis.

A number of similar cases have been reported by Knapp, of New York (Vol. IX. of the Archives of Otology, where the earlier literature of the subject may be found), by Kipp, of Newark, N. J. (Vol. II. of the Transactions of the American Otological Society), and by others. The chief point of interest in the present case lies in the fact that a circumscribed periosteitis was demonstrable, for a comparatively long period, at symmetrically placed spots in both external auditory canals. These spots corresponded to the bony floors of the mastoid antra. In all other material respects the case differed but little from those hitherto reported.

The discovery of a limited periosteitis (and undoubtedly also osteitis) at the very spot where tubercular disease of the ear is apt to start, suggests the question whether, in cases of deafness due to tardily developed inherited syphilis, this spot, or one very close at hand, be not also a favorite seat of syphilitic lesions.

In view of this possibility I would suggest that particular attention be directed, in cases such as we are considering, to that part of the external auditory canal which lies immediately next to the posterior upper limit of the membrana tympani. I am confident that even a careful observer may, in an unguarded moment, very easily overlook a certain amount of redness of the skin at this point, because it is not unusual to find very nearly the same state of things in cases of simple subacute catarrhal inflammation of the middle ear. The distinction between the two, however, may be stated thus: The redness of syphilitic origin should—according to this hypothesis—be most marked at a spot lying directly upon bone substance, while that due to simple catarrh is most marked along the manubrium mallei and at the periphery of the membrane, and then fades away rapidly from the periphery outward.

In a case like the one narrated above, and also in those cases in which there are no visible or demonstrable lesions in the middle ear sufficient to account for the profound disturbance of the hearing power, it would be interesting to know what is the nature of the lesion which has produced such serious impairment of the function of hearing, and to what parts of the ear it is confined. On these points we can simply speculate. It is more than probable that a localized periosteitis of the inner wall of the cochlea or of the stapedio-vestibular joint is the lesion on which the deafness depends. In the exceptional case which I have just narrated,

I should be disposed to believe that the cochlear cavity had in the main escaped, and that the periosteitis had involved only the stapedio-vestibular joint and its immediate vicinity. The visible spot of redness near the posterior and upper limit of the membrana tympani rather favors the idea that the region bordering upon the niche in which lies the stirrup was the part specially selected by the disease for its localized activity. The remarkable restoration of the hearing further favors the idea that the delicate structures of the cochlea had not as yet been seriously disturbed in their relations. In most of the cases of profound deafness dependent upon syphilis, treatment fails to restore the hearing to any marked degree; and in such cases I think it may be assumed that the delicate structures of the cochlea must have been disturbed in their normal relations, and if once disturbed it seems highly improbable that they can ever again be capable of performing the delicate and precise task assigned to them.

As regards the details of the anti-syphilitic treatment, I have nothing special to say. I find, however, that a recent writer<sup>1</sup> on the subject of hereditary syphilis, lays considerable stress on the necessity of not trusting to the potassic iodide alone, but of employing in conjunction with it mercurial inunctions.

Before dismissing this subject I wish to lay stress upon the importance of keeping one's mind on the alert for syphilis, in all cases of rapid loss of hearing, and especially in those in which no adequate demonstrable lesions can be found. All the circumstances surrounding these cases co-operate to throw the physician off his guard, and to make him dismiss syphilis from his mind when he thinks over the possible causes of the deafness. The case last narrated may be cited as an instance of the serious harm that might follow such an oversight, and yet it is an error that physicians must often make.

## II. TUBERCULOSIS.

Tubercular disease of the middle ear is by no means rare in private practice, and among the poorer classes in our large cities it is of almost frequent occurrence. When once the disease has reached a certain stage in its progress it is no longer possible to distinguish the visible lesions from those presented by chronic non-tubercular inflammation of the middle ear. It is only by weighing these lesions in the light of the history of the case and of the general physical condition of the patient, that we find ourselves forced to conclude that the damage which is revealed to us by aid of the speculum and reflected light has been wrought by tubercular disease. Now and then I have observed cases which

<sup>1</sup> A. Wolff: *Ueber Syphilis hereditaria tarda*. Volkmann's Sammlung Klinischer Vorträge, No. 273.

presented features so different from anything that I have seen in the ordinary course of non-tubercular middle-ear disease (both purulent and non-purulent) that I have felt justified in describing the lesions as distinctively tubercular in their nature. For the sake of convenience, I will divide these cases into two groups, and will designate each by a title which describes the most striking feature of its appropriate group.

*Painless Ulcerative Inflammation of the Membrana Tympani.*—So far as my notes show, I have seen only three instances of what I am now about to describe, and yet I am confident that in almost every case of tubercular disease of the middle ear the early changes are precisely the same as those observed in these three cases. The rarity of the disease, or rather of these particular lesions, is more apparent than real. In the absence of pain and of an appreciable discharge from the ear, the patient feels no special need of consulting a physician; and later, when the need is felt, the lesions have disappeared, and the picture then presented to the eye of the observer possesses no specially characteristic features.

In all three of the cases referred to above, the patients were in fair general health. They were certainly not robust, but nobody would for a moment think of speaking of them as presenting the appearance of delicate health. One of them had been subject to almost constant backache for a few months previously, but the significance of this pain (disease of the spinal vertebræ) was only discovered a short time before she consulted me on account of her ear. So far as I could learn, there was no evidence of present or previous pulmonary disease in any of the cases.

In all three of them tinnitus and a sense of fulness in the ear, together with slight impairment of the hearing, were the first symptoms noticed. In two of the three cases I had repeated opportunities of examining the parts with the mirror and reflected light from the earliest commencement of the disease. In the third case I was not consulted until after the patient discovered that his ear was discharging. Slight redness and infiltration of the upper part of the membrana tympani, chiefly posteriorly, and of the skin covering the bony wall of the canal in the immediate vicinity, were the first changes observed. In the course of several days, in one case, and of a few weeks in the other, the infiltration and congestion spread downward until the entire posterior superior quadrant was involved. Gradually, after the lapse of a few days, this region became convex toward the eye of the observer, as if some semi-fluid material were accumulating on the inner side of the membrana tympani. Finally, without any pain, or with a sense of fulness and discomfort barely amounting to a sense of pain, at the most prominent part of the bulging portion,



a perforation established itself, as if by a melting-away process at this spot. From this time forward the disease pursued a somewhat different course in each of the cases. In one of them the redness and infiltration spread rapidly from the posterior superior quadrant to the rest of the membrane. The same thing probably took place in the case which I did not see until after the discharge had been established. In the third case, however—that of the young girl with spinal disease—the redness and infiltration did not spread to the other portions of the drum-membrane; but, on the other hand, the upper and posterior portion of the wall of the canal gradually became more markedly congested and infiltrated, as if the bone itself—that part which constitutes the floor of the antrum—were the chief seat of the disease.

Finally, I will state briefly the subsequent histories of these cases. In the one to which I have last referred the ear gradually improved so far that the only lesions left were a little redness along the upper wall of the bony canal and a scab-like formation covering the site of the perforation. The hearing in this ear was also slightly impaired. In the other two cases the discharge increased in quantity until it became profuse. Then obstructions to the free escape of pus developed, and the patients experienced a great deal of pain. In one of these two cases a sudden hæmorrhage from the lungs announced the development of tubercular processes in that region; in the other, the general health became so wretched that the patient has since been obliged to spend the winter in a milder southern climate.

In conclusion I would say that I am disposed to consider the following as the distinguishing features of a tubercular inflammation of the middle ear, in its incipient stages: 1, *the tendency to localize itself in the vicinity of the upper and posterior portion of the membrana tympani*; but whether the disease originates in the tympanic mucous membrane, in the fibrous structures of the membrana tympani, or in the bone of the immediate vicinity, I am still unable to determine, although I suspect that in some cases the bone substance is the starting-point of the disease; 2, *the marked insignificance of the pain, or even its entire absence*; and 3, *the intolerance of any but the simplest and gentlest local remedial measures*.

*Cheesy Inflammation of the Middle Ear.*—The following brief histories of cases furnish all the information which I am able to give, from personal observation, in regard to this particular type of disease.

CASE I.—The patient, a man thirty-two years of age and in a poor general condition (habitual cough, night-sweats, incurvated nails, emaciated countenance), gave the following account of his ear affection: About a year previously he had experienced slight

pain in one ear, which was followed shortly afterward by a discharge. In the course of six months he went through the same experience with the other ear. In both ears the discharge lasted only for a short time, but the deafness, which was well-marked, had continued unchanged ever since. On examination, October 4, 1876, I found the right drum-membrane of a peculiar pale, flesh-tint color, with two or three dilated blood-vessels crossing its outer surface. The impression conveyed to the eye was as if the drum-membrane had been stretched so tightly over some whitish body that its superficial blood-vessels (veins) had been compelled to perform not only their own legitimate task, but also that of the more deeply situated vessels, which at that time must have been obliterated.

I saw this case only once. I made a note of the conditions observed, but was not able at that time to offer any satisfactory explanation of their origin or significance. I also omitted to test the membrane with the probe; though the appearances were such that I could scarcely have been mistaken with regard to the presence of some semi-solid material in the tympanum, which pressed sufficiently against the drum-membrane to interfere with the circulation on its mucous surface. In the light of the following case, however, I believe that the two cases were essentially identical.

CASE II.—The patient, a clerk, about thirty years of age and in rather poor general health, and with all the external appearances of a person affected with phthisis, consulted me on the 30th of January, 1878, for marked deafness affecting both ears. He gave the following account of his trouble: During the previous autumn, as a result of sea-bathing, both ears had begun to discharge. He was very positive that the affection had developed without pain, and that previous to that time his hearing had been perfect. In corroboration of this statement he called my attention to the fact that he was the head of one of the departments in a large publishing house, and that it would scarcely have been possible for him to have risen to that position, and to have performed its duties properly, unless his hearing had been fairly good. At the time when I saw him his deafness was so marked that I was obliged to speak in quite a loud tone of voice in order to make myself understood. On examination, I found the right auditory canal perfectly dry. The drum-membrane presented a peculiar whitish, polished appearance. A circular perforation, with sharply cut, somewhat thickened edges, occupied the anterior superior quadrant. The entire posterior half of the membrane was in a perceptibly bulging condition, and over its surface ran two or three dilated and sharply defined blood-vessels. When I tested this bulging portion with the probe I found that the drum-membrane was resting upon some solid substance. It felt more like a semi-solid substance (cheesy material, for example) than like bone. Anteriorly the drum-membrane yielded readily to the pressure of the probe. On the left side, I found a little thin, purulent secretion in the auditory canal. The drum-membrane was in all essential respects like the right one. The only difference that I could discover was this: the perforation was slit-shaped and occupied the anterior inferior quadrant, close to the periphery of the membrane; whereas in the other ear it was circular and occupied the anterior superior quadrant, midway between the periphery and the handle of the hammer.

I expressed to the patient's physician the belief that cheesy

material had accumulated in both middle ears, and said that I would like to make an incision through the bulging posterior half of one drum-membrane and endeavor to wash out the cheesy material; and if the operation proved successful, I should want to repeat it on the other ear. My proposition was explained to the patient, but he declined to submit to any such operative interference.

The experience of recent years has taught me to abstain carefully from all such vigorous interference in cases of a tubercular nature. It is probable that the incision of the membrane and the subsequent manipulations of the parts would have resulted in an aggravation rather than an amelioration of the disease.

## CHAPTER XV.

### DIFFERENT FORMS OF AURAL DISEASE IN WHICH THE LABYRINTH IS BELIEVED TO BE INVOLVED.

THIS chapter comprises a series of aural disturbances, all more or less grave in character, and many of them very obscure in their pathology. It is customary to group them together under the heading, "Diseases of the Labyrinth," but, unfortunately, there are good reasons for believing that this convenient designation cannot rightfully be applied to more than a fair proportion of the entire number. In the cases of total deafness following the disease known as epidemic cerebro-spinal meningitis, there can be very little doubt that the chief lesions are located in the labyrinth.<sup>1</sup> I will give in brief outlines the histories of two such cases.

**CASE I.**—The patient, a boy seven years of age, was brought to the Infirmary on the 26th of June, 1872. His father stated that ten weeks previously his son had been taken ill with severe headache, fever, pain in the back, and bending backward of the head and shoulders. About the fourth day of the attack it was noticed that the boy was decidedly deaf, and twenty-four hours later he appeared to have lost the sense of hearing entirely. There had been no discharge from either ear, and the only complaint which the boy had made with reference to his ears was, that he constantly heard noises in them of the most varied character. This symptom still persisted at the time when I saw him. During convalescence, whenever the patient attempted to walk without assistance, he experienced great difficulty in maintaining

<sup>1</sup> And yet, even in these cases, the lesions found after death are sometimes confined almost entirely to the middle ear. Thus, for example, Moos (Archives of Ophthalmology and Otology, Vol. III., No. 2, p. 175) reports a case of cerebro-spinal meningitis, in which, decided, if not total deafness was observed two days before death. At the autopsy, it was found that the tympanic mucous membrane, on both sides, was decidedly hyperemic and swollen. There were also very decided evidences of a general meningitis. But the auditory nerve, in the porus acusticus internus, was quite free from evidences of inflammation, on both sides. Both labyrinths were also examined and found normal in every respect.

Klebs also (Virchow's Archiv, Vol. 34, p. 356 et seq.) narrates the history of a somewhat similar case of meningitis. The patient, a subordinate officer in the army, was taken ill on the 10th of April, and died on the 7th of May. No deafness was noticed when he was first taken ill. Soon afterward, however, he gradually became totally deaf. At the post-mortem examination the auditory nerves (examined microscopically) were found to be perfectly normal. The terminal apparatus of the cochlea was also found to be normal. The middle ear, however, was found on both sides to be the seat of extensive inflammatory changes. Strong bands of connective tissue, well supplied with blood-vessels, traversed the cavity in all directions, and must of necessity have greatly impeded the movements of the ossicles, to which they were adherent at numerous points.

his equilibrium. Although this difficulty had afterward greatly diminished, it was still sufficiently marked, when the boy came to the Infirmary, to attract my attention. On examination, I found both external and middle ears in a comparatively healthy state. The deafness was absolute.

CASE II.—The patient, a boy four years of age, and in apparently good health, was brought by his mother to the Infirmary on the 24th of September, 1872. She gave the following history:

Five months previously the boy had been taken with symptoms of cerebro-spinal meningitis, viz., vomiting, pain in the head, delirium, high fever, and opisthotonos. In the course of a week the delirium passed off, and then the parents noticed that the child was entirely deaf. Since recovery the child had shown an "ugliness" of disposition to his family which they had never noticed before, and a desire to destroy clothing and other articles which came within his reach. His gait had been staggering and was still, at the time when I saw him, somewhat unsteady. Deafness complete. Right membrana tympani opaque and sunken; left, in nearly the same condition. In other respects the middle ear appeared to be normal.

In both of these cases it is reasonably clear that the original disease partook of the nature of a meningitis, and that the inflammation at a certain stage spread to both labyrinths. If the inflammation had not involved the labyrinths, but had simply damaged the main trunks of the auditory nerves, it is difficult to understand why the trunks of the facials, which are so intimately related to these nerves, should have escaped. Equally great are the difficulties that stand in the way of the assumption that the auditory centres in the medulla oblongata are the parts involved. Weber-Liel has shown,<sup>1</sup> by direct experimentation, that a free communication exists between the endolymphatic and perilymphatic spaces of the labyrinth and the extralabyrinthine intracranial spaces, and it is probably by this route that the inflammation spreads from the meninges to the labyrinth.

Epidemic cerebro-spinal meningitis is not the only epidemic affection which is apt to be followed by labyrinthine disease. Scarlet fever, typhoid fever, and measles, also furnish a large proportion of the cases of this form of aural disease. The disease known as mumps may also, in exceptional cases, terminate in the total loss of hearing in one ear. In 1881 I published the reports of two such cases,<sup>2</sup> and since that time I have seen two or three others. I will give here the histories of the two first cases.

The patient, a rather delicate girl, sixteen years of age, was taken ill with the mumps on or about March 9, 1881. She contracted the disease from her sister, but experienced it in a somewhat more severe form than did the latter. Both sides of the face were much swollen, the motions of the jaw were painful, and there was decided soreness of the throat, with a corresponding

<sup>1</sup> Virchow's Archiv, Bd. 77, 1879.

<sup>2</sup> Transactions of the American Otological Society, 1881.

difficulty in swallowing food. On the third day she experienced a sharp pain in one right ear. It lasted only a few hours, and was associated with an unpleasant singing or ringing noise. It was not, however, until the following day that she discovered that she had lost the power of hearing in the right ear. From that time onward, the unpleasant singing noise had continued unchanged. When I was called to see the patient, on the seventh or eighth day of the attack, I found her face still decidedly swollen on both sides. Her general appearance was that of a person who had passed through a somewhat severe illness. Part of this, however, was probably to be attributed to a recent malarial attack. The hearing power of the left ear was normal, both for the ticking of the watch and for spoken words; that of the right ear had apparently been completely destroyed. When she closed the left ear firmly, she was unable to distinguish words spoken in an ordinary tone of voice at a distance of five or six feet from the affected ear. When the same words were spoken in a rather loud tone, she was able, by paying close attention, to make them out correctly. When I pressed my watch lightly against her right ear, she was unable to hear the sound of the ticking, but when I pressed the watch more firmly, she said that she could distinguish it faintly, *but with the left ear*. I tapped gently upon a silver spoon which the patient held suspended lightly between her teeth, and she referred the sounds thus produced to the left ear. (On a subsequent occasion I employed the tuning-fork in the usual manner, and obtained the same results.) The ticking of a watch held in a similar manner between the teeth, was also referred by the patient to the left ear. Firm closure of the right ear did not alter the results obtained in these last two experiments; the ticking of the watch and the sound of the vibrating spoon were still referred to the left ear.

On examination with the speculum and reflected light I found the membrana tympani of the affected (R.) ear very nearly normal in appearance. There was not the slightest evidence of congestion of the dermoid blood-vessels; the membrane proper was perfectly smooth and transparent, and there were no indications of an exudation in the tympanic cavity, or of a swollen or congested condition of the tympanic mucous membrane. The only abnormal condition that I could discover, was a slight drawing inward of the membrane beyond its natural position. The pharyngeal mucous membrane, however, presented decided evidence of having been recently inflamed. It was still markedly swollen (oedematous), and there was abundant secretion in the nasopharyngeal space. It was only with difficulty that air could be forced through the right Eustachian tube into the middle ear. There was no paralysis of the facial nerve.

I questioned the patient closely a second time with regard to the symptoms which immediately followed the attack of pain in the right ear, but failed to elicit any further facts of importance. She had experienced no dizziness, no nausea, no difficulty in maintaining her balance in walking or standing, — in a word, none of the symptoms which are usually associated with the so-called Ménière's disease.

Although the condition of the Eustachian tube and middle ear seemed no longer to have any connection with the deafness, I directed my efforts toward restoring the naso-pharyngeal and tubal mucous membrane to a healthy condition, by means of applications of nitrate of silver, in solution, to the vault of the pharynx, and of inflations according to Politzer's method.

On the first of April, fourteen days after I first saw the patient, I abandoned this plan of treatment. The naso-pharyngeal mucous membrane had, by that time, apparently returned to a healthy condition, and the air during inflation passed readily into the right middle ear. There could, therefore, no longer be any reasonable doubt that further benefit was not to be expected from treatment directed to the middle ear and neighboring mucous membrane. In its stead I prescribed iodide of potassium in increasing doses, and counter-irritation behind the right ear, by means of tincture of iodine. The patient began with fifteen grains of the iodide daily, and increased the dose slowly up to forty grains. During the third week, while she was taking these comparatively large doses, she began to experience the specific effects of iodine. As there was no evidence that the hearing power of the right ear was being restored, in even the slightest degree, I no longer hesitated in giving an absolutely unfavorable prognosis, and advised the patient to stop all treatment. I examined the affected ear again during the second week of May, just before the patient left for a pleasure trip in Europe, and found that the hearing still remained a perfect blank.

The following is the history of the second case reported by me in 1881:

The patient, a man forty-one years of age and in good health, contracted the mumps on or about the first day of June, 1881. The swelling was noticeably greater on the left than on the right side of the face. The motions of the jaw were decidedly painful. On the third or fourth day of the attack, he discovered that he was unable to hear with his left ear. He also suffered at the same time with a loud roaring sound in the head. In the course of three or four days this noise, which had hitherto been general throughout the head, gradually became localized in the left ear. On or about the fifteenth day the patient experienced nausea and dizziness, and found considerable difficulty in maintaining his balance. These new symptoms grew more marked during the following forty-eight hours, and then began slowly to diminish in intensity. No very marked change for the better took place, however, until after four leeches had been applied behind and in front of the affected ear. This was done on the 20th or 21st of June, by the advice of the physician whom he first consulted. The roaring and deafness remained unaffected by the local blood-letting, but the nausea, dizziness and difficulty in maintaining his equilibrium were at once greatly diminished by this procedure. Leeches were also applied on two subsequent occasions, each time with a certain amount of benefit to his general condition, but without affecting the damaged hearing in the slightest degree.

On the 15th of July I examined the left ear with the speculum and reflected light, but failed to find anything in the condition of the parts that might account for the deafness or other symptoms. So far as could be ascertained by means of the usual tests, the hearing power of the left ear had been completely destroyed. The sound of the vibrating tuning-fork, when placed against the patient's teeth, was heard by him only in the right ear.

Local blood-letting, counter-irritation, etc., were all tried without any apparent benefit, and the case was dismissed as incurable.

Toynbee, in his "Treatise on Diseases of the Ear" (p. 361; Lon-

don, 1860), refers very briefly to the development of deafness in the course of mumps. His words are as follows: "The peculiar poison which causes the disease generally known by the name of mumps, is very often the source of complete deafness, which, however, usually occurs in one ear only. In these cases, the nervous apparatus is evidently affected, as the deafness comes on suddenly, is usually complete, and, as a general rule, no appearance of disease can be detected in the meatus, membrana tympani, or tympanic cavity. When the nerve is not wholly paralyzed, and some, although it may be a very slight degree of hearing remains, the only plan of treatment which can be recommended is the use of gentle counter-irritation over and around the ears, at the same time that the ear is exercised by means of the elastic speaking tube." From this statement, it appears that cases similar to the one which I have just narrated were by no means rare in Toynbee's experience. Vogel, also, in speaking of those cases of mumps which terminate in suppuration, says:<sup>1</sup> "Not at all unfrequently, the labyrinth and middle ear participate, in which case the pus probably passes directly along the vessels and nerves that go from the parotid gland to the ear. The ossicles of the ear thus become destroyed, and, at the best, life-long deafness ensues." A short distance further on, he says: "Apart from this, the facial nerve seems especially adapted to conduct the inflammation into the auditory apparatus." From this it would be fair to infer that the complication under consideration is not altogether rare in Germany. And yet, in the seventh edition of Von Troeltsch's treatise (1881), I am unable to find a single reference to the subject, and even in the latest edition (1888) of the text-book of Politzer the fact is barely mentioned. The recently published second edition of Gruber's work gives quite a full list of the cases published since 1881, and also mentions briefly the salient points of a case that occurred in his own practice, and that was distinguished by the fact that the hearing was destroyed simultaneously in both ears. From all these facts it appears that the loss of the hearing from mumps is an event of comparatively rare occurrence. It is also fair to assume that the parts chiefly affected are the labyrinthine structures.

Scarlet fever, diphtheria, typhoid fever, small-pox and measles may all be followed by total loss of the hearing power due to labyrinthine lesions involving one or both ears. In rare cases pregnancy has similarly been followed by labyrinthine deafness. In one case which came under my observation the patient's mother attributed the loss of hearing to a series of epileptic seizures. As the child, however, had been subject to otorrhœa, it is quite

<sup>1</sup> Ziemssen's *Cyclopædia of the Practice of Medicine* (American edition), vol. VI, p. 838.



probable that the relations were reversed, viz., that the epileptic attacks were due to the aural affection. In many of these cases the deafness develops at a time when there is no reason to believe that even a trace of meningitis exists, and we must, therefore, in such cases, seek for some other mode of origin. The high degree of inflammation of the middle ear which characterizes a certain proportion of these cases suggests the likelihood of an extension of the inflammation from the tympanum to the labyrinth.<sup>1</sup> Blood-vessels pass freely from the tympanum to the vestibule through the stapedio-vestibular ligament, and, if I am not mistaken, also through the membrana tympani secundaria. There are, therefore, no anatomical reasons why such an extension of the inflammation should not take place. As a matter of fact, however, an acute inflammation of the middle ear, no matter how severe, rarely leads (during the acute stage) to serious and permanent impairment of the hearing, or, in other words, to serious disease of the labyrinth. This is the only objection that I know of to the view that in some of these cases of total loss of hearing the damage may be due to an extension of the inflammation from the middle ear to the labyrinth. I might frame still other hypotheses for the purpose of explaining these obscure cases of rapid loss of hearing, but the actual facts in our possession are so few that I prefer to abstain from any further theorizing on the subject.

In a few cases the loss of the power of hearing takes place in a gradual manner, and without any attendant symptoms that might throw light on the cause of such loss. As an example of this, I might mention the following case: A healthy young girl, thirteen years old, was brought by her mother to the Infirmary on the 3d of November, 1873. Six months previously the mother had noticed that her daughter was a little deaf, and in the course of about two weeks the child completely lost the sense of hearing. No illness of any kind preceded or accompanied this loss, and even the dizziness and staggering gait, which are so often associated with the sudden development of deafness, were absent in this case. An examination showed that the middle and external ears were in every respect normal.

<sup>1</sup> In this connection I might mention a case of intermittent complete deafness, in a boy about four years old. The child, as I learned from the mother, had twice before remained in a condition of total deafness for a period, each time, of several weeks. During the intervals he had heard sufficiently well for those around him to be able to make themselves understood. At the time when I saw the boy, he had been absolutely deaf for a period of six weeks, and the parents were beginning to fear that he had permanently lost the sense of hearing. On examination I found the drum-membranes so highly atrophied that each of them lay like a thin film in contact with the purplish and swollen mucous membrane of the inner wall of the tympanum. The tonsils were enormously swollen, and the naso-pharyngeal space seemed to be almost obliterated by the highly swollen condition of the surrounding walls. As a consequence the boy was obliged to breathe wholly through the mouth. So far as I could ascertain by actual experiment, the boy was totally deaf. (The subsequent history of this case is unknown to me.)

Voltolini<sup>1</sup> maintains that there is such a thing as a primary acute inflammation of the labyrinth, and gives the histories of a few such cases. He admits that this form of disease is often mistaken for "inflammation of the brain," and I suspect that the error—if error it be—is one that can scarcely be avoided. In some instances, however, the history of the progress of the disease shows quite clearly that the meningitis does not precede the disease of the labyrinth. Thus, for example, Schwartz<sup>2</sup> has published the details of a case in which the symptoms during life pointed to an acute primary inflammation of the labyrinth. Subsequently meningitis developed and the patient died. At the autopsy no other cause for the general meningitis was found beyond a purulent inflammation of the labyrinth.

The term "Ménière's disease" is loosely applied to all those cases of sudden loss of hearing (on one or on both sides, complete or incomplete) which are associated with vertigo, tinnitus, nausea, inability to maintain one's balance, etc. In some of these cases, especially in young individuals, it is more than likely that the disease should be considered as a mild attack of epidemic meningitis, with an extension of the inflammation to the labyrinths. In 1872 this disease was fairly epidemic in this city and vicinity, and in parts of Connecticut, and many of the patients were brought to the Infirmary in the hope that their deafness could be relieved. In a few of these cases the cerebral disturbances seemed to have been very trivial, and had it not been for the fact that the disease was epidemic and that I was interested in learning something about it, I think I might very easily have overlooked the primary disease and have considered some of these cases, at least, as instances of a primary affection of the labyrinth. Take as an example the following case:

The patient, a girl, about fourteen years of age, was brought to the Infirmary on the 8th of May, 1872. From her mother I learned that three months previously she had been taken ill one day with dizziness, noises in the ears, slight disturbance in vision, photophobia, and finally vomiting. On the afternoon of the second day the mother noticed that she was very deaf, and by bed-time it had increased to such an extent that they were obliged to communicate with her by writing. So far as I could learn there had been no delirium, no opisthotonos, nor any other decided symptom of meningitis. Although the other symptoms soon disappeared, the deafness and the inability to easily maintain her equilibrium persisted. The latter symptom had not entirely disappeared at the time when I saw the patient, but the deafness was apparently as profound as on the second day of the attack. I found the middle ears practically normal.

In other cases it is extremely difficult to picture to ourselves

<sup>1</sup> Monatschrift für Ohrenheilkunde, October, 1867; June, 1868. See also a case reported by Schwartz, in the Archiv für Ohrenheilkunde, XIII., p. 107.

<sup>2</sup> Archiv für Ohrenheilkunde, Bd. XIII., p. 107.

the precise nature of the pathological processes and the exact locality in which they are taking place. When we take into consideration the apoplectiform character of the attack or attacks,—for there are often several of them,—the nearness of the auditory centre to other important centres (that governing the pneumogastric, for instance), and the fact that, when the inflammation spreads from the tympanum to the labyrinth, all those concomitant symptoms which are considered as essential features of the typical Ménière's disease,—viz., the dizziness, the staggering gait (or movements in a circle), and the nausea or vomiting,—are lacking; when we consider all these things, I say, it is hard to resist the belief that the medulla oblongata is more likely to be the seat of the disease than the labyrinth.<sup>1</sup>

<sup>1</sup> In this connection I might mention the results of experiments made by Arthur Boettcher, in 1872, on pigeons, and published in the *Archiv für Ohrenheilkunde* for 1874. Those made by Flourens, many years earlier, seemed to determine beyond a doubt that in that part of the labyrinth which is represented by the semicircular canals resides the power of controlling the equilibrium of the body. In 1870 Goltz repeated these experiments, and was led to the conclusion that the semicircular canals "were organs of sense for the maintenance of the equilibrium of the head, and so also, indirectly, of the entire body." Boettcher, by operating in a somewhat different manner from that pursued by his predecessors, was able to divide the posterior vertical semicircular canal of the frog *without* producing in that animal any of the peculiar movements described by Flourens. This induced him to carry out a series of similar experiments upon pigeons, the results of which may be stated as follows:

In those cases in which the operation was carried out without any special precautions, and in which, as a consequence, there was considerable hemorrhage from the vessels in the neighborhood of the semicircular canals, the results obtained were essentially the same as those described by Flourens, Goltz, and others, viz., twisting of the head to one side, rolling movements, travelling in a circle toward the affected side ("mouvements de manège"), unsteady and uncertain gait, pendulum-like motions of the head, etc. In one case the twisting of the head and the rolling movements did not appear until the fifth day after the second operation (division of the canal on the opposite side). At the post-mortem examination in this case the evidences were found of an acute inflammation of the dura mater in the vicinity of the region where the second operation had been performed, and extending thence to the portion which covers the cerebellar hemispheres.

In a second series of cases, although great care was used in performing the operation, the results varied very greatly. Thus, in one case, after division of the inner vertical canal of one side, the bird showed a tendency to fall forward, but this continued for only two days. After division of the horizontal canal of the opposite side, pendulum-like movements of the head began, and the bird showed a tendency to fall toward that side. The pendulum-like movements, however, soon ceased, and the bird slowly recovered the use of its legs. The power of flight was totally lost after the second operation.

In another case, after division of the semicircular canals, the tendency to move in a circle showed itself, but soon passed off. Although a semicircular canal on each side had been divided, no pendulum-like movements occurred. A short time after the operation, and notwithstanding the fact that the continuity of the semicircular canals has been broken on both sides, no disturbance of the equilibrium could be noticed. Furthermore, the tendency to move in a circle scarcely showed itself at all when the bird walked, while during its flight it was very marked. The peculiar manner of holding the head sideways, and the attacks of bringing the head down in such a way that the top would touch the floor, did not appear as the immediate result of the operation, but for the first time as late as four weeks after the operation, that is, after the full disappearance of all the immediate effects of the operation. These peculiar symptoms were therefore due to some disturbances which must have developed at a later date, and were only indirectly connected with the division of the semicircular canals. The rolling movements appeared in connection with the twisting of the head whenever the bird was very greatly disturbed. There was no appreciable connection between the rolling movements and the tendency to move in a circle. The latter symptom was noticeable for a long time before the rolling movements appeared, and when these came, the tendency to move in a circle disappeared altogether.

In still another case, after the division of both outer vertical semicircular canals, the twisting of the head and the rolling movements did not appear until after a

I will give here a few examples of that form of Ménière's disease in which the apoplectiform character of the attack would lead a careful observer to doubt seriously the correctness of the prevailing view that the labyrinth in such cases is the region chiefly or exclusively affected.

CASE I.—The patient, a decidedly stout, full-blooded lady, about forty years of age, consulted me on the 1st of August, 1871. She stated that on the previous Christmas morning, while in the enjoyment of her usual good health, she had been suddenly seized with a severe pain in her head, accompanied by dizziness, nausea, and loud noises in both ears. She was walking about the room at the time of the attack, and was obliged to take hold of some article of furniture, in order to escape from falling. The objects in the room seemed to her to be turned upside down; she also saw double. She lay down upon the bed, and soon afterward vomited. When her friends came into the room and spoke to her, she discovered that she had completely lost the sense of hearing. The nausea and vomiting ceased in the course of a few hours, and, with the disappearance of these symptoms, she experienced decided relief from the pain in the head. Her hearing soon began to return, and at the end of about six days she was able to hear fairly well. The double vision lasted somewhat longer, and did not finally disappear until after the lapse of several weeks. The subjective noises, however, and a moderate degree of deafness, had

lapse of about three weeks. There was total loss of the power of flight, and the left leg appeared to be permanently affected. At the autopsy, an extravasation of blood was found in the pia mater, on the left side, just over the origin of the acoustic nerve. The supposition is therefore justifiable that the symptoms which developed later, — the twisting of the head and the rolling movements, — were due to this extravasation.

Finally, in a fourth case, after the division of the lower arms of both vertical semicircular canals, the bird was still able to hold its head in a perfectly normal position. The ability to walk and the power of flight were very materially diminished; yet they improved very decidedly in the course of a short time. About ten days after the operation, well-marked pendulum-like movements in a vertical direction set in, and the power of flight appeared to be quite destroyed. At last these symptoms, too, almost entirely disappeared. No lesions were found in the brain or its membranes at the autopsy.

In a third series of cases the operation was performed more successfully, as regards the avoidance of injury to neighboring important parts; and in these cases, after the division of one or more semicircular canals on both sides, but very slight and transient motor disturbances followed; the birds in a very short time entirely recovered their powers of locomotion, of maintaining perfectly their equilibrium, and of picking up particles of food.

By these very important experiments Boettcher proves that the semicircular canals may be divided *without* causing any of the symptoms described by Flourens and Goltz as specially due to a lesion of this apparatus. If, as he says, the destruction of the semicircular canals were the cause of these characteristic motor disturbances, the latter should have persisted as a permanent thing; instead of this, however, they soon disappeared entirely, notwithstanding the fact that the apparatus of the semicircular canals had been practically destroyed. Another point to which he calls attention, and which certainly has a suspicious character about it, is this: *the motor disturbances, when only one side is operated upon, always appear in the extremities of the side upon which the operation has been performed.* Thus, the movements in a circle are always executed toward the injured side. A slight paresis of the foot or wing of one side would be sufficient to cause these peculiar movements in the muscle, which have hitherto been considered as something almost specific of a lesion of the semicircular canals.

In conclusion, Boettcher thus states his views regarding this question: "These disturbances of equilibrium manifest themselves either immediately after the operation, — and are then due to an injury of the brain, — or after the lapse of a few days, in which case they are due to pathological processes which have involved the central portions of the nervous system."

As regards an injury to the brain, Boettcher calls attention to the fact that the auditory nerve is not bound down at any point between its origin in the brain, on

continued to annoy her up to the time when I saw her. I tested the hearing and found it to be: R.,  $\frac{1}{4}$ ; L.,  $\frac{3}{4}$ . The sound of the vibrating tuning-fork, no matter at what point it was placed on the cranium, was heard best in the right ear. Aside from the slightly opaque condition of the drum-membranes, the external and middle ears appeared to be normal. Both pupils responded to the light, but the left was fully twice as large as the right. From Dr. Carl Reincke I ascertained that the ophthalmoscopic examination had yielded only negative results. Auscultation revealed the existence of a loud systolic bellows-murmur, heard most distinctly at the base of the heart. (The patient was not seen again.)

CASE II.—The patient, a well-to-do farmer, about sixty years of age, consulted me on the 15th of April, 1873. He gave the following history: About two months previously he was taken suddenly ill with severe pain in the head, dizziness, and nausea. The objects in the room seemed to be revolving in a circle. He lay down, and in about five minutes all the more marked symptoms, with the exception of the headache, disappeared. The attack, however, left him in such a prostrated condition that he was compelled to keep his bed for about three weeks. During this period he occasionally vomited his food, and whenever he attempted to walk about the room he experienced great difficulty in maintaining his equilibrium. About five weeks after this attack he experienced two more attacks of a similar character, the interval between the two not exceeding twenty-four hours. At the time when

the one hand, and the fundus of the meatus auditorius internus, on the other; and that consequently any operative interference with the semicircular canals, which may result in pulling upon or tearing the ampullæ or sacculi,—that is, in pulling upon the vestibular fibres of the auditory nerve,—must necessarily produce a certain amount of injury in that portion of the brain from which these fibres come. The variable results obtained from interference of this kind are due to the circumstance that at one time one set of fibres is pulled upon, while at another, another set. In this connection he quotes Brown-Séquard as saying: "I have ascertained that the phenomena observed in these experiments do not depend on the section of these canals, as this operation may not cause these phenomena, but that they are the results of an irritation of the auditory nerve, from the drawing upon it by the membranous semicircular canals at the time we divide them." (Course of Lectures on the Physiology and Pathology of the Central Nervous System, Philadelphia, 1861, p. 195.)

In answer to the objection of some, that the motor disturbances here under consideration are of too long duration for so slight a lesion, and always take place on the side of the body corresponding to the lesion, — which does not agree with the generally accepted notion that an injury to one side of the brain should be followed by disturbances upon the opposite side of the body, Boettcher again cites the following remarks of Brown-Séquard (loc. cit.): "It is a fact worthy of attention, that a puncture with a needle through the anterior pyramids, which contain very nearly all, if not all, the nerve-fibres employed in voluntary movements, will hardly produce a momentary contraction in some muscles; while certain punctures through the olivary column of the medulla oblongata at once produce a spasm of many muscles, although this column does not contain more than very few (if any at all) voluntary motor fibres! And now, to add to the strangeness of the fact, in this last case the muscles remain contracted sometimes for hours, sometimes for days and weeks."

There is, therefore, in some parts of the nervous centres, a property of acting in a persistent manner to produce muscular spasms during and after a mechanical excitation."

The parts of the base of the encephalon which are capable of producing persistent spasms seem to be quite different from those employed in the transmission of sensitive impressions, or of the orders of the will to muscles, at least in the medulla oblongata and the pons Varolii. They constitute a very large portion of these two organs and perhaps the three-fourths of the first one; they are placed chiefly in the lateral and posterior columns of these organs; many of their fibres do not decussate, and produce, therefore, spasms on the corresponding side of the body."

This is important evidence in favor of Boettcher's view; showing, as it does, that a slight injury of the medulla oblongata, the very part of the brain from which the auditory nerve springs, may result in motor disturbances on the corresponding side of the body, and, furthermore, that these disturbances may last for quite a long time.

he consulted me there was complete deafness in the right ear, the sound of the tuning-fork being referred very promptly by the patient to the right ear. I was unable, however, to ascertain satisfactorily at what precise time during the previous eight weeks this loss of the hearing-power had taken place. The patient complained chiefly of a throbbing pain throughout the left side of the head. The noises in the left ear also distressed him. On examination I found both ears in a comparatively healthy state. Suction with Siegle's tympanoscope diminished the throbbing appreciably. An examination of the urine showed simply a rather low specific gravity (1004).

Dr. Brown-Séguard, to whom I referred the patient, wrote as follows: "Your patient is evidently attacked with what has been miscalled Ménière's disease (an affection which I had described in lectures and books three or four years before Ménière spoke of it). He has no organic affection of the brain so far as it is possible to say so from the fact that there are no brain-symptoms actually. I would, however, recommend the use of the two medicines for which I have given him a prescription, and I will suggest that counter-irritation of some kind be used behind each of the ears. The patient must live well, taking chiefly nourishing food, but avoiding excess as regards quantity of any kind of food. He has no need of stimulants." The prescription referred to is the following:

R	Sodii iodidi, .....	ʒiiss.
	Sodæ bicarb., .....	j.
	Infus. calumbæ fl., .....	ʒij.
	Tinct. rhei, .....	ʒij.

M. S.—A teaspoonful and a half three a times day before meals, with a little water. (B.-S.)

Also:

R	Strychniæ sulphatis, .....	gr. j.
	Acid. sulph. dil., .....	ʒ xv.
	Aquæ destillatæ, .....	ʒ v.

M. S.—Two teaspoonfuls three times a day after meals. (B.-S.)

The plan of treatment suggested above was carried out faithfully up to the 23d of May. As the effects of the strychnine were then beginning to show themselves (muscular pains and stiffness), the patient was advised to discontinue internal treatment. His general condition had certainly improved during the interval, but the aural symptoms had remained unchanged.

CASE III.—The patient, a healthy but rather full-blooded lady, about thirty years of age, consulted me on the 17th of September, 1872. She stated that during the previous spring she had experienced a sudden attack of severe pain in the head, with loud noises in the right ear. Afterward she discovered that she could not walk without staggering, and that the hearing of the right ear was very much impaired. The former symptom had gradually disappeared, but the deafness and the noises still persisted. On examination, I found both drum-membranes—so far as they could be seen—normal in appearance. In each external auditory canal, however, there was a hemispherical exostosis, sufficiently large to conceal the lower two-thirds of the membrana tympani. These symmetrically placed bony tumors were in close proximity to the drum-membranes. The tuning-fork was heard best in the left ear; the ticking of the watch was not heard at all in the

right ear; when the left ear was closed, words spoken in an ordinary tone of voice were not heard correctly in the right ear beyond a distance of about one foot.

In the course of about two months, under the employment of the iodide of potassium in ten-grain doses, repeated three times a day, the patient so far regained her hearing that she could distinguish the ticking of my watch at a distance of half an inch, and words spoken in an ordinary tone of voice at a distance of about five feet. The tinnitus continued unchanged. Two or three times, during this period of eight weeks, the remedy had disagreed with her, and she had been obliged to discontinue it for about one week each time.

As recently as during the summer of 1879, I learned that the patient had not experienced a relapse.

CASE IV.—The patient, a clerk, about forty years of age, and a decided sufferer from stomach indigestion (nausea, heartburn, gaseous eructations, etc.), was taken suddenly ill, about the 15th of August, 1880, with marked dizziness and noises in the left ear. When he attempted to walk, he found that he could do so only with great difficulty, as he was unable to keep his balance. On the second or third day he discovered that his sense of hearing in the left ear was not as acute as before the attack.

On the 30th of August he consulted his regular medical adviser, and was by him sent to me for a report on the condition of his ear. Although his gait had, he thought, steadily improved, it was still at that time noticeably unsteady. He not only used a cane, but in walking out of doors he seemed to avail himself of the assistance of his wife. He was barely able to distinguish the ticking of my watch, when I pressed it firmly against the left mastoid process. With the right ear closed, he distinguished words spoken in an ordinary tone of voice at a distance of several feet from the left ear. The tuning-fork was heard best (by bony conduction) in the right ear. The drum-membrane showed slight evidences of a subacute catarrhal inflammation, and there was also a moderate degree of naso-pharyngeal catarrh.

Under the title of *anomalies of hearing* may be grouped a series of comparatively rare phenomena which are usually considered as being dependent on lesions confined to the cochlear structures. In this category are included the conditions known as *dipacusis monauricularis* and *binauricularis*,<sup>1</sup> and that known under the designation of "limited range of audition." No instances of the latter anomaly have as yet come under my observation; of the former, however, I have seen a few cases. In the first of these, the patient, an intimate personal friend, contracted a severe "cold in the head," and soon afterward a subacute catarrh developed in the right middle ear. When notes of a rather low pitch were sounded, he heard them as well-defined simple musical tones. When, however, the highest tones and even those of a moderately high pitch were sounded, the patient heard, besides the fundamental tone, a second and less distinct one. His

<sup>1</sup> Dr. Knapp, of this city, was, I believe, the first to describe and give a name to this peculiar anomaly (Arch. of Oph. and Otol., vol. ii.).

ear not being sufficiently cultivated, he was unable to state what was the interval between these two tones. Furthermore, while suffering in this way he attended a public concert, but, instead of deriving pleasure from the music, he experienced positive discomfort by reason of the great confusion of sounds which it produced in his ear. He discovered, however, that by keeping the right ear closed the confusion entirely disappeared, and the musical tones which reached his ear appeared to be distinct and harmonious. In the course of a few weeks these unpleasant symptoms entirely disappeared.

In this case, the term *diplacsis monauricularis* (or double hearing in one and the same ear) would be the appropriate expression to use in designating the pathological condition. In a second case, the patient, who was also suffering at the time from a naso-pharyngeal (and, in all probability, tympanic) catarrh, experienced still a different form of annoyance. "When I whistled," I quote very nearly his own words as written down at the time in my note-book—"I heard in one ear the corresponding (or correct) note, but in the other ear I heard a tone which harmonized with the first note; the exact relation of which, however, to the note whistled I am not musical enough to state. If I closed the ear that was out of tune I heard only one note, and not a chord." As the patient was giving me an account of something that had happened before I saw him, I was unable to gather more accurate information with regard to several points which would be apt to occur to anybody on reading the above statement. In classifying this case, we might very properly designate it by the term *diplacsis binauricularis*, the phenomenon of double hearing requiring, in this case, both ears for its production.

In a third case, the patient, a maiden lady about fifty years of age, consulted me on the 25th of June, 1873, for a slowly increasing deafness, which on examination I found to be due to a chronic catarrhal inflammation of both middle ears. When I placed the vibrating tuning-fork (C) upon the central portion of the forehead, she said that she heard it differently in the two ears, that is, lower in the left than in the right. As she knew very little about music, she could not tell what the interval was between the two notes. She was positive, however, that it was less than an octave. She also said that the two notes harmonized. I then held the vibrating fork first in front of one ear and then in front of the other, and she still insisted that the pitch of the tone heard on one side was lower than that heard on the other.

I greatly regret that I allowed these cases (or at least the first and the last ones) to pass out of my hands without first subjecting them to a more thorough examination with regard to the behavior of the ears when tested with tones of different pitch.



Since 1873 I have not had a single opportunity of making good these deficiencies. But even these three imperfectly observed cases offer data that possess a certain degree of value. Thus, in the first place, it will be noticed that in all of them there was disease of the mucous membrane of the middle ear. In the second place, in the first two cases (and, possibly, for aught I know, also in the third) the phenomenon of double hearing disappeared entirely when the catarrh subsided. In the third place, there was nothing sudden in the character of the attack, nor was there any nausea or giddiness. Finally, in the second case I would call attention to the patient's statement that when he closed the ear that was out of tune, the symptom of double hearing ceased. Cases of diplacusis are considered as *par excellence* cases of disease of the cochlea. It is assumed that those particular fibres or sets of fibres in the organ of Corti, which normally should vibrate in sympathy with a different tone from that sounded, become so altered in their tension or in their loading that they too respond to the tone in question, and so send a wrong communication to the brain. If such be the true state of things in these cases of diplacusis, why should the closing of the affected ear—which implies the nearly total exclusion of those sound impulses that would naturally reach the labyrinth by way of the membrana tympani and chain of ossicles—put a stop to the phenomenon of double hearing? The vibrations of the air in the patient's mouth, as he continued to whistle, must, under these circumstances, have been transmitted to the cochlea of the affected (or mis-tuned) ear through the intervening bony structures, without the aid of the mechanism of the middle ear, and, finding there a healthy organ of Corti, these vibrations then produced effects which caused correct impressions to be transmitted to the brain. If this phenomenon can be verified in other similar cases, it will go far toward demonstrating the possibility that the mechanism of the middle ear may be so mis-tuned as to allow certain harmonics of the note sounded to exert a preponderating influence upon its mode of vibration, and thus to excite unduly the corresponding portions of Corti's organ.

I bring forward these points, not because I wish my readers to adopt these views, but simply because I wish to impress upon them the necessity of waiting for further proofs before they unhesitatingly adopt any view. I am myself utterly in the dark with regard to all this category of assumed labyrinthine diseases, and I think we should endeavor to collect, with minds unprejudiced in favor of any particular view, further *facts*. In this way, and in this way only, shall we be able to reach conclusions that will bear the test of time.

In a few cases I have observed the condition usually designated

as *hyperæsthesia acustica*. The individuals so affected were invariably of a nervous temperament, and I have always looked upon the symptom rather as an evidence of an overstrained nervous system than as a manifestation of any disturbance of a peculiarly aural type.

I should perhaps refer in brief terms to the diagnosis, prognosis, and treatment of this class of cases.

If, in the course of scarlet fever, measles, typhoid fever, or cerebro-spinal meningitis, a sudden loss of the hearing-power takes place, we may at once suspect that the lesions are either intracranial or labyrinthine. If, on examination, we fail to find any adequate cause for the deafness in the condition of the external or middle ear, we may feel as positive, with regard to the correctness of our diagnosis, as it is possible to be in the present state of otological knowledge. If the deafness is confined to one ear, the tuning-fork will be found of great value in corroborating our suspicions. It is not an indifferent matter what sort of a tuning-fork we use for this purpose. If the instrument be too small and of too high a pitch, we shall find it utterly unfit for use. No matter how quick our movements may be, we shall barely have time to plant the vibrating fork on the patient's forehead before its vibrations will have become so feeble that to the patient they will be inaudible. In all the instrument-makers' shops it is now an easy matter to purchase forks of low pitch and so constructed that they maintain sufficiently vigorous vibrations for a period of several seconds—that is, long enough for the surgeon to deliberately place the vibrating fork on the patient's head, and for the patient then to quietly observe in which ear he hears the sound best. In the class of cases which we are now considering, the sound of the vibrating fork, placed on the bridge of the nose or in the median line of the forehead, will be heard best or exclusively in the unaffected ear; while if the affection be due to some disturbance in the middle ear (the drum-membrane still being entire), the sound will probably be heard best in the affected ear. In children the test is of doubtful value at best.

The mode of development of the deafness (as, for example, in the cases of Ménière's disease) will also aid us greatly in arriving at a correct diagnosis. In this connection I would again direct attention to the importance of remembering how often these obscure cases originate from constitutional syphilis, either hereditary or acquired. No harm can come from the assumption, in any given case, that the disease is of syphilitic origin; but the failure to recognize such a cause may under certain circumstances deprive the patient of a cure which is perhaps within reach.

The *prognosis*, in all the different cases of this class, is bad;

and yet now and then recoveries are observed. I can recall a single case of total deafness in one ear, following an attack of scarlet fever, in which the hearing, after the lapse of about two weeks, gradually returned to a fair degree of acuteness. The case of syphilitic deafness treated by Dr. Roosa (p. 360) and that of the boy with inherited syphilis furnish striking examples of what may sometimes be accomplished by treatment in this form of labyrinthine disease. In "Ménière's disease" the prognosis is decidedly bad. In those cases in which the hearing is only partially lost, a certain degree of improvement may afterward take place; in the great majority of cases, however, the damage is permanent. The deafness produced by cerebro-spinal meningitis may be considered as the most hopeless of all the known forms of sudden or rapid loss of hearing.

So far as the treatment of Ménière's disease is concerned, I have very little experience of my own to offer. The iodide of potassium afforded some relief in one or two cases; in another, the course of treatment recommended by Dr. Brown-Séguard (see p. 381) ameliorated the patient's condition in other respects, but failed to improve the hearing; finally, in a third, a vigorous anti-syphilitic treatment so far restored the patient's hearing that he was able to hear ordinary conversation fairly well. I have not sufficient faith in the efficacy of electricity or galvanism, in cases of this kind, to justify me in urging a patient to make a trial of them.



APPENDIX.



## APPENDIX.

### ANATOMICAL AND PHYSIOLOGICAL SKETCH OF THE EAR

THE ear in mammals consists of three different cavities—the external auditory canal, the tympanum, and the labyrinth. The first cavity, which is nearly cylindrical in shape, communicates freely, at one end, with the outer world, while at the other it is entirely shut off from the cavity beyond (namely, the tympanum) by a thin inelastic membrane—the *membrana tympani* or drum-membrane. The second cavity, the tympanum, so far as the naked eye can see, is a closed cavity, filled with air, which, through the intervention of the Eustachian tube, is maintained at the same degree of density as the air on the outer side of the *membrana tympani*; or, in other words, the atmospheric pressure upon the outer side of the *membrana tympani* and that upon the inner side exactly counterbalance each other so long as the Eustachian tube is permeable to air. The outer side of the tympanum, as will be seen by the accompanying figure (Fig. 98), is formed chiefly by the *membrana tympani*,

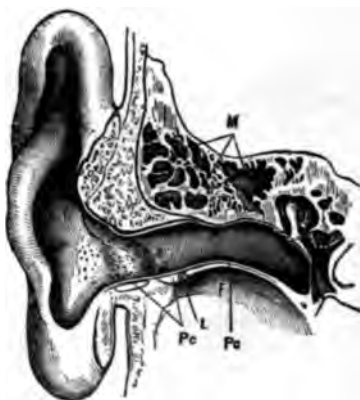

FIG. 98.—Transverse Vertical Section of the Temporal Bone, showing the relations of the external auditory canal to the middle ear, and of the ossicles to each other and to the *membrana tympani* and fenestra ovalis. (After Urbantschitsch.) *M*, mastoid cells; *Pr*, cartilaginous meatus; *Po*, osseous meatus; *L*, membranous connection between the cartilaginous and the osseous portions of the canal; *F*, fossa of the temporo-maxillary articulation.

*membrana tympani*, while the inner is a somewhat dome-shaped surface of bone, covered of course with mucous membrane. In this inner wall of the cavity are two openings—the one oval in shape, the other round—which lead by separate passages into the last cavity or system of cavities of the ear, *viz.*, the labyrinth. In the natural

state these openings are closed, the upper one (the fenestra ovalis) by the foot-plate of the stirrup, the lower (the fenestra rotunda) by a delicate membrane (the membrana tympani secundaria). The apparatus provided for transmitting vibrations of sound from the air in the external auditory canal to the acoustic nerve in the labyrinth, consists of a compound lever formed by the three ossicles—the hammer, the anvil, and the stirrup. If we examine carefully the anatomical and mechanical relations of these little

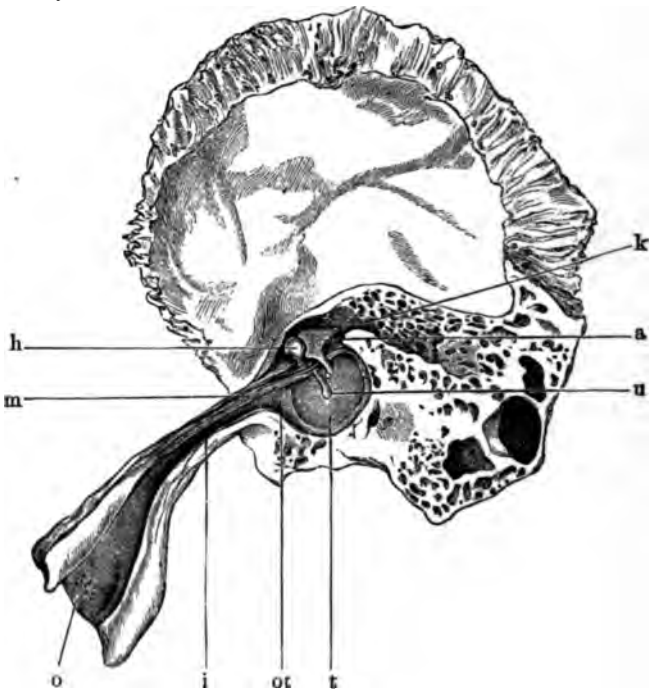


FIG. 99. View of the Outer Wall of the Tympanum. (After Politzer.) *a*, Anvil; *k*, its short process, resting against the posterior wall of the tympanum just beneath the entrance to the mastoid antrum; *h*, the head of the hammer; *u*, the tip end of the handle of this ossicle, corresponding to the umbo of the membrana tympani; *m*, the fleshy part of the musculus tensor tympani; *o*, the pharyngeal orifice; *ot*, the tympanic orifice, and *i*, the isthmus of the Eustachian tube; *t*, the tympanic membrane.

bones to each other, to the membrana tympani, and to the adjacent parts, we shall find ample evidence of the function which they are intended to perform. In the first place, if we disconnect the anvil from the hammer, thus leaving the latter ossicle free to follow the movements of the drum-membrane, and then press upon it from different directions and at different points, we find that its attachments are of such a nature that it can only

rotate inward and outward, as far as the drum-membrane will permit it to rotate, around an axis corresponding to a line drawn from the spina tympanica posterior through the neck of the hammer, and finally through the band of fibres known as the ligamentum anticum of the hammer (Fig. 100 *Lg.a.*). This axis line is represented in the

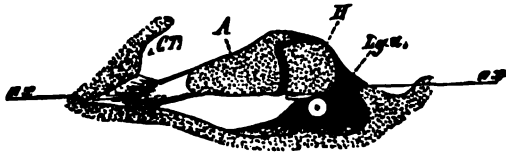


FIG. 100.—View of the Hammer and Anvil as seen from Above (diagrammatic. (After Hensen.) A, Anvil; H, hammer; *Lg.a.*, ligamentum anticum; ax, ax, axis line.

accompanying figure by a straight line running from *ax* to *ax*.

The next point that will be noticed is the peculiar manner in which the anvil is attached to the hammer. As will be seen in Fig. 99, the head of the hammer and the body of the anvil interlock at a level noticeably higher than that of the axis line referred to above. Helmholtz, who was the first to describe the real nature of the malleo-incudal joint, compared it to "the joint used in certain watch-keys, where the handle cannot be turned in one direction without carrying

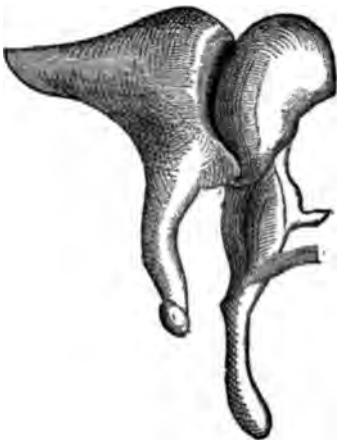


FIG. 101.—Mode of Union between the Head of the Hammer and Body of Anvil. (After Helmholtz.)

the opposite direction it meets with only slight resistance" (*Mechanik der Gehörknöchelchen*, Bonn, 1869.) As a result of this peculiar union between the two ossicles, an excursion of the head of the hammer from within outward—corresponding to an excursion of the membrana tympani in the reverse direction—will, by reason of the fact that the short process of the anvil is quite firmly anchored to the posterior wall of the tympanic cavity, cause the forward part of the body of this ossicle to be lifted both upward and outward. As a further result of this lifting of the body of the anvil upward and outward, the end of the long lever which projects downward from the anvil and which is known by the name of its long process, will be made to rotate upward and inward, and probably a little forward, through a short arc of a circle. The axis line of the rotatory movements of



the anvil, it will thus be seen, is quite different from that of the hammer. With the reverse excursion of the latter ossicle, all direct pressure upon the anvil is withdrawn, and this little bone returns to its former position of rest, partly through the force of gravity and partly through the elasticity of the articular capsule which binds it to the head of the hammer. The third member of the chain of ossicles, or rather of the compound lever which we are endeavoring to describe, is the stirrup. The head of this little bone articulates with the end of the long process of the anvil. The opposing bony prominences are provided with regular articular surfaces, and the joint thus formed is enveloped by a capsular ligament and lubricated, apparently, by synovial fluid. The capsular ligament holds the opposing articular surfaces together so firmly that the head of the stirrup must necessarily follow all the movements of the long process of the anvil. These movements, as we have just seen, would cause the head of the stirrup to be carried, first in an upward, inward and slightly forward direction, and then in the reverse direction back to the starting-point. What effect this excursion of the head of the stirrup will have upon the foot-plate of this ossicle, depends upon the anatomical relations of the latter to the oval window. In the first place it should be borne in mind that in a state of rest the foot-plate lies in a plane which is very nearly parallel with that of the membrana tympani or of the inner wall of the tympanic cavity. The plane of the circle in whose arc the head of the stirrup moves when it makes its excursion, is therefore nearly at right angles to the plane of the foot-plate. Consequently there are six different axes around which the foot-plate of the stirrup may rotate, three of them horizontal, and three vertical, viz. :—(1) it may rotate around an axis running through its upper border; or (2) through one traversing its lower border; or, finally (3), through one situated midway between the two parallel borders. These are the three horizontal axes. The vertical axes are: (4) one running through the anterior border or lip of the foot-plate, (5) or one running through the posterior border, or, finally (6), one running midway between the two.

1. In the case of *an axis of rotation running through the upper border*, we should find the attachments of the foot-plate to the oval window firmer, *i. e.*, less mobile, along the upper than along the lower border, as the excursion of the foot-plate would be far greater at the latter than at the former point.

2. In the case of *an axis of rotation running through the lower border*, we should find the conditions exactly reversed; the lower border would be more firmly attached to the edge of the oval window than the upper one.

3. In the case of *an axis of rotation running midway between*

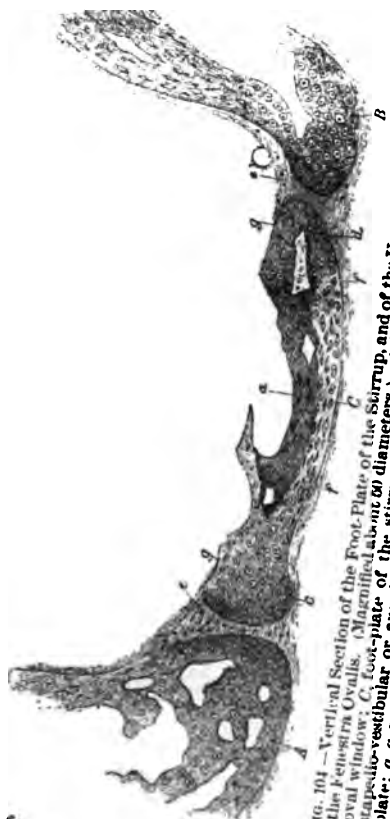*the upper and the lower borders*, we should find the attachments equally yielding or equally firm at both borders; for, like the damper in a stove-pipe, one border of the foot-plate would, in such an arrangement of the axis of rotation, be obliged to travel exactly as far in one direction as did the other in the opposite direction.

The same line of reasoning may be applied to the three possible vertical axes. If the axis of rotation runs through the anterior margin of the foot-plate, the relations of the soft parts along the posterior margin would be found to be such as favor greater freedom of motion on the part of the stirrup at this point, and less freedom near the axial line. On the other hand, if it runs through the posterior margin, the relations just described would be reversed. And, finally, if the axis of rotation is situated midway between the two, no material difference between the attachments of the anterior and posterior borders should be discoverable.

From a mechanical stand-point it would not make any difference whether the axis of rotation of the foot-plate of the stirrup was coincident with the upper, the lower, the anterior or the posterior border: for in either case a direct displacement of the fluid contents of the labyrinth as a whole must follow. On the other hand, if the axial line ran through the centre of the foot-plate, midway between the upper and the lower borders, or midway between the anterior and the posterior margins, the excursions of the stirrup would simply disturb slightly that part of the labyrinthine fluid which lay in its immediate neighborhood, but there would be no displacement of the fluid contents as a whole. The determination of the position of the axial line of rotation of the foot-plate of the stirrup is therefore a matter of importance.

A study of the minute anatomical relations of the stirrup to the oval window throws considerable light upon this question, and the observation that the *membrana tympani secundaria* makes to-and-fro excursions when the *membrana tympani* and chain of ossicles are set in vibration, virtually settles the question in favor of a total displacement of the contents of the labyrinth—that is, in favor of locating the axial line at either one of the four margins of the foot-plate of the stirrup.<sup>1</sup> In the hope of determining this point by direct observation Politzer cut away enough of the *pars petrosa* of the temporal bone to gain an unobstructed view of the vestibular aspect of the foot-plate of the stirrup, without disturbing any of the connections of this or of the other two ossicles and *membrana tympani*. The view thus gained

<sup>1</sup> See, in this connection, the author's paper on the "Mechanism of the Ossicles of the Ear," published in the *Archives of Ophthalmology and Otology*, in 1870.



104 — Vertical Section of the Foot-Plate of the Stirrup, and of the Upper and Lower Margins of the Fenestra Ovalis. (Magnified about 60 diameters.)  
 oval window: *C*, foot-plate of the stirrup, about 60 diameters; *A*, lower margin; *B*, upper margin; *D*, peristemeum (= intuscia) of the lower edge; *E*, *F*, *G*, *H*, various processes belonging to the foot-plate.

don

a treadle rather than to that of a piston, as is commonly done. The mechanical effect upon the fluid of the labyrinth, it is true, is the same in both motions, but when we come to consider the action of the stapedius muscle, we shall see that it is important to bear clearly in mind what is the precise nature of the excursions of the foot-plate.

If further corroborative evidence were needed in support of the doctrine that the ossicles play the part of a compound lever and effect to-and-fro displacements of the labyrinthine fluid, we might furnish instances among the lower animals where a single bone (columella) takes the place of a chain of ossicles, and is so disposed, anatomically, that it can perform no other than a piston-like motion inward and outward. Such is the case, for example, in the sea turtle (see Fig. 105).

In the human being the compound lever composed of the ossicles is provided with two relatively powerful muscles, by the aid of which the different parts of the lever may at will be brought into

a state of greater tension, or greater readiness to respond quickly to vibrations of sound. The effort to pay closer attention implies, I believe, not simply the concentration of the mind upon the different sounds that reach the brain through the ear, but also the unconscious holding of these muscles in readiness to quickly attune the compound lever to all the various kinds and

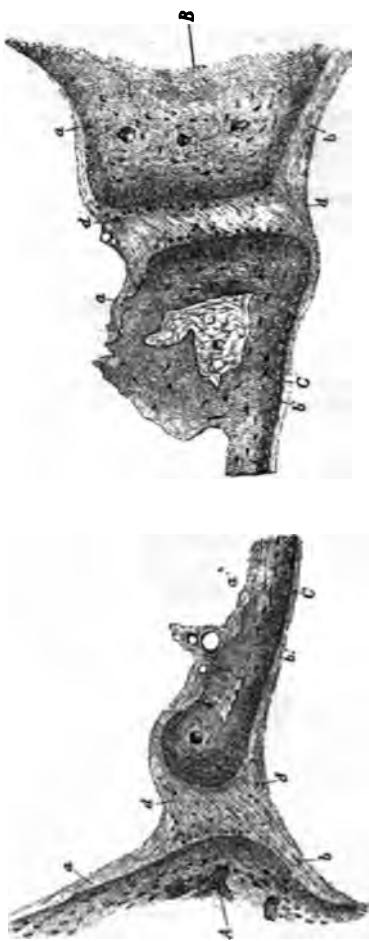


FIG. 104.—Longitudinal Section of the Foot-Plate of the Stirrup, and of the Anterior and Posterior Margins of the Fenestra Ovalis. (Magnified about 50 diameters.) *A*, anterior margin; *B*, posterior margin of the fenestra ovalis; *C, C*, foot-plate of the stirrup; *a*, periotium (= mucosa of the niche for the oval window; *b*, endosteum of the vestibular wall; *b'*, endosteum of the vestibular aspect of the foot-plate; *d*, stapedio-vestibular or annular ligament. (Copied from a specimen belonging to the author.)

rates of vibration which it may be called upon to perform. A deep tone probably calls for little or no muscular co-operation, whereas the higher tones necessitate a great degree of tension of the vibrating mechanism of the middle ear, and this extreme tension can only be effected through the intervention of muscular action. While it is true that will power exercises a certain degree

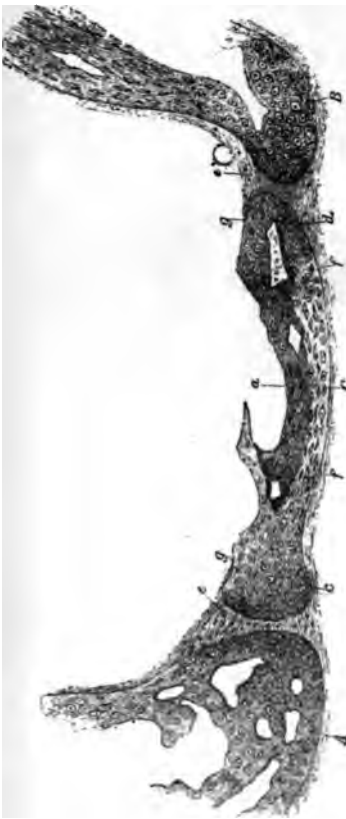

FIG. 104.—Vertical Section of the Foot-Plate of the Stirrup, and of the Upper and Lower Margins of the Fenestra Ovalis. (Magnified about 50 diameters.) A, upper margin of the oval window; B, lower margin of the oval window; C, foot-plate of the stirrup; D, lower edge of the scapulo-vestibular or annular ligament; E, condensation of the vestibular aspect of the foot-plate; F, perioticium (= mucosa) of the tympanic aspect of the foot-plate. (Copied from a specimen belonging to the author.)

of control over the action of these muscles, it is plain that habitually they must act automatically, that is, through the intervention of separate automatic nerve centres. The two muscles referred to are the tensor tympani and the stapedius.

The belly of the tensor tympani muscle rests upon a gutter-like shelf of bone on one side of the membranous part of the Eustachian tube. At the tympanic orifice of the tube the muscular substance merges into a slender cylindrical tendon which passes backward to a point on the inner wall of the tympanum, above the oval window, where it traverses a pulley-like structure which changes the line of traction of the tendon from a direction that is chiefly antero-posterior to one that is chiefly transverse.

Its final insertion is on the inner surface of the hammer, directly opposite the situation of the short process, and about midway between the extreme tip of the handle and the top of the head of this ossicle. When the muscle contracts, therefore, it puts all the ligamentous attachments of the hammer, together with the membrana tympani itself, upon the stretch. It probably also causes a somewhat closer inter-

locking of the opposing articular surfaces of the malleo-incudal joint.

The stapedius muscle is concealed within the pyramidal mass of bone which lies immediately back of the oval window. The belly of the muscle and the facial nerve lie side by side in their respective channels in the bone. The tendon emerges from the apex of the pyramid and passes directly forward to the head of the stirrup. The contraction of the stapedius muscle will therefore produce a three-fold effect: it will tend to drive the posterior margin or lip of the foot-plate farther into the vestibule; it will also tend to lift the anterior margin or lip farther out from the vestibule; and, finally, it will bring the head of the ossicle into closer contact with the end of the long process of the anvil. Thus, through

the combined action of both these muscles every part of the transmitting apparatus of the middle ear may be rendered tense, or, in other words, ready to vibrate in quick sympathy with whatever tones may reach it from the outer world.

In some animals special provision is made for the reinforcement of sounds that may reach the ear. Thus, for example, in the dog there is one large spherical bony chamber (the bulla tympanica) which apparently performs no other function but that of a resonator.<sup>1</sup> The elephant is provided with a perfect labyrinth of such hollow chambers, some of them of large size, and all apparently destined to serve as resonators. Both of these animals possess very acute hearing—more acute, it seems to me, than that of the human being, in whom, as a rule, the resonating chambers—the

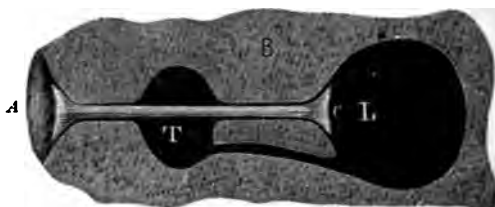


FIG. 105.—Diagrammatic Representation of the Sea Turtle's Ear. A, dense elastic pad of connective tissue, separating the head or outer end of the columella (C) from the horny side surface of the turtle's head; B, solid mass of bone in which the nerve cavity or labyrinth (L) and a second cavity (T), which may be called the tympanum, are situated. That some kind of communication exists between these two cavities is shown by the fact that when pressure is made upon the outer end of the columella—and therefore upon the contents of the labyrinth—the soft parts at one point in the wall of the tympanum may be seen to move outward as if to compensate for the displacement which has taken place in the labyrinth. This yielding point therefore represents (mechanically) the membrana tympani secundaria. (From a specimen in the author's possession.)

<sup>1</sup>The reader is doubtless familiar with the fact that the sound given forth by a vibrating tuning fork can be rendered very much louder by resting its handle upon an empty wooden box, open at one end, or by bringing the ends of the tines in close proximity to and directly opposite the open mouth of a metal Helmholtz's resonator. If the tone of the resonator happen to coincide with that of the fork, the sound given forth by the latter when set in vibration and held near the mouth of the resonator, will be unusually loud. It is thus seen how hollow chambers of a material like wood, some hard metal, or bone, may aid greatly in reinforcing or intensifying sound.

mastoid cells—are small and sometimes lacking altogether. In the elephant, the giraffe, and a few other animals, peculiar osteophytes are found in the middle ear which seem to play some part in the work of reinforcing sound. One of these osteophytes, for example, consists of a very slender rod of bone which projects free into the cavity of the middle ear, and is provided at its extremity with a comparatively heavy knob.<sup>1</sup> Such a heavily loaded elastic rod could, in accordance with well-known acoustic laws, vibrate only in sympathy with tones of a deep pitch. Large as are some of the resonating chambers of the elephant's ear, it is improbable that any of them can serve to reinforce a

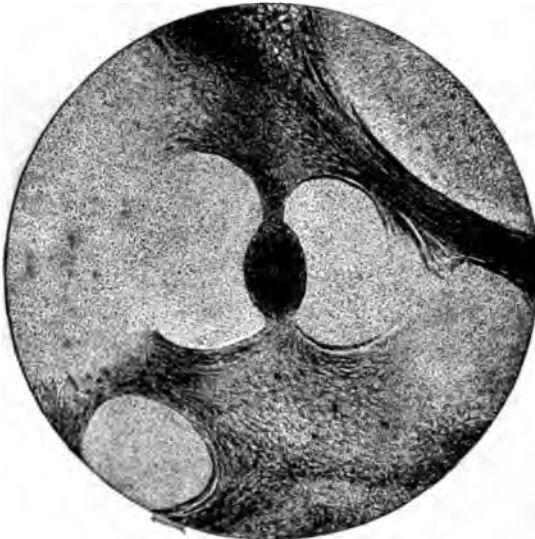


FIG. 106.—Connective Tissue Network from Vicinity of Stirrup, with Peculiar Pear-shaped Body attached. Copied from a microphotograph taken by the late Prof. J. W. S. Arnold, M.D., from a specimen belonging to the author.  $\times 50$  diameters.

decidedly low tone. I think it likely, therefore, that this particular osteophyte performs for low tones precisely the same function as the numerous larger and smaller hollow chambers do for the middle and higher tones of the musical scale. No such contrivance as this is to be found in the human being, but, on the other hand, there have been found,<sup>2</sup> in the immediate neighborhood of the stirrup, in the mastoid antrum, and, in a single instance, on the membrana tympani itself, certain peculiar ovoid bodies which very probably perform this very function of rein-

<sup>1</sup> See a paper by the author entitled "A Contribution to the Anatomy of the Elephant's Ear," in the Transactions of the American Otological Society for 1898.

<sup>2</sup> By Politzer first, and then by Kessel, in 1869.

forcing tones of a deep pitch. One of these bodies which I discovered in a specimen prepared for the purpose of ascertaining the relations of the stirrup to the oval window, is represented in the preceding cut (Fig. 106). Mechanically, the relations of these bodies are those of a loaded string or cord, tensely stretched from the sides of the niche for the oval window to the posterior limb of the stirrup.

Before dismissing the subject of the middle ear, I would like to call attention to the peculiar course taken by the chorda tympani nerve on its way to the tongue. As will be seen in Fig. 107, this nerve emerges from the outer wall of the tympanic cavity, close to the posterior and upper boundary of the membrana tympani, traverses the open space between the middle portion of the hammer and the long process of the anvil, and finally loses itself in the tissues at the upper and anterior boundary of the drum membrane. So far as we possess any knowledge in regard to the function of this nerve, it takes absolutely no part in the mechanism of hearing. Furthermore, it furnishes the only instance in the human body, so far as I am aware, of a nerve crossing an open air-containing space, without any special protecting covering beyond that afforded by a very thin layer of mucous membrane.

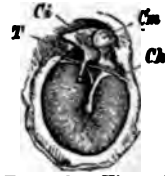


FIG. 107. — View of Inner side of the Membrana Tympani, showing the Course of the Chorda Tympani Nerve between the Hammer and the Long Process of the Anvil. (After Urbantschitsch.) *Cs*, body of the anvil; *Ch*, head of the hammer; *Ch*, chorda tympani nerve; *T*, inner fold of the posterior pocket.

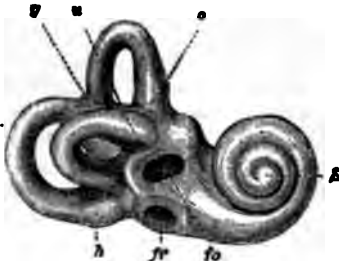


FIG. 106. — Thin Shell of bone immediately surrounding the Vestibule, Cochlea and Semicircular Canals, and showing the Form and Relations of these Cavities to each other. (Right ear.) (After Gruber.) *u*, upper semicircular canal; *a*, posterior semicircular canal; *g*, terminal canal common to both the posterior semicircular canals; *fo*, foramen ovale; *fr*, foramen rotundum; *S*, cochlea.

Thus far we have studied the anatomical and physiological relations of the external auditory canal and tympanic cavity, and of the apparatus contained therein for transmitting sound from the outer world to the labyrinth.

It now remains for us to give a brief sketch of at least the gross anatomical features of the latter system of cavities.

If we take a human temporal bone, either in its natural fresh condition or in the dried state, and endeavor by simple inspection to get some idea of the form, size and relations of the labyrinth, we shall fail completely. There are only three points—the oval window, the round window, and the meatus auditorius internus—where we can get a glimpse of the approaches to this sys-

tem of cavities.



tem of cavities. At all other points the various channels and cavities of the labyrinth are deeply imbedded in the substance of the petrous portion of the temporal bone. It is only by aid of a hammer, chisel, and knife that we can obtain the thin shell of bone which represents, as it were, the mold of the contained cavities. (See Figs. 108 and 109.) In this way we shall find that the labyrinth—we are speaking now only of its osseous boundaries—consists of a central cavity, from four to six millimeters in diameter, from one side of which spring, like arches, the three semicircular canals, while from the other side a canal leads into the snail-shaped body called the cochlea. In their natural state these bony cavities are filled with membranous structures and fluid. Thus, for example, the central cavity, the vestibule,

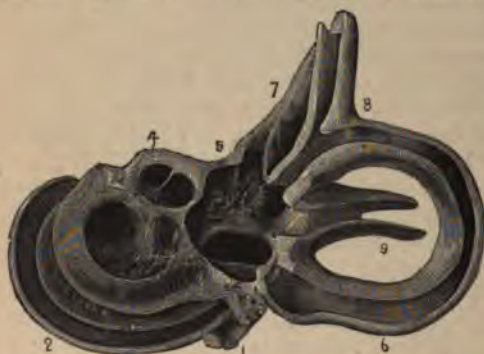

FIG. 109.—The same Shell of Bone chiseled away sufficiently to show the contained cavities and channels. The specimen is taken from the right temporal bone of a newborn infant. (Copied from the Rüdinger Atlas, translated by Clarence J. Blake, M.D., of Boston, Mass.)

contains two distinct membranous sacs which together do not quite fill the entire space of the cavity, but leave room, in the immediate vicinity of the foot-plate of the stirrup, for a certain amount of free fluid. The smaller of the two sacs, the saccule (*S*, in Figs. 110 and 112), communicates with one of the membranous channels of the cochlea, the ductus cochlearis (*scala cochleæ*, in Fig. 115; *D. c.*, in Fig. 112). The larger sac, the utricle (*U*, in Fig. 112), is continuous with the membranous tubes which partially fill the osseous semicircular canals. The two sacs just mentioned do not communicate with each other directly. From each, however, a narrow membranous duct is given off, and these two unite together, at a short distance from the parent sacs, to form the so-called aquæductus vestibuli (*A. v.*, Fig. 112), or ductus endolymphaticus (*de*, Fig. 111), which traverses the intervening bone and communicates with the endolymph of the cranial cavity. Another small membranous channel, the canalis reuniens of Hensen (*c. H.*, Fig. 110), establishes a direct communication between the saccule and the ductus cochleæ (*D. c.*, Fig. 112). The mass of fluid surrounding the saccule and utricle is a direct continuation of that which fills the upper spiral staircase of the

cochlea, the scala vestibuli (*S. v.*, Fig. 112), and also—through a small opening at the very top of the cochlear whorl, called the helicotrema (See Fig. 114)—with that which fills the lower spiral staircase, the scala tympani (*S. t.*, Fig. 112). A spiral diaphragm separates these two masses of fluid. This diaphragm, which is exceedingly complex in structure, contains within it a small duct filled with fluid and called the ductus cochleæ (*D. c.*, Fig. 112).

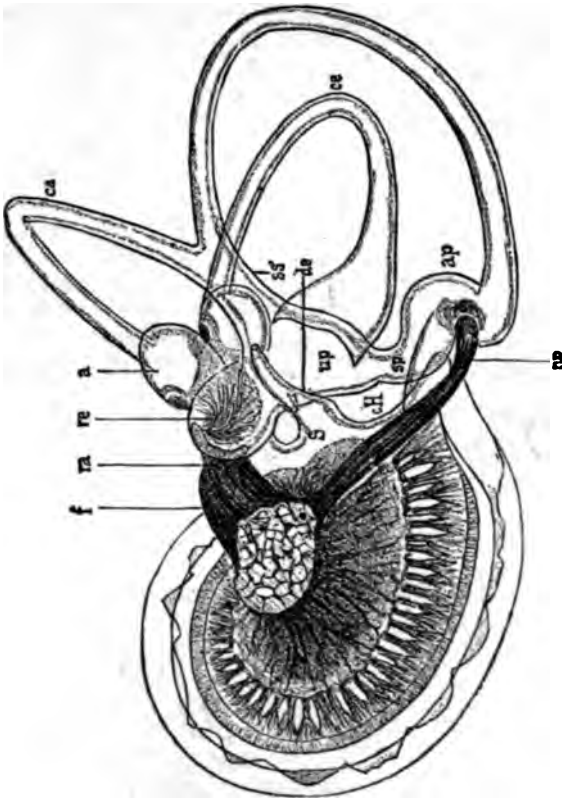


FIG. 110.—The Membranous Labyrinth of a five-months-old Human Embryo. (After Retzius.) X 10 diameters. *sp*, Utriculus proprius; *re*, recessus utriculi; *s*, sacculus; *sa*, sinus utriculi superior; *sp*, sinus utriculi posterior; *ca*, canalis semicircularis anterior; *a*, ampulla anterior; *ap*, ampulla posterior; *ca*, canalis semicircularis anterior; *ca*, canalis semicircularis posterior; *re*, recessus utriculi; *f*, nervus ampullæ posterioris.

These coarser relations of the different cavities, ducts and masses of fluid contained within the labyrinth may all be made out either with the naked eye or by aid of lenses of feeble magnifying power, and they are well shown in Hartmann's diagram (Fig. 112).

As regards the finer details of the labyrinthine structures I shall make no attempt to give here more than a very superficial description. The membranous semicircular canals, to begin

with, present but few peculiarities worthy of note. A cross section of one of them reveals the fact (easily observable in ordinary

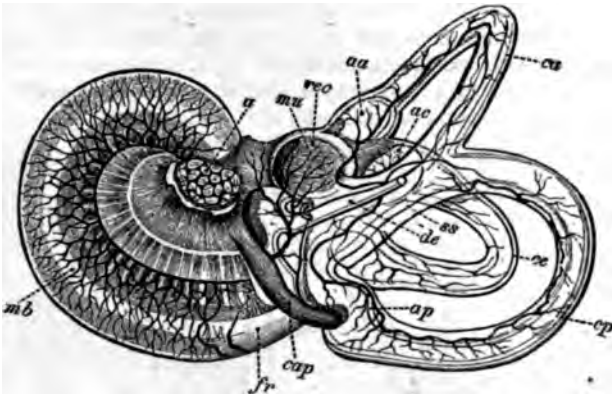


FIG. 111.—Membranous Labyrinth of a five-months-old Human Embryo.  $\times 5$  diameters. (After Retzius.) *ca*, canalis semicircularis anterior; *cp*, canalis semicircularis posterior; *ce*, canalis semicircularis externus; *aa*, ampulla anterior; *ac*, ampulla posterior; *ap*, ampulla posterior; *ss*, terminal duct or tube common to both the anterior and posterior semicircular canals; *de*, ductus endolymphaticus; *rec*, recessus utriculi; *mu*, macula acustica recessus utriculi; *a*, nervus acusticus; *cap*, ramulus ampullae posterioris; *fr*, vicinity of the fenestra rotunda; *mb*, membrana basilaris. The blood-vessels of these parts are represented by branches and networks of black lines.

dissections) that it fills but a small portion, perhaps one-third, of the calibre of the osseous semicircular canal (See Fig. 113).

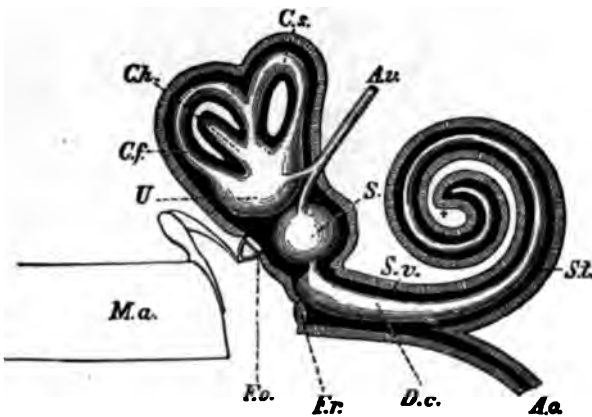


FIG. 112.—Diagram Showing the Relations of the Membranous Structures of the Labyrinth to each other, to the Surrounding Bony Walls, and to the Transmitting Apparatus of the Middle Ear (After Arthur Hartmann.) *Ma*, External auditory canal; *U*, utriculus; *Cf*, frontal semicircular canal; *Ch*, horizontal semicircular canal; *Cs*, sagittal semicircular canal; *Av*, aqua-ductus vestibuli; *S*, sacculus; *Sv*, scala vestibuli; *S2*, scala tympani; *Ac*, aqua-ductus cochleae; *Dc*, ductus cochleae; *Fr*, fenestra rotunda; *Fo*, fenestra ovalis.

The inner surface of this membranous canal is lined with columnar epithelium, and this epithelial lining, when not distended by endolymph, is thrown into folds or rugæ (z, Fig. 118). Like every other part of the labyrinth the semicircular canals are well supplied with blood-vessels; but nerve filaments have not been discovered in any part of these canals except in the ampullæ.

The utricle and saccule present no anatomical features of special interest. The saccule is round in form and communicates with the ductus cochlearis through the medium of the canalis

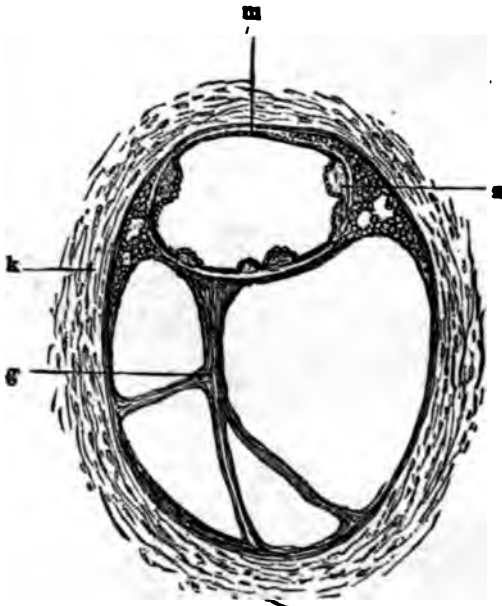


FIG. 118.—Transverse Section of Both the Membranous and Osseous Portions of the Semicircular Canal. (After Politzer.) *k*, Osseous semi-circular canal; *s*, spot where the membranous is attached to the osseous canal; *z*, hill-like elevations of the internal lining of the membranous canal; *g*, trabeculae of the vascular connective tissue.

reuniens of Hensen. Both in the saccule and in the utricle there is one spot where the wall of the sac is thickened, partly by an increase in the amount of the connective tissue, but also in large measure by reason of the presence of an aggregation of peculiar cylindrical epithelial cells which stand in direct communication with nerve fibres coming from the ramus vestibuli of the auditory nerve. These spots are called the maculae acusticae. The free extremities of these epithelial cells are provided with hair-like cilia or rods, and among them are scattered (post-mor-

tem at least, if not during life) the small six-sided crystals of carbonate of lime known as otoliths.<sup>1</sup>

There still remains to be considered the cochlea, the most complicated and evidently the most essential part of the labyrinth. The auditory nerve, it will be remembered, gains entrance into the cochlea by way of the modiolus—the cone-shaped standard of bone around which the cochlear channels are coiled spirally. The base of this standard corresponds with the cribriform bottom, or *cul de sac*, of the porus acusticus internus; its summit, with the cupola or highest point of the scala vestibuli. The modiolus is traversed lengthwise by countless channels through

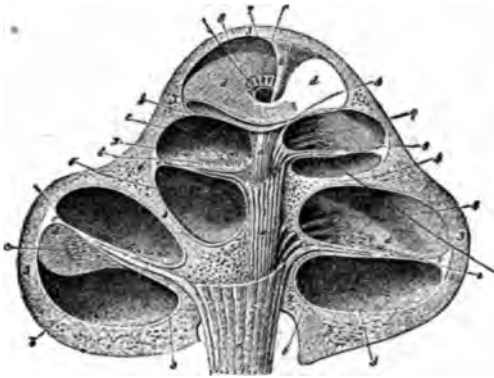


FIG. 114.—Transverse Section of the Human Cochlea in the Plane of the Axis of the Modiolus. (After Breschet.)  $\times$  circa 12 diameters. *a, a, a*, Trunk of the cochlear portion of the auditory nerve; *b, b*, filaments of this nerve branching off from the trunk and passing into the substance of the lamina spiralis ossea; *c, c*, anastomosing nerve filaments; *d, d*, lamina spiralis membranacea; *e, e*, ligamentum spirale of Henle; 1, 1, 1, osseous modiolus; 2, columella; 3, 3, outer bony shell of the cochlea; 4, 4, partition of bone separating the individual cochlear whorls; 5, 5, tympanic portion of the lamina spiralis ossea; 6, 6, vestibular portion of the same; 7, hamulus; 8, helicotrema. A black bristle is represented as passing from the scala tympani below, through the helicotrema, into the scala vestibuli above.

which run the filaments of the auditory nerve. From the base to the vicinity of the summit of this conical core of the cochlea, nerve filaments are constantly being given off laterally to the spiral diaphragm which separates the two scalæ from each other. Just as the filaments are about to leave the modiolus and enter the substance of the lamina spiralis—the technical name of the diaphragm just mentioned,—they pass through an aggregation of ganglion nerve cells (*ganglion spirale*, Fig. 115). Up to this point, and even beyond it, as far as to the line of junction between the lamina spiralis ossea and the lamina spiralis membranacea, the nerve filaments retain their sheathing (white substance of

<sup>1</sup> These anatomical relations have been thoroughly investigated by Urban Pritchard (*Quarterly Journal for Medical Science*, 1876.)

Schwann, etc.), but after they pass this last point they are encountered only as delicate nerve fibrillæ, like those which are found in the rabbit's cornea.

The spiral diaphragm separating the scala tympani below

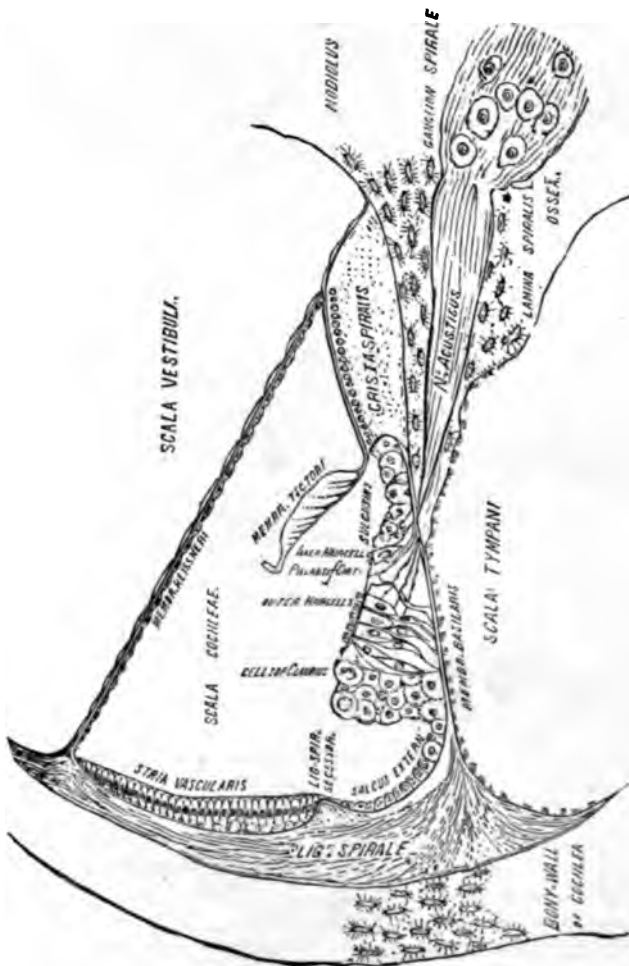


FIG. 11A.—Diagrammatic Transverse Section of the Organ of Corti. X 90 diameters. Copied from Randall and Morse's Photographic Illustrations of the Human Ear.

from the scala vestibuli above, is found, on more careful examination, to contain within itself a third channel—the scala or ductus cochleæ, the fluid contents of which bathe the complicated structures known collectively as Corti's organ. It is here that the

delicate fibrillæ of the auditory nerve may be traced to their ultimate destination, and it is here, beyond all question, that those sensations are elaborated which reach the brain as impressions of sound.

The more important individual histological elements entering into the formation of Corti's Organ are the following:—

1. The *lamina spiralis membranacea*, or the *membrana basilaris*.—This membrane, which is attached along its inner border to the outer edge of the lamina spiralis ossea, and is inserted into that part of the outer wall of the cochlea which is known as the *ligamentum spirale* (Fig. 115), is subdivisible into three zones, *viz.*, the inner, the middle, and the outer zones. The inner zone is extensively perforated, to permit the passage through it of nerve filaments from the auditory nerve; hence its name, *zona perforata*. The middle zone is that part of the *membrana basilaris* which affords immediate support to the organ of Corti; it is called the *zona arcuata*. The outer zone is finely striated in a direction at right angles to the long axis of the membrane; that is, as if the striæ radiated from the central axis of the modiolus.

2. A series of stiff but elastic rod-like bodies which occur in two rows and are so disposed as to form an arched way above the *membrana basilaris*. These are the *outer* and *inner pillars of Corti* (also known as *Corti's fibres* or *rods*.)

In their anatomical relations these pillars present one or two peculiarities which throw some light upon their physiological function: their bases are firmly anchored to the *membrana basilaris*, while their upper ends or heads articulate one with another—each inner pillar with its corresponding opposite outer pillar—in such a manner as to suggest for these parts the very sort of vibratory motion which on theoretical grounds has been attributed to them.

3. A peculiar fenestrated membrane, the *lamina reticularis*, which extends in a horizontal direction some little distance outward from the heads of the pillars of Corti, to which it seems to be in some way attached.

4. Five rows of ciliated cells, four on the outer side of the arch, and one on the inner side, close to the inner pillars of Corti. The four outer rows insert their heads into the openings of the fenestrated lamina reticularis in such a manner that the cilia stand up like bunches of hair at regular intervals along the surface of the membrane. Bundles of primitive nerve-fibrils from the cochlear branch of the auditory nerve have been traced to all five rows of ciliated cells, but to no other structures in the ductus cochlearis. Hence the name of *hearing-cells* which has very appropriately been awarded to these evidently the most important elements in the apparatus we are endeavoring to describe.

5. Simple epithelial cells, destined apparently to serve as a support to the lamina reticularis and to the outer and inner rows of hearing-cells.

6. A peculiar membranous structure, which starts from the upper side of the hooked-shaped process of the *lamina spiralis ossea* and extends outward over the lamina reticularis. This membrana is mucoid (or doughy) in consistency, and, from the

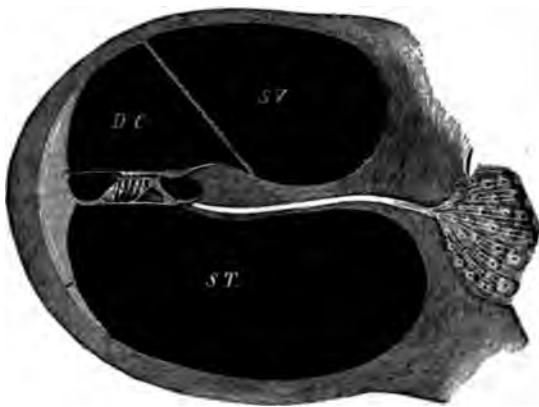

FIG. 116.—Transverse Section of a Cochlear Whorl (Diagrammatic). On the right, embedded in the substance of the bone, is a group of ganglion cells, through which the fibres of the auditory nerve pass before entering the lamina spiralis ossea. This latter is represented in the figure as a broad septum separating the scala vestibuli (S.V.) from the scala tympani (S.T.), and containing a canal for the passage of the auditory nerve filaments. The latter on emerging from the lamina spiralis ossea, pass in part directly to the inner row of hearing cells, and in part beneath the arch of Corti's pillars to the four outer rows of hearing cells. The cilia belonging to the latter may be seen projecting through the lamina reticularis; those of the single row of inner hearing cells project above the head of the inner pillar of Corti. The lamina reticularis is drawn as a horizontal projection (outward) of the upper portion of the head of the outer pillar of Corti. Above the cilia of the hearing cells are covered by the membrana tectoria or Corti's membrane, which springs from the outer hook-shaped edge of the lamina spiralis ossea and terminates, in the present drawing, in a small projecting point called the ligamentum spirale accessorium. At present, however, the weight of testimony seems rather to favor the termination of the outer edge of Corti's membrane at a point in the immediate vicinity of the outermost row of hearing cells. The space bounded below by the organ of Corti (membrana basilaris and superimposed structure) and above by Reissner's membrane (represented in the drawing by a straight band which extends from the bony wall of the cochlea downward and inward to the upper side of the lamina spiralis ossea,) is called the ductus cochlearis (D.C.).

fact that it lies like a gelatinous veil over, and perhaps in contact with, the cilia of the hearing-cells, it is called the *membrana tectoria* or covering membrane (also *Corti's membrane*). As far as to the outer limit of the hearing-cells, this membrane retains its thick, doughy consistency, but beyond this region it is continued in the form of a thin lamina to its outer border. From the appearance of the parts it is believed that in its natural state



the membrana tectoria does not terminate in a free border, but is attached to the underlying cellular structures at some point beyond the limit of the outermost row of hearing cells. By others it is believed that the line of insertion of the membrana tectoria is in the upper part of the ligamentum spirale, along the outer wall of the cochlea.

7. A thin membranous diaphragm, separating the scala cochleæ from the scala vestibuli, and known as *Reissner's Membrane*.

It would be extremely interesting to know what is the behavior of all these delicate structures when subjected to the influence of sound vibrations, but unfortunately we can only speculate with regard to this point. We have described the labyrinth as a closed cavity, having but two channels of approach—the round and the oval windows;—one of which is filled up tightly by the foot-plate of the stirrup. Now, since, according to physical laws, the fluid contents of the labyrinth cannot be supposed to undergo diminution in bulk, under the pressure made by the foot-plate of the stirrup, we must assume—what has now been proved by direct observation—that the elastic membrane of the round window affords the required yielding-point for this displacement.

The first body to receive the impulse of the stirrup is the free mass of fluid which fills those portions of the vestibule and the scala vestibuli, which are not occupied by membranous sacs. Without stopping here to discuss the effects of the stapedia impulse upon the utriculus and semicircular canals, let us proceed at once to the consideration of the effects which this impulse will produce upon the cochlear structures.

In the first place a moment's thought will convince us that, in estimating the effects of the stapedia impulse upon the ductus cochlearis, we may totally disregard the sacculus and the canalis reuniens. The uniform pressure of the fluid upon all sides of these last-named cavities will effectually prevent anything like a current from the ductus cochlearis to the sacculus, or the reverse, through the canalis reuniens. The ductus cochlearis—that is to say, the upper and inner wall of it, or *Reissner's membrane*—is therefore subjected to a uniformly distributed pressure from above downward by the centrifugal (if I may so use the term) force of the fluid of the scala vestibuli. As it yields beneath this force, the incompressible body of fluid which fills the ductus cochlearis must in turn find its yielding-point in the entire membrana basilaris; for this and *Reissner's membrane* are the only two portions of the wall of the duct which are membranous, and therefore capable of yielding. Finally, the displacement caused in the contents of the scala tympani, by the depression of the entire membrana basilaris, is provided for by the presence of an

elastic membrane (*membrana tympani secundaria*) at the larger end of this channel.

This brings us, then, face to face with the fact that the *entire* *membrana basilaris* (including high and low notes alike) is obliged to perform all the excursions which may be communicated to the stirrup or the *membrana tympani* by sonorous vibrations; or,

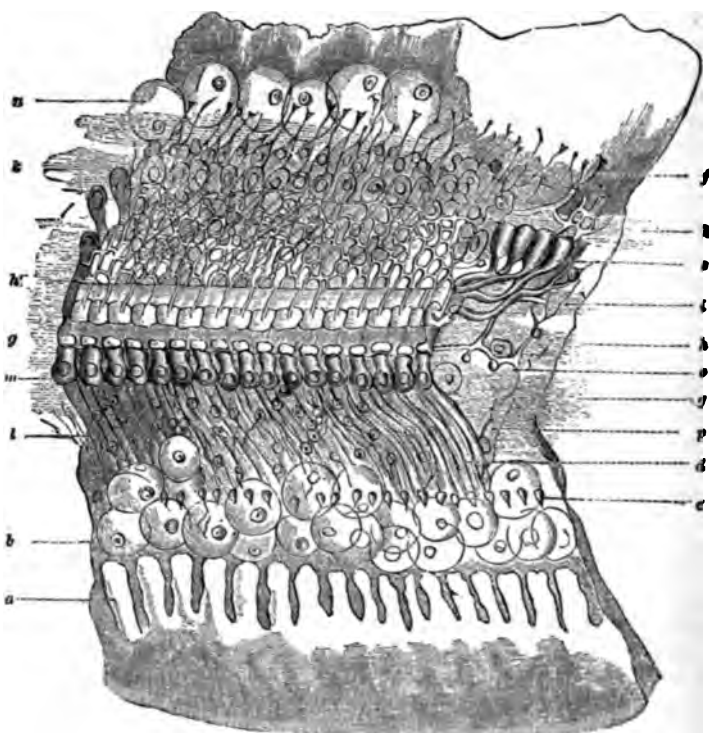


FIG. 117.—View of the Organ of Corti as seen from the Side of the Scala Vestibuli. (Diagrammatic, after Deiters.) Copied from Helmholtz's *Lehre von den Tonempfindungen*. a, Row of tooth-like projections close to inner edge of the *membrana basilaris*; b, epithelial cells, in a swollen condition; c, openings for nerves along the inner border of the *membrana basilaris*; d, row of inner pillars, e, row of outer pillars of Corti's arch; g, h, i, k, k', first four bundles of spiral nerve fibres; l, radiating twigs of the first bundle of nerve fibres; m, upper and inner row of cover cells; n, epithelial cells of the *membrana basilaris*; p, nerve fibres running in a radiating direction over the *membrana basilaris*.

to speak more minutely, with every tone sounded, every "organ of Corti" must perform the number of excursions corresponding to that particular tone. According to the theory propounded by the distinguished German physiologist, Helmholtz,<sup>1</sup> the component

<sup>1</sup> *Lehre von den Tonempfindungen*. Braunschweig, 1870.

fibres of the membrana basilaris are to be considered in very much the same light as separate strings, which by a process of loading—that is, weighing them down with the pillars of Corti, the hearing-cells, etc.,—and also by reason of the differences in their lengths—those near the cupola being twenty times as long as those near the vestibule,—have been tuned so as to vibrate in sympathy with all the appreciable tones, from the highest to the lowest. In fact, for every half-tone of our present musical scale there must be in the cochlea at least thirty-three strings to represent all its possible shades. According to Kölliker there are, in round numbers, 3000 organs of Corti in the human cochlea. By assigning 200 of these to tones outside of the ordinary range, we shall still have 2800 left to provide for the perception of the tones of the seven octaves of our ordinary musical instruments (400 for each octave, or  $33\frac{1}{3}$  for each half tone). (Helmholtz: *Op. cit.* p. 230.) When the stirrup, for instance, vibrates one hundred times in the second, it must excite to action that particular string, or group of strings, which is tuned to vibrate one hundred times per second. The vibration thus caused makes an impression upon the nerve supplying the vibrating part, and this in turn produces in the brain the sensation of sound. The damping of the vibrations, at the instant the irritation which produced them ceases, is attributed partly to the presence of a fluid medium, and partly to the fact that the vibrating structures proper (the strings of the membrana basilaris and the pillars of Corti) are pressed upon by cell-bodies which are not adapted for vibration.

In the presence, then, of these apparently conflicting facts—*viz.*, that certain fibres of Corti are tuned to vibrate in sympathy with certain musical tones, and that, nevertheless, the production of any musical tone whatsoever will necessarily cause *all* of the fibres of Corti to vibrate at the same time,—how shall we explain the possibility of sensations being transmitted to the brain which correspond perfectly with the particular note which may have been sounded? Apparently, we can only explain this by assuming that while the rest of the fibres of the scale vibrate passively in the presence of a particular musical sound, those special fibres which are attuned to the sound in question, will vibrate vigorously,—sufficiently so to free themselves from the influence of any damper that may be present and may consequently prevent the remaining fibres from sending their own individual impressions to the brain. But exactly how these specific impressions are made upon the terminal nerve filaments is something about which we scarcely dare even to speculate.

The equilibrium sense is supposed to possess in the semicircular canals a mechanism suitable to the proper performance of this function. The experiments made by Arthur Böttcher, of Dor-

pat, and reported in detail on page 378, throw so much doubt upon the correctness of this theory that, for the present at least, it is better to consider the question of the physiology of the semicircular canals as wholly undetermined.



## GENERAL INDEX.

- A**BSCESS of cartilaginous portion of the external auditory canal, 29.  
 Absolute alcohol, application of, to the stumps of excised polypi, 268.  
 Acetate of lead solution, in the treatment of diffuse inflammation of the external auditory canal, 78.  
 Acetum cantharidis, in the treatment of eczema of the ear, 30.  
 Acid nitrate of mercury, application of, to stumps of polypi, 268.  
 Acoumeter, Politzer's, 4.  
 Adenoid vegetations in the naso-pharyngeal cavity, 171.  
 Adhesions in the middle ear, 286.  
     operative interference with, 287.  
 Agnew, C. R., 51, 276.  
 Alcohol, as an application to the stumps of polypi, 268.  
 Alcoholics, the excessive use of, promotes irritation of the naso-pharyngeal mucous membrane, 180.  
 Alum powder, in the treatment of discharge from the middle ear, 238.  
     in the treatment of naso-pharyngeal catarrh, 169.  
 Ampullæ, 401.  
 Anaesthetics, necessity of employing, when paracentesis of the drum membrane is performed, 223.  
 Andrews, J. A., 234.  
 Aneurism, circoid, of the auricle, 54.  
     false, of the posterior auricular artery, 329.  
 Angelo's ear douche, 24.  
 Angioma cavernosum of the auricle, 54.  
     of the middle ear, 352.  
 Angioma of the middle ear, 292, 293.  
 Angular forceps, 17.  
     use of, in cases of impacted cerumen, 63.  
 Annulus tympanicus, 13, 14.  
 Anstie, 56.  
 Anthelix, 36.  
 Antisyphilitic treatment, 366.  
 Antitragus, 36.  
 Antrum, mastoid, 299, 300.  
     localized inflammation of, 28.  
     of Highmore, in connection with naso-pharyngeal catarrh, 197.  
 Anvil, relations of, to surrounding parts, 14, 300.  
 Aperients, in the treatment of eczema of the ear, 37.  
 Aqueductus vestibuli, 400.  
 Arnold, J. W. S., 368.  
 Arsenic (Fowler's solution) in the treatment of diffuse inflammation of the auditory canal, 79.  
 Arthritis of the temporo-maxillary joint, 29.  
 Artificial drum membrane forced through a perforation in the membrana tympani, 270.  
     Toynbee's, 290.  
 Aspergillus in external auditory canal, 75.  
 Astringents, application of, to granulating surfaces, 269.  
 Atrophy of the drum membrane, 341.  
 Attic of the tympanum, localized inflammation of, 28.  
 Audition, limited range of, 362.  
 Auditory canal, external, anatomical relations of, 13, 339.  
     cysts of the, 121.  
     desquamative inflammation of the, 82.  
     diffuse inflammation of the, 69.  
     false membranes in the, 64.  
     foreign body in the, 95.  
     impacted cerumen in, 59.  
     inflammations of, 31.  
     new growths of the, 112.  
     osteoma of the, 112.  
     outward motion of epidermis in, 59, 90.  
     relations of lithæmia or gout to inflammations of, 32.  
     syphilitic ulcers and condylomata of the, 100.  
     ulcers, polypoid growths and caries of the, 87.  
     wounds of the, 111.  
 Auricle, anatomy of the, 14, 36.  
     burns of the, 44, 55.  
     chondromalacosis of the, 40.  
     congenital malformations of the, 57.  
     displacement of, for the removal of foreign bodies from the auditory canal, 103.  
     eczema of the, 36.  
     frost-bite of the, 44, 56.  
     hæmatoma of the, 40.  
     herpes zoster of the, 53, 56.  
     new growths of the, 51.  
     perichondritis of the, 40.  
     simple diffuse inflammation of the, 39.  
     syphilis of the, 53.  
     wounds and contusions of the, 55.  
 Auspitz, 56.

- BACON, GORHAM**, 263, 267.  
 Bacon's wet cup, 33, 183, 235.  
**Beekman, J. N.**, 55.  
 Benzoated oxide of zinc ointment, in the treatment of eczema of the ear, 39.  
**Bertollet**, 51.  
**Bezold**, 8.  
 Bicarbonate of soda, as a solvent of hardened cerumen, 65.  
**Blake, Clarence J.**, 51, 58, 65, 99, 104, 259, 275, 400.  
 Blake's middle-ear syringe, 295.  
 Blake's polypus snare, 268, 295, 299.  
 Bleeding from the ear, in fractures of the temporal bone, 222.  
 Blood-letting, local, in the treatment of acute inflammations of the middle ear, 224.  
     in the treatment of eczema of the ear, 38.  
 Blood-sac on outer part of the membrana tympani, 157, 205.  
 Body-temperature, in mastoid affections, 257.  
**Boettcher's** experiments upon the semi-circular canals, 373.  
 Bone chisels, **Schwartz's**, 337.  
 Bone drills, 336.  
 Bone, growth of, in auditory canal, 91.  
     involved, in cases of purulent inflammation of the middle ear, 270.  
     scraping of, for the cure of caries, 272.  
 Boracic acid, in the treatment of discharge from the middle ear, 236.  
 Bran, hot, as a local application in the treatment of acute inflammation of the middle ear, 223.  
**Breschet**, 404.  
**Bridge, Horatio**, 175.  
 Bronchial catarrh dependent apparently upon impacted cerumen, 62.  
**Brown-Séguard**, 280, 281.  
**Brunner**, 44, 49.  
 Bubbles visible through the membrana tympani, 159.  
**Buerkner**, 345.  
**Buhl**, 345.  
 Bulging of the membrana tympani, in cases of acute inflammation of the middle ear, 205.  
 Bulla tympanica of the dog, 297.  
 Bullet, extraction of, from the ear, 205.  
 Burns of the auricle, 44, 55.  
**Burnett, C. H.**, 51, 52, 53, 55, 58, 76, 99, 147, 275, 316.  
**Butlin**, 177.  
**CADE**, oil of, in the treatment of eczema of the ear, 38.  
 Calcareous deposits in the drum membrane, 281, 292.  
     in the external auditory canals of old people, 14.  
 Calcareous material in the auditory canal, 80.  
 Canadian emollient, in the treatment of eczema of the auditory canal, 74.  
 Canalis reuniens of **Hensen**, 400.  
 Canal of **Fallopius**, 14.  
 Cancer of external auditory canal, 116.  
 Carbolic acid solutions not borne well by the skin of the external auditory canal, 80.  
 Carcinoma of the middle ear, 262, 257.  
 Caries of the auditory canal, 87.  
 Caries, superficial, of the middle ear, 271.  
 Carotid artery, ligature of, in the treatment of vascular growths of the auricle, 54.  
     ulceration of, from caries of the temporal bone, 260.  
 Catarrhal inflammation of the middle ear, acute and subacute, 152.  
     chronic, 22, 194.  
**Catheter, Eustachian**, 131.  
     objections to the use of, 153.  
     faucial, 126.  
 Cauterization of eczematous ulcers, 33.  
     of stumps of polypt, 268.  
 Cerebro-spinal meningitis, epidemic, 277.  
     a frequent cause of deafness, 272.  
 Cerumen, diminished secretion of, in connection with sclerosis of the tympanic and pharyngeal mucous membrane, 60.  
     impacted, in external auditory canal, 59.  
     increased secretion of, in connection with naso-pharyngeal catarrh, 60.  
     removal of, by syringing, 22.  
 Ceruminous glands, 14, 59.  
 Cervical glands, involvement of, in cases of mastoid inflammation, 223.  
 Change of air, beneficial effects of, in stubborn cases of ear disease, 184.  
 Cheesy inflammation of the middle ear, 263.  
**Chimani**, 44, 54.  
 Chloroform and ether, vapor of, as a cause of acute inflammation of the middle ear, 204.  
 Chondromalacosis of the auricle, 40.  
     of the external auditory canal, 65.  
 Chorda tympani nerve, 209.  
     affection of, 280.  
 Chromic acid, application of, to stumps of polypt, 268.  
 Chronic catarrhal inflammation of the middle ear, 194.  
     purulent inflammation of the middle ear, 242.  
 Cicatrices of the drum membrane, 263.  
 Cinchona preparations, in furunculosis, 69.  
 Cirsoid aneurism of the auricle, 54.  
 Cleaning the ear, importance of, 244.  
 Cleft lobule, 54.  
 Cochlea, 299.  
 Cod-liver oil, beneficial effects of, in cases of naso-pharyngeal catarrh, 184.  
 Cold in the head, 139.  
 Columella, 285, 297.  
 Coma, in mastoid disease, 227.  
 Concha, 35.  
 Condensing mastoid osteitis, subacute, 205, 207, 225.  
 Condylomata of the auditory canal, 100.  
 Congenital malformations of the auricle, 57.  
 Cord-like bridge of flesh in the auditory canal, 94.  
 Cornu humanum of the auricle, 52.  
**Cornwell**, 204.  
**Corti's** organ, 405.  
 Cotton-holders of malleable steel, 19.  
     usefulness of, as an instrument for making applications to the vault of the pharynx, 165.  
 Counter-irritation, in the treatment of ear diseases, 165.

Curette, 30, 22.  
 use of, in cases of impacted cerumen, 63.  
 Cyst-like tumors of the drum membrane, 230.  
 Cysts of the auditory canal, 121.  
**D**ALBY, SIR WILLIAM, 176.  
 Deafness, dependent upon obstructed nasal passages, 154.  
 intermittent complete, 376.  
 Delafield, Francis, 130.  
 Delirium in mastoid disease, 327.  
 Delstanche, fils, 116.  
 Dennert, 276.  
 Dental engine, use of, in operations upon the external auditory canal, 116.  
 Deprèa, 103.  
 Desquamated epidermis, removal of, by the curette, 24.  
 Desquamative inflammation of the auditory canal, 82.  
 otitis externa, 62.  
 processes in the middle ear, 276.  
 Diachylon ointment, Hebra's, 39.  
 Diagnosis of ear diseases in general, 1.  
 Diet, effects of, upon inflammation of external auditory canal, 32.  
 in the treatment of eczema of the ear, 37.  
 regulation of, in cases of chronic catarrhal inflammation of the middle ear, 301.  
 Diffuse inflammation of the external auditory canal, 69.  
 Dilatation of the osseous external auditory canal ascribed to impacted cerumen, 62.  
 Diplocus binauricularis, 383.  
 monauricularis, 383.  
 Diploetic spaces of the mastoid process, 301.  
 Discharge from the ear, physical peculiarities of, 35.  
 Dizziness and faintness caused by the use of the syringe or the douche, 224.  
 an occasional symptom in chronic purulent inflammation of the middle ear, 375.  
 Dog, ear of, 327.  
 Double-curved Eustachian catheters, 133.  
 Double hearing, 383.  
 Drainage tubes, employment of, after perforation of the mastoid process, 339.  
 Drills driven by dental engine, 116.  
 Drum membrane, artificial substitute for, 230.  
 calcareous deposits in the, 231, 232.  
 cicatrices of the, 235.  
 cyst-like tumors of the, 230.  
 deformed, 344.  
 perforations in the, 237.  
 pockets of the, 33.  
 reproductive powers of the, 234.  
 ruptures of the, 345.  
 thickening of, 232.  
 Ductus cochlearis, 400.  
 endolymphaticus, 400.  
 Dupuytren, 54.  
**E**AR-ACHES, in young children, 135.  
 Ear-louche, Angelo's, 24.  
 Ear specula, 8.  
 mode of introducing into the ear, 13.

Eczema of the auricle, 36.  
 of the external auditory canal, 69.  
 Elephant, ear of, 397.  
 Enchondroma of the parotid, 353.  
 Engleman, George T., 96.  
 Epidermis, outward motion of, in the external auditory canal, 59, 99.  
 Epilepsy, sometimes associated with labyrinthine disease, 375.  
 Epileptiform convulsions, ascribed to impacted cerumen, 63.  
 Epithelioma of the auricle, 51.  
 Equilibrium, sense of, 378.  
 Erectile tumor of the auricle, 54.  
 Erysipelas of the auricle, 37.  
 Ether, vapor of, as a cause of acute inflammation of the middle ear, 304.  
 Eustachian bougies, 130.  
 catarrh, 140.  
 catheters, 131.  
 double-curved, 133.  
 tube, as a drainage channel, 30.  
 complete closure of, 141.  
 injection of remedial fluids into, objectionable, 130.  
 narrowing of, 140.  
 orifice of, obstructed by a band of cicatricial connective tissue, 143.  
 physiology of the, 339.  
 relations of, to the middle ear, 37.  
 relations of, to the nasal passages and pharynx, 133.  
 spasmodic contractions of the muscles of, 145.  
 swelling of tympanic orifice of, 154.  
 unnatural patency of, 143.  
 Excision of the ossicles, 339.  
 Exercise, physical, value of, in the treatment of chronic naso-pharyngeal catarrh, 301.  
 in the treatment of eczema of the ear, 37.  
 Exostoses of the auditory canal, 113.  
 of the head of the hammer, 195.  
 External auditory canal, diffuse inflammation of the, 69.  
 dilatation of orifice of, by Wilde's specula, 66.  
 impacted cerumen in, 59.  
 in infants, 13.  
 in old people, 14.  
**F**ACIAL canal, anatomical relations of the, 304.  
 expression, in cases of adenoid vegetations in the naso-pharyngeal cavity, 171.  
 nerve, anatomical relations of, 31.  
 paralysis of, in the course of mastoid disease, 336.  
 sometimes affected in the course of an inflammation of the middle ear, 31.  
 paralysis, in connection with disease of the ear, 340.  
 Fainting, as a result of syringing the ear, 64, 224.  
 Fallopiian canal, 14.  
 False aneurism of the posterior auricular artery, 339.  
 membranes in the auditory canal, 94.  
 in the middle ear, 293.  
 Faucial catheter, Pomeroy's, 133.



- Fenestra ovalis**, 390.  
     *rotunda*, 390.  
**Fibroid tumors of the auricle**, 51.  
**Fibromatous polypus of the ear**, 262.  
**Fissura Glaseri**, 13.  
     *mastoido-squamosa*, 13.  
**Fissures of Santorini**, 14.  
**Fistula, congenital, of the ear**, 58.  
**Foamy secretion in the tympanum**, 159.  
**Follicular swellings of the naso-pharyngeal mucous membrane**, 171.  
**Foot-plate of the stirrup, relations of the, to the oval window**, 392.  
**Foramen stylo-mastoidaeum**, 14.  
**Forceps, angular**, 17.  
     in cases of impacted cerumen, 63.  
**Forceps, Politzer's**, 19.  
**Forehead-mirrors**, 9.  
**Foreign bodies in the auditory canal**, 95, 104.  
     in the middle ear, 309.  
     *imaginary*, in the auditory canal, 106.  
**Fossa conchæ**, 36.  
     *jugularis*, 14.  
**Fountain douche**, 24.  
     in the treatment of acute inflammation of the middle ear, 223.  
**Fowler's solution of arsenic, in the treatment of diffuse inflammation of the auditory canal**, 79.  
**Fractional method of recording the hearing**, 4.  
**Fracture of the hammer**, 346.  
**Fractures of the temporal bone**, 291.  
**Frost-bite of the auricle**, 44, 45, 49, 56.  
**Furuncles, complicating impacted cerumen**, 66.
- GALVANO-CAUTERY**, employment of, for destruction of polypoid growths, 269.  
**Ganglion spirale**, 404.  
**Gastro-intestinal irritation, in relation to chronic catarrhal inflammation of the middle ear**, 32.  
     in relation to inflammation of the external auditory canal, 32.  
**Giampetro-Læwenberg method**, 136.  
**Glands, cervical and post-auricular, participation of, in inflammation of the middle ear**, 217.  
**Glaserian fissure**, 13.  
**Glottis, spasm of, from applications of silver nitrate to pharynx**, 166.  
**Glycerine irritating to the skin of the external auditory canal**, 68.  
**Goodwillie**, 143.  
**Gottstein, J.**, 276.  
**Gout, as a cause of eczema of the ear**, 37.  
     as a cause of *naso-pharyngeal catarrh*, 198.  
     in relation to chronic catarrhal inflammation of the middle ear, 32.  
     in relation to inflammation of the external auditory canal, 32.  
**Granulation tissue, in the middle ear**, 256.  
**Gravity douche, in the treatment of acute inflammation of the middle ear**, 223.  
**Green, J. Orne**, 52, 53, 56, 110, 111, 116, 213, 306, 313, 320, 327, 328, 359.  
**Gruber, Joseph**, 8, 13, 53, 56, 103, 250, 375, 390.  
**Guddeu**, 41.
- Gummata of the auricle**, 53.  
**Gunshot wounds of the ear**, 236.
- HABERMANN**, 8.  
**Hackley, Charles E.**, 114.  
**Hæmatoma of the auricle**, 40.  
**Hæmorrhage, after excision of aural polypi**, 266.  
     *fatal*, from the ear, 360.  
     from *paracentesis of the membrana tympani*, 229.  
**Hæmorrhage from the ear, in acute inflammation of the tympanum**, 157.  
     in fractures of the temporal bone, 292.  
     in the middle ear, from use of Politzer's method, 128.  
**Hæmorrhagic exudation into the middle ear**, 163.  
**Hammer, absence of, in an otherwise normal drum membrane**, 344.  
     *deformed*, 344.  
     *exostosis of*, 195.  
     *fracture of*, 346.  
     *pockets in the vicinity of*, 33.  
     *relations of, to surrounding parts*, 14.  
**Hammer and anvil, relations of, to each other**, 300.  
**Hand-mirrors**, 9.  
**Hartmann, Arthur**, 27, 133, 140, 357, 401.  
**Haupt, G.**, 41.  
**Hearing, anomalies of**, 392.  
     Prout's fractional method of recording the, 4.  
**Hearing cells**, 406.  
**Hearing power, tests of the**, 3.  
**Heat, dry, in the treatment of acute inflammation of the middle ear**, 223.  
**Heat-prostration as a cause of acute inflammation of the middle ear**, 304.  
**Hebra's diachylon ointment**, 39.  
     *successful use of, in a case of diffuse inflammation of the external auditory canal*, 72.
- Helicotrema**, 401.  
**Hellz**, 36.  
**Helmholtz**, 391, 409.  
**Helmholtz's resonators**, 397.  
**Hensen's canalis reuniens**, 400.  
**Hermet**, 56.  
**Herpes zoster of the auricle**, 56.  
**Heurteloup artificial leech**, 225.  
**Hewett, Prescott**, 233.  
**Hickok, G. B.**, 44.  
**Highmore's antrum, disease of, a source of catarrhal inflammation of the middle ear**, 197.  
**Hinton's polypus forceps**, 263.  
**Hook-shaped manubrium mallei**, 344.  
**Hook, steel, for extraction of foreign body from the auditory canal**, 107.  
**Hooper, Franklin H.**, 175.  
**Horizontal portion of the mastoid cells (Toynbee)**, 302.  
**Horny growth of the membrana tympani**, 342.  
**Hot water, value of, in the treatment of acute inflammation of the middle ear**, 223.  
**House-fly, larvæ of, in the ear**, 259.  
**Howe, Lucien**, 48.  
**Hubrich**, 345.  
**Hun**, 40.  
**Hutchinson**, 364.

Hydrotympanum, 158.  
 Hyperæsthesia acustica, 385.  
 Hyperostosis of the mastoid process, 307.  
   of the middle ear, 346.  
 Hypertrophic catarrhal inflammation of  
 the middle ear, 194.  
 Hyrtl, 110, 301.

**I**CE, as a local application, in cases of  
 acute inflammation of the middle  
 ear, 226.  
 Imaginary foreign bodies in the auditory  
 canal, 106.  
 Incisions often useless in alleviating the  
 pain of furuncles in the external audi-  
 tory canal, 68.  
 Incisura intertragica, 36.  
 Induced current, employment of, in cases  
 of palato-tubal paresis, 149.  
 Inflating the middle ear, different meth-  
 ods of, 124.  
 Inflation of the middle ear, efficacy of,  
 182.  
 Injection of fluids into the Eustachian  
 tube objectionable, 180.  
 Intermittent complete deafness, 376.  
 Intra-nasal irritation as a cause of naso-  
 pharyngeal catarrh, 190.  
 Intra-tympanic vascular growths, 347.  
 Iodide of potassium in labyrinthine af-  
 fections, 386.  
 Iodine, tincture of, in treatment of naso-  
 pharyngeal cavity, 169.  
 Iodoform, powdered, as a parasiticide,  
 80.  
   in the treatment of discharge from  
 the middle ear, 238.  
 Iodol, in the treatment of discharge from  
 the middle ear, 238.

**JUGULAR FOSSA**, 14.

**KESSEL**, 116, 396.  
 Kipp, C. J., 44, 54, 273, 329, 365.  
 Klebs, 371.  
 Knapp, H., 66, 312, 323, 353, 365, 382.  
 Knife, proper pattern of, for incising fu-  
 runcles in the external auditory canal,  
 68.

**L**ABYRINTH, diseases of the, 371.  
 exfoliation of, by necrosis, 276.  
 membranous, 401.  
 primary acute inflammation of  
 the, 23, 377.  
 Labyrinthine fluid, effect of vibrations  
 of the stirrup upon, 395.  
 Laigt, Charles, 109, 351.  
 Lanina reticularis, 406.  
   spiralis membranacea, 406.  
   spiralis ossæa, 394.  
 Laminated masses of epithelium in the  
 middle ear, 277.  
 Langenbeck, 110.  
 Larvæ of the house-fly in the middle  
 ear, 259.  
 Lead-filled steel mallet, for mastoid  
 operations, 398.  
 Leeches, in the treatment of acute ecz-  
 ma of the ear, 38.  
   in the treatment of acute inflam-  
 mation of the middle ear, 224.  
 Life insurance, significance of a dis-  
 charge from the ear in, 248.  
 Ligamentum aoticum of the hammer,  
 391.

Ligamentum, spirale, 406.  
 Light, sources of, for examination of  
 the ear, 14.  
 Limited range of audition, 382.  
 Lindenbaum, 143.  
 Lips, power of reading the, 5.  
 Liquor potassæ, as a solvent of hard-  
 ened cerumen, 66.  
 Listerine as a nasal spray, 301.  
 Lithæmia, as a cause of eczema of the  
 ear, 37.  
   as a cause of naso-pharyngeal  
 catarrh, 198.  
   in relation to chronic catarrhal in-  
 flammation of the middle ear, 32.  
   in relation to inflammation of the  
 external auditory canal, 32.  
 Little, James, 118.  
 Lobule of the ear, 36.  
 Localized inflammations of the middle  
 ear, 33.  
 Lœwenberg, B., 127.  
 Lucæ, 8, 145, 276.  
 Lupus of the auricle, 53.

**M**ACULÆ acusticæ, 408.  
 Maggots, living, in the ear, 259.  
 Malignant tumor of the middle ear, 353.  
 Malleo-incudal joint, 391.  
 Mallet, for operations on the mastoid  
 process, 398.  
 Marcé, 280.  
 Markoe, T. M., 117, 317.  
 Martin, 54.  
 Massage, in the treatment of chronic otis  
 media catarrhalis, 202.  
 Mastoid antrum, chronic ulcerative in-  
 flammation of the, 322.  
   localized inflammation of, 28.  
   relations of, to surrounding parts,  
 30, 390.  
   the frequent seat of desquamative  
 processes, 278.  
   cells, condensing osteitis of the, 306  
   congestion (case), 214.  
   emissary veins, phlebitis of, 326.  
   inflammations, value of Wilde's in-  
 cision in, 309.  
 integuments, often quickly affect-  
 ed in acute inflammation of the  
 middle ear, in infants, 30.  
 operation, steps of the, 335.  
 osteitis, acute diffuse, 313.  
 subacute condensing, 307, 325.  
 periostitis, 307.  
 process, anatomy of, 298.  
 perforation of the, 330.  
 Matthewson, Arthur, 116.  
 McFarland, Wm., 357.  
 Medicinal springs, in the treatment of  
 chronic otitis media catarrhalis, 202.  
 Membrana basilaris, 406.  
   flaccida, 215.  
   tectoria, 407.  
 tympani, abnormally drawn in-  
 ward, 140, 141.  
 atrophy of, 141, 142, 341.  
 cyst-like tumors of the, 240.  
 deformed, 344.  
 distention of, from the presence  
 of an excess of air in the mid-  
 dle ear, 153.  
 horny growth of the, 342.  
 incision of the, in cases of acute  
 inflammation of the middle  
 ear, 227.

- Membrana tympani**, indications for paracentesis of, 222.  
in hydrotympanum, 158.  
normal appearances of, 139.  
paracentesis of, in hydrotympanum, 185, 186.  
perforations in the, 267.  
physiology of the, 239.  
relations of, to the annulus tympanicus, 13.  
relations of, to the middle ear and external auditory canal, 14.  
reproductive powers of the, 264.  
retraction of, 159.  
thickening of the, 262.  
tubercular ulceration of the, 267.  
vascular growth of the, 243.  
tympani secundaria, 260, 263.
- Membranous labyrinth**, 401.
- Ménière's disease**, 277.
- Meningitis, basilar**, extension of, to the labyrinth, 23.  
localized, present in every severe case of inflammation of the middle ear, 208.
- Meyer, Ludwig**, 41.
- Meyer, of Copenhagen**, 171.
- Micro-organisms**, part played by, in inflammations of the middle ear, 34.
- Middle ear**, acute and subacute catarrhal inflammation of, 152.  
acute purulent inflammation of the, 214.  
cheesy inflammation of the, 268.  
chronic catarrhal inflammation of the, 32, 194.  
chronic purulent inflammation of the, 242.  
desquamating processes in the, 276.  
diseases of, 139.  
foreign bodies in the, 269.  
hemorrhage in, from use of Politzer's method, 128.  
introduction of remedies into, 231.  
localized inflammations of the, 33.  
malignant tumors of the, 253, 257.  
methods of examining the, 123.  
new-growths in the, 246.  
syphilis of the, 260.
- Middle ear, and external auditory canal**, relations of to each other, 14.
- Middle ear, inflammation, extension of, to surrounding parts**, 20.
- Middle ear, pipette**, 222.
- Middle ear, syringe**, Blake's, 226.
- Mirrors for reflecting light into the ear**, 8.
- Modified Wilde's incision**, 263.
- Modiolus**, 404.
- Moos**, 273, 297, 347, 371.
- Morse**, 405.
- Mouth-gag**, Hooper's, 179.
- Mucous exudations in the middle ear**, 158.
- polypus of the ear**, 263.
- Multiple perforations**, 269.
- Mumps**, complete unilateral loss of hearing from, 272.
- Murmurs, subjective and objective**, systolic, 257.
- Muscles attached to the ossicles**, 395.
- Mussey**, 54.
- Myringotomy**, 167.
- Myxo-fibroma of the auricle**, 51.
- NASAL DOUCHE**, use of, a frequent cause of inflammation of the middle ear, 150, 204.
- Nasal passages and pharynx, relations of, to the Eustachian tube**, 133.
- Nasal passages, obstruction of**, 154.  
in connection with naso-pharyngeal catarrh, 197.
- Nasal specula**, Zaufal's, 138.
- Naso-pharyngeal catarrh**, 140.  
cavity, adenoid vegetations in, 171.
- Naso-pharynx**, applications of silver nitrate to, 105.  
exploration of, with the forefinger, 138.
- Necrosis of the temporal bone**, 275.
- Neumann**, 53.
- Neuralgia of the ear**, 53.
- New-growths in the auditory canal**, 112.  
in the middle ear, 246.
- Nitrate of silver solutions in the treatment of diffuse inflammation of the auditory canal**, 78.
- Nitric acid**, application of, to stumps of polypi, 267.
- Noyes, Henry D.**, 133, 260, 261.
- Nozzle for ear douche**, proper shape of, 24.
- Nuhn**, 300, 302.
- OCEAN-BATHING** a frequent cause of acute inflammation of the middle ear, 150.
- Oil of Cade**, in the treatment of eczema of the ear, 28.
- Ossicles of hearing**, 390.  
destruction and expulsion of the, 283.  
excision of the, 228.  
relations of, diagrammatically represented, 30.
- Osteoma of the auditory canal**, 112.
- Osteophytes in the middle ear of the elephant**, 394.
- Otalgia**, 358.  
intermittens, 359.
- Othæmatoma**, 40.  
spurious, of the auricle, 44.
- Otitis externa circumscripta**, 66.  
diffusa, 69.
- Otitis media catarrhalis acuta**, 152, 155.  
chronica, 194.  
media mucosa; cases, 180, 190, 191, 192.  
serosa sive mucosa, 158.
- Otoliths**, 404.
- PACKARD, CHARLES**, 261.  
Painless ulceration of the drum membrane, 267.  
Palate-hook of hard rubber, 178.  
Palato-tubal muscles, paralysis of, 147.  
Paquelin's thermo-cautery, in the treatment of vascular growths of the auricle, 54.
- Paracentesis of the membrana tympani**, 185, 186.  
in acute inflammation of the middle ear, 213, 223, 227.
- Pareidt**, 41, 46.
- Pathology, general, of ear diseases**, 26.
- Paulus Aegheta**, 110.
- Pear-shaped bodies in the middle ear**, 268.
- Peck, S. H.**, 256.
- Penicillium glaucum in the external auditory canal**, 68.
- Perforation of the mastoid process**, 250.
- Perforations in the drum membrane**, 206, 210, 227.

- Perforations, multiple, 269.  
 Perichondritis of the auricle, 40.  
 Periostitis of the mastoid process, 307.  
 Phlebitis of the mastoid emissary veins, 326.  
 Physical exercise, value of, in the treatment of chronic naso-pharyngeal catarrh, 201.  
 Pipette, for introducing remedial solutions into the middle ear, 232.  
 Pneumatic spaces of the mastoid process, 301.  
 Pockets of the middle ear, 83.  
 Polltzer, Adam, of Vienna, 4, 8, 14, 18, 33, 54, 55, 114, 127, 136, 139, 149, 158, 230, 283, 286, 346, 390, 393, 398, 403.  
 Polltzer's method of inflating the middle ear, 125.  
 Pollak, 41.  
 Polypoid growths of the external auditory canal, 87.  
     of the middle ear, 57.  
 Polypus snare, Blake's, 263, 266.  
 Pomeroy, Oren D., 46, 61, 138, 276.  
 Porte-acid, 267.  
 Porter, W. H., 355.  
 Position, value of, in the treatment of acute inflammation of the middle ear, 227.  
 Posterior auricular artery, false aneurism of, 329.  
 Posterior fold of the drum membrane, acute inflammation of the, 230.  
 Posterior nasal syringe, dangers of, 151.  
 Post-nasal forceps, 176, 178.  
 Potassa, caustic, as a solvent of hardened cerumen, 65.  
 Poultices, hot, in the treatment of acute inflammation of the middle ear, 224.  
     in the treatment of furuncles of the external auditory canal, 68.  
 Powdered remedies, in the treatment of discharge from the middle ear, 238.  
 Pregnancy occasionally associated with labyrinthine disease, 375.  
 Pressure, prolonged, effects of, upon the different structures of the middle ear, 34.  
 Pritchard, Urban, 404.  
 Probes, slender, for aural purposes, 20.  
 Proliferative variety of inflammation of the middle ear, 255.  
 Prout, J. S., of Brooklyn, 4.  
 Purulent inflammation of the middle ear, acute, 204.  
     chronic, 242.  
 Pyemic complications, in mastoid disease, 227.
- Q**UININE, effects of, upon the middle ear, 151.
- R**ALES heard, in cases of otitis media serosa or mucosa, 163.  
 Randall, B. Alexander, 283, 284, 288, 289, 303, 343, 345, 405.  
 Rankin, 121.  
 Reading the lips, 5.  
 Reflectors, 8, 13.  
 Reflex otalgia, 359.  
 Reincke, Carl, 396.  
 Reissner's membrane, 408.  
 Resonators, Helmholtz's, 397.  
 Rest, in the treatment of acute inflammation of the middle ear, 226, 329.
- Retzius, 401.  
 Reynder's ear douche, 24.  
 Richards, Huntington, 225, 270.  
 Rinne's experiment, 7.  
 Rochelle salts, in the treatment of chronic otitis media catarrhalis, 201.  
     in the treatment of furunculosis, 69.  
 Roosa, D. B. St. John, 47, 52, 53, 111, 120, 151, 360, 361, 396.  
 Rosenmüller's fossa, 133, 135.  
 Rubinat-Condal water, in furunculosis, 69.  
 Rüdinger, 400.  
 Ruptures of the drum membrane, 345.
- S**ACCULE, 400.  
 Salt water as a cause of inflammation of the external auditory canal, 69.  
 Sands, H. B., 354.  
 Santorinian fissures, 14.  
 Sarcoma of the auditory canal, 118.  
     of the middle ear, 353, 357.  
 Sarcomatous polypus of the ear, 262.  
 Scala cochleæ, 400.  
     tympani, 401.  
     vestibuli, 401.  
 Scalp, abscesses of, in connection with mastoid disease, 326.  
 Scarificator (Bacon's pattern), for use in local blood-letting, 225.  
 Schalle, 346.  
 Schwabach, 55.  
 Schwartz, H., 49, 54, 103, 110, 143, 145, 271, 276, 327, 330, 347, 377.  
 Sclerosis of the mastoid cells, 206.  
     of the tympanic mucous membrane, 195.  
 Scraping the bone, for the cure of caries, 272.  
 Sea-turtle, ear of, 315, 397.  
 Sebaceous cysts of the auditory canal, 121.  
 Self-inflation, 193.  
 Semicircular canals, 399, 401.  
     Roettcher's experiments upon, 373.  
 Septicæmic manifestations in connection with mastoid disease, 327.  
 Serous exudations in the middle ear, 158.  
 Sexton, S., 42, 357.  
 Shaw, 346.  
 Shrapnell's membrane, 215.  
     a favorite location for the development of a sinus, 35.  
     perforations in, 272.  
     ulcerated opening in, 240.  
 Siegle's pneumatic speculum, 124, 189.  
 Silver nitrate, application of, to the stumps of polypi, 268.  
     in solid form, application of, to the mucous membrane of the middle ear, 255.  
     in the treatment of eczema of the ear, 38.  
     strong solutions of, in the treatment of diffuse inflammation of the external auditory canal, 73, 74.  
     solutions, introduction of, into the middle ear, 236.  
     mode of applying to vault of pharynx, 165.  
 Simrock, 348.  
 Snuuses, formation of, in the vicinity of the drum membrane, 35.  
 Smith, A. A., 119.

- Smoking, injurious effects of, upon a ca-  
tarrhally inflamed nasal mucous  
membrane, 196.  
promotes irritation of the naso-  
pharyngeal mucous membrane,  
180.
- Snapping noises in the ear, 145.
- Snare, Blake's, for removing polypi  
from the ear, 263, 266.
- Snuffing of salt water, a cause of acute  
inflammation of the middle ear, 310.
- Soda, bicarbonate of, as a solvent of  
hardened cerumen, 65.
- Spasmodic contractions of the muscles  
of the Eustachian tube, 145.
- Specula, Zaufal's nasal, 138.
- Speculum, Siegle's pneumatic, 134.
- Spencer, H. N., 276, 285, 358.
- Spina tympanica posterior, 391.
- Spoken words, as a test of the hearing, 3.
- Sprays in the treatment of the Eusta-  
chian tube and middle ear, 180.
- Staggering gait, 378.
- Stapedio-vestibular joint, calcareous de-  
posits near, 282.
- Stapedius muscle, 397.
- Steaming the middle ear, 181.
- Stirrup, 392, 394.  
expulsion of, not necessarily fatal  
to the hearing, 288.  
relations of, to surrounding parts,  
14.
- Stoehr, 103.
- Strabismus, in mastoid disease, 327.
- Strawbridge, 53.
- Stylo-mastoid foramen, 13.
- Sulphate of copper, application of, to  
stumps of excised polypi, 263.
- Sympathetic otalgia, 358.
- Syphilis, inherited, 365.  
of the labyrinth, 360.
- Syphilitic gummata and ulcerations of  
the auricle, 53.  
ulcers and condylomata of the ex-  
ternal auditory canal, 100.
- Syringe, for aural purposes, 21, 22.
- Syringing, in cases of impacted ceru-  
men, 63.
- Systolic murmurs, subjective and ob-  
jective, 357.
- T**EETH, disease of, a source of otal-  
gia, 339.  
syphilitic, Hutchinson's, 364.
- Tegmen tympani, 14.  
defective, effects of, in acute in-  
flammation of the middle ear, 30.
- Temperature of body, in mastoid affec-  
tions, 327.  
rise of, in acute inflammations of  
the middle ear, 219.
- Temporal bone, fractures of the, 291.  
necrosis of the, 275.  
of newly-born child, 13.
- Temporo-maxillary joint, arthritis of, 29.
- Tensor tympani muscle, 396.  
spasmodic contractions of, 140.
- Terillon, 257.
- Tests of the hearing power, 3.
- Thermometer, in acute otitis media, 158.
- Thickening of the drum membrane, 282.
- Ticking of a watch, as a test of the hear-  
ing, 3.
- Tincture of iodine in the treatment of  
the naso-pharyngeal cavity, 169.
- Tobacco smoke, irritating effects of, up-  
on the naso-pharyngeal mucous mem-  
brane, 196.
- Toynbee, 276, 302, 374.
- Toynbee's artificial drum membrane, 290.
- Tragus, 36.
- Triquet, 55.
- Tuberculosis of the ear, 366, 368.
- Tuning fork, 6.  
in labyrinthine disease, 365.
- Turnbull, 346.
- Tympanic cysta, 290.
- Tympanum, hyperostosis of the, 346.
- U**Lcers of the auditory canal, 67.  
syphilitic, of the auditory canal,  
100.
- Umbo of the membrana tympani, 390.
- Urbantschitch, 75, 283, 326, 359.
- Uterine disease, as a cause of tinnitus  
aurium, 199.  
in relation to chronic catarrhal in-  
flammation of the middle ear, 32.
- Utricle, 400.
- V**ALSALVA'S experiment, 123, 124.  
Van Gieson, Ira, 263, 265.
- Vapors, introduction of, into the middle  
ear, 181.
- Vascular growth of the membrana tym-  
pani, 343.  
growths, intratympanic, 346.
- Vaseline and vaseline oil, in the treat-  
ment of eczema of the auricle, 83.
- Vault of pharynx, exploration of, with  
the forefinger, 133.
- Vestibule, 400.
- Vichy water, in the treatment of chronic  
otitis media catarrhalis, 302.
- Virchow, R., 41, 352.
- Vogel, 375.
- Volkmann's spoon, in mastoid opera-  
tions, 338.
- Voltolini, 359, 377.
- Von Bismadecki, 117.
- Von Truetsch, 110, 375.
- W**ATCH, usefulness of, in testing  
the hearing, 3.  
Water, proper temperature of, for use  
in syringing the ear, 23.
- Watery discharge from the ear, in cases  
of fracture at the base of the skull, 293.
- Weber-Liel, 359, 372.
- Weber's nasal douche, use of, objection-  
able, 167.
- Weir, Robert F., 12, 130, 346, 347, 352.
- Weinlechner, 54.
- Weich, Wm. H., 119.
- Wendt, 44, 47.
- Wilde, Sir William, of Dublin, 8, 68, 329.
- Wilde's ear specula, 8.  
incision, in mastoid inflammations,  
309, 329, 331.  
incision, modified, 303.  
snare, 263.
- Wokes, Edward, 147, 196, 198.
- Wolff, A., 366.
- Wood, James R., 312, 317.
- Wounds of the auditory canal, 111.
- Z**AUFAL, 347.  
Zaufal's nasal specula, 138.  
Zona arcuata, 406.  
perforata, 406.
- Zuckerkaudl, 301.











2121  
B921  
1889

118271

**LANE**



Gift  
San Francisco County Medical  
Society



L121  
3921  
1889

118271

**LANE**

**MEDICAL**



**LIBRARY**

Gift  
San Francisco County Medical  
Society

